








# Transient second-degree high-grade atrioventricular block caused by myocarditis

Bilal Özelce<sup>1</sup> , Utku Pamuk<sup>1</sup> , Serhat Koca<sup>2</sup> , Hazım Alper Gürsu<sup>2</sup>  and İbrahim İlker Çetin<sup>3</sup> 

## Brief Report

**Cite this article:** Özelce B, Pamuk U, Koca S, Gürsu HA, and Çetin İİ (2024) Transient second-degree high-grade atrioventricular block caused by myocarditis. *Cardiology in the Young* 34: 218–220. doi: [10.1017/S1047951123003980](https://doi.org/10.1017/S1047951123003980)

Received: 10 May 2023

Accepted: 5 November 2023

First published online: 1 December 2023

### Keywords:

Myocarditis; atrioventricular block; treatment

### Corresponding author:

B. Özelce; Email: [ozelcebilal@gmail.com](mailto:ozelcebilal@gmail.com)

<sup>1</sup>Department of Pediatric Cardiology, Ankara City Hospital, Ankara, Turkey; <sup>2</sup>Department of Pediatric Cardiology, University of Health Sciences, Ankara City Hospital, Ankara, Turkey and <sup>3</sup>Department of Pediatric Cardiology, Yıldırım Beyazıt University, Ankara City Hospital, Ankara, Turkey

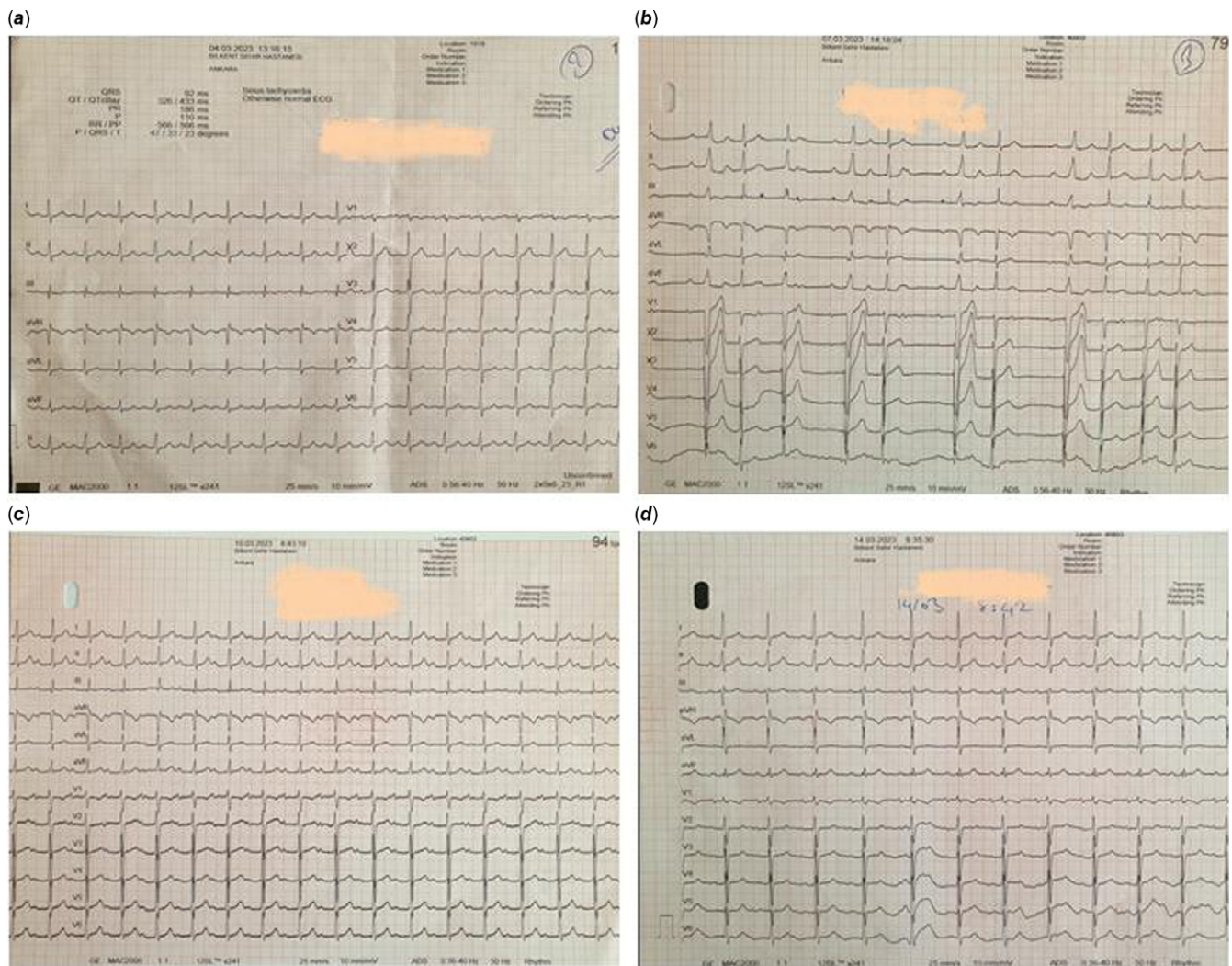
### Abstract

Myocarditis is an inflammatory disease of the heart muscle that most commonly occurs after infectious diseases in childhood. The clinical picture of acute myocarditis ranges from asymptomatic infection to fulminant heart failure and sudden death (1). Most of the patients may present with nonspecific symptoms such as respiratory distress, chest pain, nausea, and vomiting (2). While rhythm abnormalities such as ventricular and supraventricular rhythm disorders can be observed in these patients, various degrees of atrioventricular blocks may rarely develop (3). In this article, we aimed to present a patient who developed second-degree, high-grade atrioventricular block after myocarditis and recovered completely after treatment.

Myocarditis is an inflammatory disease of the heart muscle that most commonly occurs after infectious diseases in childhood. The clinic picture of acute myocarditis ranges from asymptomatic infection to fulminant heart failure and sudden death.<sup>1</sup> Most of the patients may present with nonspecific symptoms such as respiratory distress, chest pain, nausea, and vomiting.<sup>2</sup> While rhythm abnormalities such as ventricular and supraventricular rhythm disorders can be observed in these patients, various degrees of atrioventricular blocks may rarely develop.<sup>3</sup> In this article, we aimed to present a patient who developed second-degree, high-grade atrioventricular block after myocarditis and recovered completely after treatment.

### Case report

A 13-year-old, 97 kg, male patient applied to the emergency outpatient clinic with the complaints of intermittent left chest pain and weakness started three days ago. He had a history of upper respiratory tract infection a month ago. Vital signs and physical examination of the patient were normal. PR time was 160 ms, QTc time was 410 ms, and there were no ST segment and T-wave changes in electrocardiogram at the admission (Fig. 1a). In echocardiographic examination, cardiac functions were normal, and he had a secundum type atrial septal defect. C-reactive protein was 160 mg/L (normal range 0–5), troponin I; 100 ng/L (normal range 0–45), N-terminal pro-B-type natriuretic peptide; 778 ng/L (normal range < 125) in laboratory examinations. Three days later, the patient had intermittent short-term chest pain and did not have syncope or palpitations. Second-degree, high-grade atrioventricular block, ventricular escape beat patterns secondary to atrioventricular conduction delay were detected in the control electrocardiogram (Fig. 1b). Echocardiographic examination revealed left ventricular ejection fraction: 51% and fractional shortening: 26%. Troponin I was 93 ng/L, N-terminal pro-B-type natriuretic peptide: 556 ng/L, C-reactive protein: 130 mg/L, and erythrocyte sedimentation rate: 20 mm/h. Considering that the patient had inflammation at the atrioventricular node that developed as a result of myocarditis, intravenous immune globulin treatment at a dose of 400 mg/kg for 5 days was started. Oral clarithromycin was added to treatment after investigations for the aetiology. Lyme disease agent *Borrelia burgdorferi* was negative, and mycoplasma pneumonia immune globulin M was positive. Because the electrocardiogram findings did not improve on the second day of the treatment, we started oral methylprednisolone therapy at a dose of 3x 20 mg to suppress the inflammation. On the third day after treatment, second-degree, high-grade atrioventricular block regressed and turned to first-degree atrioventricular block (PR time 400 ms) and ventricular escape beats disappeared (Fig. 1c). On the seventh day of the follow-up, the ventricular functions of the patient improved in the echocardiography, and the PR interval decreased to 160 ms in electrocardiogram (Fig. 1d). The acute phase reactants were also regressed. The patient was discharged on the seventh day of his hospitalisation.



**Figure 1.** *a*-First admission ECG. Normal sinus rhythm. *b*-3rd day ECG; AV block, 2nd degree, high grade. *c*-5th day (3rd day after treatment) ECG; 1st degree AV block. *d*-7th day ECG; normal sinus rhythm.

## Discussion

Myocarditis is an inflammatory disease of the heart muscle, and its true incidence is unknown because the disease course is asymptomatic in most patients.<sup>4</sup> Viral agents such as Coxsackie B, adenovirus, and parvovirus are at the forefront, but bacterial agents such as mycoplasma and chlamydia are also involved.<sup>5</sup> Electrocardiogram abnormalities are seen in the vast majority of patients.<sup>6</sup> Although ST segment and T-wave changes are common electrocardiogram findings in myocarditis, varying degrees of atrioventricular block are rarely seen.<sup>7</sup> Mycoplasma pneumonia and influenza A agents have been reported among the factors causing atrioventricular block in varying degrees due to myocarditis.<sup>8</sup> Second-degree atrioventricular block arrhythmia detected in our case is one of the rare types of arrhythmias in myocarditis. High-degree atrioventricular block is the absence of conduction of two or more P waves into the ventricles with PR prolongation. Since it is an arrhythmia with a high risk of progression to third-degree atrioventricular block, it can turn into a life-threatening medical emergency, especially in patients with myocarditis with impaired ventricular functions. These patients should be followed closely in terms of haemodynamics and electrocardiogram monitoring. In our patient, considering conduction delay due to atrioventricular node

inflammation, oral methylprednisolone and intravenous immune globulin treatment were given to suppress the inflammation. It has been reported that, since these patients can show sudden haemodynamic deterioration and can die before allowing pacemaker implantation, temporary pacemaker implantation is performed in order to be used when the anti-inflammatory therapy is not sufficient.<sup>6</sup> In our patient, there was no need to a pacemaker implantation due to improvement in arrhythmia and left ventricular functions after anti-inflammatory therapy.

## Conclusions

Atrioventricular block may develop rarely after myocarditis. These patients can be successfully treated, especially with the suppression of inflammation. However, in cases where anti-inflammatory therapy is not sufficient, a pacemaker should be reserved.

## References

1. Caforio AL, Pankuweit S, Arbustini E, et al. Current state of knowledge on aetiology, diagnosis, management, and therapy of myocarditis: a position statement of the European society of cardiology working group on myocardial and pericardial diseases. *Eur Heart J* 2013; 34: 2636–2648.

2. Canter CE, Simpson KE, Simpson KP. Diagnosis and treatment of myocarditis in children in the current era. *Circulation* 2014; 129: 115–128.
3. Granér M, Lommi J, Kupari M, Räisänen-Sokolowski A, Toivonen L. Multiple forms of sustained monomorphic ventricular tachycardia as common presentation in giant-cellmyocarditis. *Heart* 2007; 93: 119–121.
4. Feldman AM, Mc Namara D. Myocarditis. *N Engl J Med* 2000; 343: 1388–1398.
5. Chang AB, O'Duffy J, Ratcliffe J, Radford D, Masters IB. Severe pleuropneumonia without a cough and myocarditis with mixed mycoplasma infection. *J Paediatr Child Health* 1996; 32: 546–547.
6. Caughey RW, Humphrey JM, Thomas PE. High-degree atrioventricular block in a child with acute myocarditis. *Ochsner J* 2014 Summer; 14: 244–247.
7. Buttà C, Zappia L, Lattera G, Roberto M. Diagnostic and prognostic role of electrocardiogram in acute myocarditis: a comprehensive review. *Ann Non invasive Electrocardiol* 2020; 25: e12726.
8. Cheng WL, Lin CS. Transient atrioventricular block as a complication of influenza a virus: a case report. *J Acute Med* 2021; 11: 102–104.