


Letter to the Editor: New Observation

C2 Ganglionectomy for Pain Associated with Multiple Occipital Neurofibromas

Fady Girgis¹ , Elizabeth Adam¹ , Suganth Suppiah², Daniel Umansky^{1,3} and Rajiv Midha¹

¹Department of Neurosurgery, University of Calgary, Calgary, AB, Canada, ²Department of Neurosurgery, University of Toronto, Toronto, ON, Canada and

³Department of Neurosurgery, University of Utah Health, Salt Lake City, UT, USA

Here, we present the case of a patient with neurofibromatosis type 1 (NF-1) who responded to bilateral C2 ganglionectomies for treatment of pain associated with multiple neurofibromas along the greater occipital nerves. To our knowledge, this is the first reported case of ganglionectomy or proximal neurotomy for the management of neuropathic pain in peripheral nerve tumors. While the ganglion itself was infiltrated with tumor, the neurofibromas along the distal nerve were not removed.

A 51-year-old female with NF-1 presented with several occipital subcutaneous nodules and associated pain. The patient had previously undergone multiple neurofibroma resections involving various peripheral nerves over the previous decades. She was otherwise healthy, and medications included gabapentin 2400 mg per day, a fentanyl patch and oxycodone as needed. She had previously tried amitriptyline with minimal effect. Pain was described as shooting and stabbing extending from the occipital area toward the top of the head, triggered by pressure to the occipital region during sleep. On examination, several small nodules could be palpated subcutaneously along the course of the greater occipital nerves bilaterally, many with a positive Tinel sign radiating ipsilaterally along the course of each nerve. Magnetic resonance imaging of the cervical spine showed multiple neurofibromas arising from the C2 nerve roots bilaterally, unchanged on serial imaging done over 5 years.

Surgical resection of four of the larger lesions was performed with neurolysis of the left greater occipital nerve. The pathology of the resected tissue came back as neurofibroma, WHO grade 1. The operation was completed without complication, and the patient initially had some relief of her pain without any associated numbness. Unfortunately, at 4-month follow-up, her pain had largely returned to pre-surgical baseline, and she still had several palpable subcutaneous lesions in the area. Because the majority of the lesions were located along the courses of the greater occipital nerves, and they were too numerous to re-attempt removal of the individual lesions, the patient was offered C2 ganglionectomies. The patient was made aware of the risks of developing deafferentation pain, failure of the procedure and/or early recurrence of pain. She was also offered occipital nerve stimulation as an alternative. She elected to proceed with ganglionectomy, and because this was an experimental procedure we only offered a

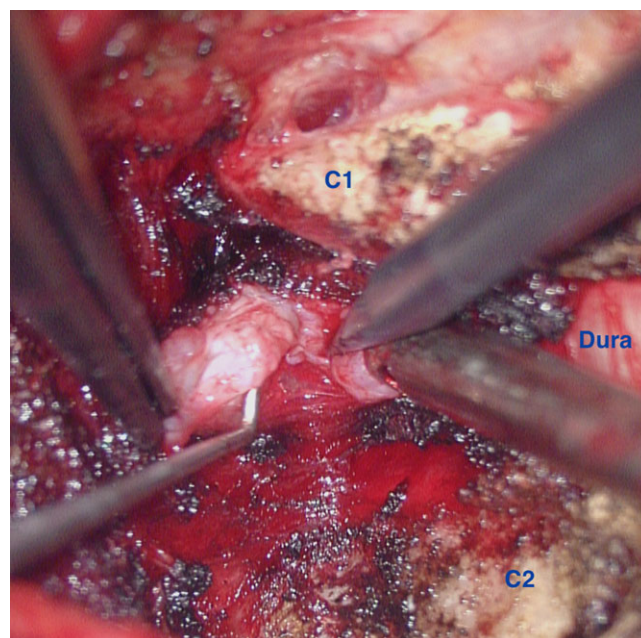


Figure 1. Intra-operative magnified image showing the tumor infiltrated left C2 ganglion during transection. C1 arch is above, C2 arch is below and dura of the thecal sac is seen medially on the right side of the image. Burned remnants of venous plexus can be seen surrounding the ganglion.

unilateral approach and started with the left side where the pain was most severe.

Standard posterior cervical dissection was carried out identifying the posterior arches of C1 and C2 on the left side. The ganglion was found by dissecting lateral to the thecal sac and coagulating any surrounding venous plexus. It was found to be abnormally bulbous due to tumor infiltration. An external neurolysis was performed, and all fascicles proximal and distal to the ganglion were then transected under microscope (Figure 1). The ganglion was removed, and there was no presence of cerebrospinal fluid. Pathology revealed neurofibroma, WHO grade 1. The procedure was uncomplicated, and the patient was discharged home the next

Corresponding author: Fady Girgis; Email: fmgirgis@ucalgary.ca

Cite this article: Girgis F, Adam E, Suppiah S, Umansky D, and Midha R. (2025) C2 Ganglionectomy for Pain Associated with Multiple Occipital Neurofibromas. *The Canadian Journal of Neurological Sciences* 52: 531–532, <https://doi.org/10.1017/cjn.2024.282>

© The Author(s), 2024. Published by Cambridge University Press on behalf of Canadian Neurological Sciences Federation. This is an Open Access article, distributed under the terms of the Creative Commons Attribution licence (<http://creativecommons.org/licenses/by/4.0/>), which permits unrestricted re-use, distribution and reproduction, provided the original article is properly cited.

day with some numbness and no further pain the left occipital region.

At 1-year follow-up, the patient remained pain free in this region and was extremely pleased with the result. Although the subcutaneous nodules were still present at the original size, they were no longer associated with pain to palpation and Tinel sign was negative. Due to the successful outcome on the left side, we then performed the same procedure on the right side with identical results at further 1-year follow-up. Small areas of numbness persisted bilaterally along the course of the nerves.

C2 ganglionectomy is typically performed in cases of occipital neuralgia, defined as paroxysmal shooting or stabbing pain in the distribution of the greater, lesser or third occipital nerves.¹ The disorder has various causes, such as trauma or compression, and those patients with typical neuropathic pain descriptors, or those with post-traumatic neuropathy, respond best to surgical treatment with success rates of 60%–80%.² Ganglionectomy is postulated to relieve pain by targeting its source in the dorsal root ganglion and preventing its recurrence by prohibiting axonal regeneration through removal of the cell bodies. This, in theory, makes it superior to more distal neurotomy and less invasive techniques such as endoscopic or percutaneous C2 rhizotomy or C2/3 facet rhizolysis.³ While our patient did not have a typical case of occipital neuralgia, her pain responded nonetheless as it was neuropathic in nature.

Our case is consistent with the literature in that benign peripheral nerve tumors tend to present with pain that is not always alleviated with tumor resection. Schwannoma resection tends to be more successful in improving pain as compared to neurofibromas.⁴ For example, a series of 28 neurofibroma resections only resulted in pain relief in 20% of cases, whereas 73 schwannoma resections resulted in pain relief in 40% of cases.⁵ Different outcomes may be related to different rates of gross total resection, which are consistently lower with neurofibromas due to their more infiltrative nature, especially in NF-1.^{4,5} As in our case, initial resective surgery was unsuccessful in relieving pain, which lead to exploration of alternative surgical modalities.

Two reported cases describe tumor resection with surrounding neurectomy for the treatment of pain in humans and animals. One case of recurrent schwannomatosis of the radial digital nerve in a human⁶ and another case of a neurofibroma of the ulnar nerve in a dog both treated with segmental neurectomy and both resulted in no further signs of pain or tumor recurrence at 1-year follow up.⁷

In our case, the nerve with its associated tumors was not removed, but rather it was transected at the ganglion. While physical palpation of the subcutaneous tumors over the span of 2 years did not reveal any growth or regression of the lesions, the evolution of peripheral nerve sheath tumors in nerves undergoing Wallerian degeneration is unknown, and therefore it is unclear if our patient's greater occipital nerve tumors will grow after denervation, even though pain is no longer a factor. But given the positive outcome in this case, ganglionectomy or proximal neurotomy may be a general option for painful, non-compressive tumors affecting peripheral nerves where sacrifice would not cause functional impairment.

Author contributions. RM and FG are the neurosurgeons involved in this patient's case. EA collected the data, and FG and EA drafted the manuscript. All authors (EA, SS, DU, RM and FG) were involved in interpretation of the data. SS, RM and FG reviewed the article. All authors read and approved the final manuscript.

Funding statement. None.

Competing interests. None.

References

- Olesen J, Bes A, Kunkel R, Lance JW, Nappi G, Pfaffenrath V, Rose FC, Schoenberg BS, Soyka D, Tfelt-Hansen P, Welch MA, Wilkinson M. Headache classification committee of the international headache society (IHS) the international classification of headache disorders, 3rd edition. *Cephalalgia*. 2018;38:1–211. DOI: [10.1177/0333102417738202](https://doi.org/10.1177/0333102417738202).
- Acar F, Miller J, Golshani K, Israel Z, McCartney S, Burchiel K. Pain relief after cervical ganglionectomy (C₂ and C₃) for the treatment of medically intractable occipital neuralgia. *Stereot Funct Neuros*. 2008;86:106–12. DOI: [10.1159/000113872](https://doi.org/10.1159/000113872).
- Lozano A, Vanderlinden G, Bach R, Rothbart P. Microsurgical C-2 ganglionectomy for chronic intractable occipital pain. *J Neurosurg*. 1998;89:359–65. DOI: [10.3171/jns.1998.89.3.0359](https://doi.org/10.3171/jns.1998.89.3.0359).
- Kim D, Murovic J, Tiel R, Moes G, Kline D. A series of 397 peripheral neural sheath tumors: 30-year experience at louisiana state university health sciences center. *J Neurosurg*. 2005;102:246–55. DOI: [10.3171/jns.2005.102.2.0246](https://doi.org/10.3171/jns.2005.102.2.0246).
- Artico M, Cervoni L, Wierzbiński V, D'Andrea V, Nucci F. Benign neural sheath tumours of major nerves: characteristics in 119 surgical cases. *Acta Neurochir*. 1997;139:1108–16. DOI: [10.1007/BF01410969](https://doi.org/10.1007/BF01410969).
- Nicolescu R, Agrawal N, Pettit R, Netscher D. Recurrent schwannomatosis of the hand. *HAND*. 2020;15:NP73–NP79. DOI: [10.1177/1558944719895605](https://doi.org/10.1177/1558944719895605).
- Basa R, Crowley A, Johnson K. Neurofibroma of the ulnar nerve in the carpal canal in a dog: treatment by marginal neurectomy. *J Small Anim Pract*. 2020;61:512–15. DOI: [10.1111/jsap.12945](https://doi.org/10.1111/jsap.12945).