




## Letter to the Editor: New Observation

# Subcutaneous Intrathecal Catheter and Port for Repetitive Nusinersen Administration

Abdulaziz A. Bokeris<sup>1</sup> , Carlos Emilio Restrepo<sup>2</sup> , Jordan Sheriko<sup>3</sup>  and P. Daniel McNeely<sup>4</sup>

<sup>1</sup>Neurosurgery, Dalhousie University, Halifax, NS, Canada, <sup>2</sup>Neurosurgery, Dalhousie University, Halifax, NS, Canada, <sup>3</sup>Pediatrics, Dalhousie University, Halifax, NS, Canada and <sup>4</sup>Division of Neurosurgery, IWK Health Centre, 5850 University Avenue, P.O. Box 9700, Halifax, NS, Canada

**Keywords:** Spinal muscular atrophy; SMA; Nusinersen; Spinraza; Intrathecal administration; Subcutaneous intrathecal nusinersen

Spinal muscular atrophy (SMA) is a genetic disorder that causes degeneration of anterior horn cells, leading to muscle weakness and atrophy. In 2017, Health Canada approved intrathecal nusinersen to prevent the degeneration of motor neurons in the spinal cord. Repetitive intrathecal injections of nusinersen may be challenging in patients with spinal deformities, particularly if the patient has undergone scoliosis surgery or if the patient requires an anesthetic with every injection.

Inspired by others who have successfully implanted subcutaneous intrathecal catheter and port systems,<sup>1,2,3</sup> the following technique was offered to six patients in an effort to facilitate repetitive nusinersen administration.

Two Health Canada-approved devices were combined to create each implant system: 1) an intrathecal catheter designed for intrathecal baclofen pumps and 2) an implantable subcutaneous port designed for intravascular medication administration.

The surgical technique was similar for every patient. An incision is opened on the anterior chest wall to implant the port. The port used in our cohort was a Medcomp 5-French MRCTI5084SM. The location of the implants is individualized to suit each patient's anatomy. Placement of the intraspinal catheter is done in a manner analogous to the placement of an intrathecal baclofen pump catheter. In a situation where it is decided to place the catheter in the thoracic or cervical spine, a hemi-laminectomy is performed in order to expose the dura at that level and place the intraspinal catheter under direct vision with countertraction on the dura in order to minimize the risk of spinal cord injury during catheter placement. The Medcomp 5-French catheter is tunneled from the anterior chest wall incision to the posterior spinal incision. The anterior chest was chosen as the site for the port in this case series in an effort to maximize comfort for the patient and to allow the possibility of accessing the port while the patient is seated in their wheelchair. Both implants are then connected and secured to fascia at the posterior spinal incision site. The port is then accessed. Successful aspiration of cerebrospinal fluid (CSF) without resistance confirms patency of the system, which is ready for medication injection at this point if so desired.

Patient	Age at OR	Catheter Insertion	OR time (min)	Scoliosis	Complications
Case 1	26	Cervical	186	Yes	Wound seroma requiring readmission and aspiration
Case 2	2	Lumbar	115 & 69	No	Intrathecal catheter migrated out of spine, requiring a return to OR for replacement
Case 3 (See Figure 1)	14	Thoracic	117	Yes	None
Case 4	19	Thoracic	105	Yes	No CSF return but the system was patent on myelography
Case 5	11	Thoracic	98	Yes	None
Case 6	16	Thoracic	123	Yes	None

Of our six patients, three experienced complications, which we will outline below.

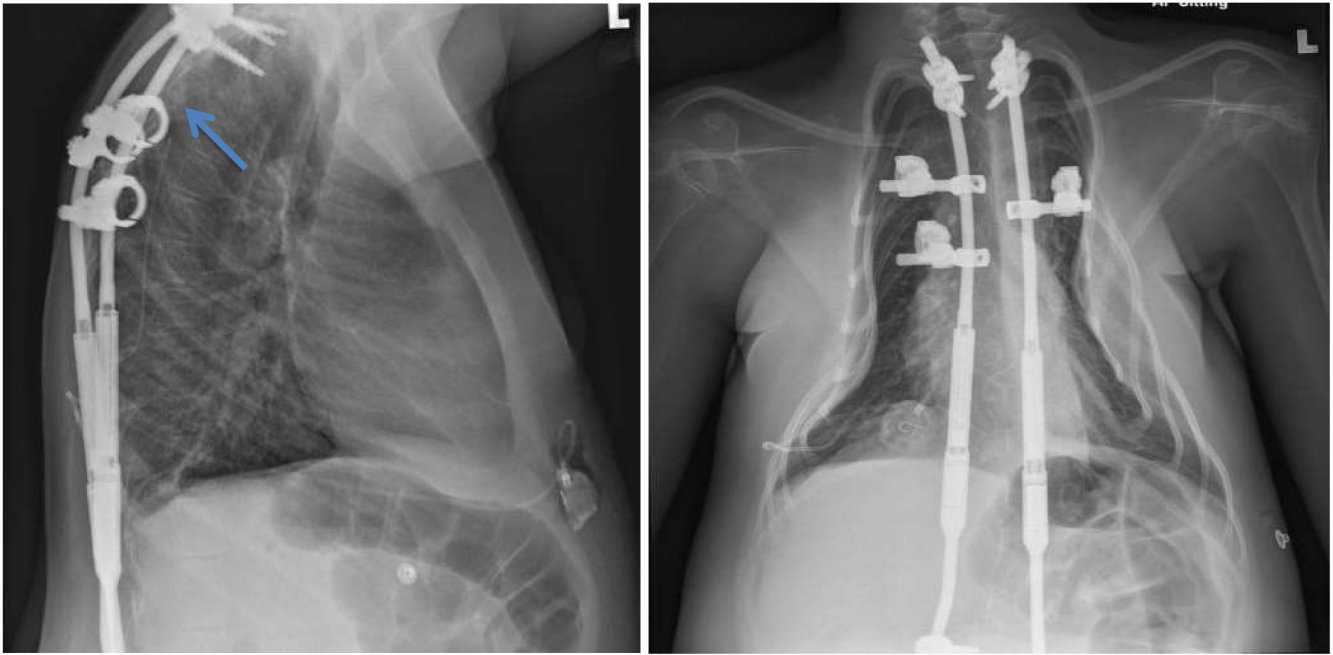
A 26-year-old female with SMA type 2 (Case 1). She is a wheelchair ambulator and has previously undergone scoliosis surgery. Her scoliosis surgery was done in 2003 at the age of 10. Because of her scoliosis construct with sublaminar wires extending from the upper thoracic spine down to the pelvis, it was decided to place her intrathecal catheter in the cervical spine. Ten days after the operation, the patient developed a significant wound seroma, with serosanguinous drainage from the port (anterior chest wall) surgical site. The patient was re-admitted and the incision site was aspirated for cultures, which came back negative. She was started on intravenous cefazolin for 2 days then switched to oral cephalexin for 5 days. The swelling around the port subsided, and eventually went on to heal appropriately.

A 3-year-old female with SMA type 1 who was diagnosed at the age of 5 months (Case II). An intrathecal catheter and port system were implanted, in an effort to facilitate the repeated injections as

**Corresponding author:** Abdulaziz A. Bokeris, 5980 University Ave #5850, Halifax, NS B3K 6R8, Canada. E-mail: [abdulazizbokeris2@gmail.com](mailto:abdulazizbokeris2@gmail.com)

**Cite this article:** Bokeris AA, Restrepo CE, Sheriko J, and McNeely PD. (2024) Subcutaneous Intrathecal Catheter and Port for Repetitive Nusinersen Administration. *The Canadian Journal of Neurological Sciences* 51: 447–448, <https://doi.org/10.1017/cjn.2023.40>

© The Author(s), 2023. Published by Cambridge University Press on behalf of Canadian Neurological Sciences Federation. This is an Open Access article, distributed under the terms of the Creative Commons Attribution licence (<http://creativecommons.org/licenses/by/4.0/>), which permits unrestricted re-use, distribution and reproduction, provided the original article is properly cited.



**Figure 1:** Lateral and AP chest X-ray views demonstrating a thoracic spine subcutaneous intrathecal catheter and port implant. Note the location of the port over the lower aspect of the chest on the right side, with an arrow on the lateral X-ray indicating the location of the catheter tip.

she was requiring anesthesia with every lumbar puncture. She did not have scoliosis hardware, therefore it was decided to place the intrathecal catheter in her lumbar spine. Four weeks post-op, it was found that there was no CSF return when the port was accessed, and there was high resistance to injection. During that visit, the patient received her nusinersen dose through a lumbar puncture. X-rays subsequently revealed that her intrathecal catheter had pulled out from her spine. The catheter was curled up in the subcutaneous tissues of the lumbar spine, outside of the thecal sac. The patient returned to the operating room in order to replace and secure the intrathecal catheter correctly. The system now remains in good working order more than 3 years later.

A 19-year-old male who was diagnosed with SMA type 3 when he was 4 years old (Case III). A thoracic intrathecal catheter and port were placed since he had previously undergone scoliosis surgery with a pedicle screw and rod construct. Two weeks later, the patient was seen for his second nusinersen injection. The port was accessed and the drug was administered without resistance; however, there was no CSF return upon withdrawal raising questions regarding the integrity of the system. A CT myelogram was therefore carried out, confirming a patent system.

All implant procedures in this case series were performed between May 2019 and July 2020. Minor complications (one of these requiring a return to the OR) were encountered early post-op as described above. No further complications have been observed since, and all patients continue to receive their nusinersen therapy via their implants to this day.

Intrathecal administration of nusinersen can be difficult in patients with spinal deformities and those needing anesthesia for its administration. Injecting the drug through an implanted subcutaneous port and intrathecal catheter is an alternative to repeated lumbar punctures. This technique avoids the need for fluoroscopically guided lumbar or C1–C2 punctures in patients

who have undergone scoliosis surgery and avoids the need for anesthesia in younger patients who would otherwise require sedation. We hope that a medical device manufacturer will one day offer an implant that will consist of a catheter and port that can be anchored securely to the patient's anatomy, allowing repeated access to the intrathecal space. This system could resemble current intrathecal pump systems, without the need for a pump.

This case series illustrates the benefits and pitfalls that may be associated with these implants. Catheters may be placed in the cervical, thoracic, or lumbar spine, depending on the patient's anatomy.

**Disclosures.** Jordan Sheriko and P. Daniel McNeely received honoraria from Biogen Canada Inc. The remaining authors have no conflicts of interest to declare.

#### Statement of authorship.

A.B: Chart review and writing the manuscript.  
D.M: Patient selection, consent and reviewing the manuscript.  
J.S: Patient selection and reviewing manuscript.  
C.R: Reviewing the manuscript.

#### References

1. Strauss KA, Carson VJ, Brigatti KW, et al. Preliminary safety and tolerability of a novel subcutaneous intrathecal catheter system for repeated outpatient dosing of nusinersen to children and adults with spinal muscular atrophy. *J Pediatr Orthop.* 2018;38:e610–e617.
2. Iannaccone ST, Paul D, Castro D, Weprin B, Swift D. Delivery of nusinersen through an Ommaya reservoir in spinal muscular atrophy. *J Clin Neuromuscul Dis.* 2021;22:129–34.
3. Shashi KK, Stone SSD, Berde CB, Padua HM. Intrathecal catheter and port placement for nusinersen infusion in children with spinal muscular atrophy and spinal fusion. *Pediatr Radiol.* 2021;51:2588–95.