



# Recommendations for the training and practice of fetal cardiology from the Association of European Paediatric Cardiology

## Continuing Medical Education

**Cite this article:** Dangel JH, Clur S-A, Sharland G, Herberg U, and on behalf of the Fetal Cardiology Working Group of the AEPC (2024) Recommendations for the training and practice of fetal cardiology from the Association of European Paediatric Cardiology. *Cardiology in the Young* **34**: 1839–1848. doi: [10.1017/S1047951124025885](https://doi.org/10.1017/S1047951124025885)

Received: 1 December 2023  
Revised: 23 May 2024  
Accepted: 31 May 2024  
First published online: 11 November 2024

### Keywords:



fetal cardiology; fetal echocardiography; CHDs; fetal arrhythmia; prenatal counselling

### Corresponding author:

Joanna H. Dangel; Email: [jdangel@cmkp.edu.pl](mailto:jdangel@cmkp.edu.pl)

Sally-Ann Clur is the Member of the European Reference Network for rare, low prevalence and complex diseases of the heart - ERN GUARD-Heart (ERN GUARDHEART; <http://guardheart.ern-net.eu>)

Gurleen Sharland is currently retired.

Joanna H. Dangel<sup>1</sup> , Sally-Ann Clur<sup>2</sup>, Gurleen Sharland<sup>3</sup> and Ulrike Herberg<sup>4</sup> , on behalf of the Fetal Cardiology Working Group of the AEPC

<sup>1</sup>Department of Perinatal Cardiology and Congenital Defects, Centre of Postgraduate Medical Education, Warsaw, Poland; <sup>2</sup>Department of Paediatric Cardiology, Emma Children's Hospital, Academic Medical Centre, Amsterdam University Medical Centres, Amsterdam, The Netherlands; <sup>3</sup>Fetal Cardiology Unit, Department of Congenital Heart Disease, Evelina London Children's Hospital, London, UK and <sup>4</sup>Department of Paediatric Cardiology, University Hospital Aachen, University of Aachen, Aachen, Germany

### Abstract

Prenatal detection of cardiac abnormalities has increased significantly over the past few decades, such that fetal cardiology has developed into a sub-specialty of paediatric and congenital cardiology. As this speciality develops further and extends across Europe and more globally, it is important to standardize the requirements for training and subsequent practice, to optimize prenatal diagnosis and perinatal care. In addition to the knowledge and technical skills required to make a correct diagnosis, the counseling of families after diagnosis and the planning of appropriate perinatal management is equally important. The aim of these recommendations is to provide a framework for both basic and advanced training for paediatric cardiologists wishing to practice as fetal cardiologists, as well as highlighting requisites for a fetal cardiology service. All aspects regarding training in fetal cardiology and service provision are addressed including diagnosis, counseling and management.

## Introduction

In the current era of improved and earlier prenatal screening, the prenatal detection of cardiac abnormalities is increasing.<sup>1,2,3</sup> Fetal cardiology has developed into a sub-speciality of paediatric and congenital cardiology, thus warranting recommendations for its practice and training. Guidelines for the practice of fetal cardiology in Europe were first published in 2004<sup>4</sup> and the basic knowledge in fetal cardiology required by an aspirant paediatric cardiologist was described in 2020.<sup>5</sup> An update covering the basic knowledge needed for every paediatric cardiologist in training, the advanced knowledge recommended for the fetal cardiologist, and recommendations for the organisation of a fetal cardiology unit are outlined below. A detailed description of the diagnosis and treatment of fetal cardiac disease was published by the American Heart Association in 2014,<sup>6</sup> and has been updated in 2023.<sup>7</sup> Included are the indications for performing fetal echocardiography, as well as guidelines on how to perform a full fetal echocardiogram and the use of complimentary modalities. Therefore, these will not be addressed again in this document. Since legislation, funding, and organisation of health care systems differ significantly between countries, it is important to appreciate that these recommendations are only intended as a framework, which can be adapted to the individual situation per country.

## The role and responsibility of the fetal cardiologist

### Part of a multidisciplinary team

There are unique aspects of fetal heart disease and fetal circulation that are part of the foundation of knowledge of the fetal cardiologist. As a paediatric cardiologist, a fetal cardiologist also understands the perinatal and postnatal circulations. A fetal cardiologist should have advanced knowledge and be able to perform and evaluate a complete fetal echocardiogram. The fetal cardiologist is responsible for making the final diagnosis of the fetal cardiac problem and guides team decisions regarding pre-, peri-, and postnatal management of the baby. He/ she also provides counselling to the parents. The care of the mother and feto-placental environment problems should be discussed and managed together with an obstetrician or feto-maternal specialist. A fetal cardiologist is an integral part of a multidisciplinary team providing comprehensive care for both the mother and the baby. The composition of this team may vary between countries but, depending on the type of defect detected, will usually include several of the following: a fetal cardiologist, a fetal medicine specialist/perinatologist and/or obstetrician, a

geneticist, a paediatric cardiac surgeon, a paediatric surgeon, a neonatologist, a paediatrician, a psychologist, a paediatric cardiac nurse specialist, a midwife, and a social worker.

### Optimisation of perinatal care

A close cooperation between the obstetrician, fetomaternal specialist, and fetal cardiologist is crucial for optimal perinatal care. The obstetrician is responsible for the mother and the monitoring of the growth and wellbeing of the fetus. The obstetrician or fetomaternal specialist (or the person performing the fetal ultrasound depending on the local setup—such as radiologists, paediatricians, geneticists, or others) should distinguish between the normal and abnormal fetal heart, and depending on their experience may even determine a primary cardiac diagnosis. On suspicion of a fetal cardiac abnormality, the fetal cardiologist should be consulted. We recommend that even if the primary diagnosis is made by an experienced obstetrician or fetomaternal specialist, a referral should always be made to a fetal cardiologist for further assessment. The fetal cardiologist should be responsible for making a complete cardiac diagnosis and then providing appropriate information and counselling to the parents.<sup>8,9,10</sup> In addition to providing a detailed description of the problem, the possible medical, interventional, and/or surgical management should be discussed, along with the early and late prognosis and outcomes. In cases where the diagnosis may not be clear or definite, the uncertainty and limitations should be explained in the counselling and further follow-up arranged. Important aspects of counselling are highlighted in Table 1. The potential for progression of the lesion as pregnancy advances should also be considered. Cardiac defects are evolving lesions, so the final diagnosis may not be fully established in the first trimester and can change with advancing gestation. If a cardiac diagnosis is made in the first trimester, one should acknowledge the limitations of scanning a very small heart and it is recommended that a confirmatory echocardiogram is performed by an experienced fetal cardiologist before a definitive decision is made regarding the final pregnancy course.<sup>11</sup> Where there is a confirmed chromosomal abnormality associated with a suspected heart defect, it is recommended that a fetal cardiologist is consulted and is part of the counselling team assisting the parents in their decision regarding further management. In cases where the parents decide to interrupt the pregnancy, every effort should be made to confirm the diagnosis by the performance of a post-mortem examination by a specialised pathologist if possible.

The fetal cardiologist should be an integral part of the team making the preliminary management plan, including the delivery plan,<sup>6</sup> for fetuses with isolated cardiac defects, as well as those with additional extracardiac malformations and/or genetic disorders. In Table 2, the cardiac defects have been classified according to their severity and necessity for different perinatal strategies.

It has been reported that delivery of babies with CHD before 39 weeks of gestation is not beneficial for further outcomes.<sup>12</sup> Therefore, early delivery should only be planned if there are clear indications, and a vaginal delivery is preferable wherever possible. Each case should be evaluated individually. Of importance is that peripheral flows in fetuses with CHD may differ from healthy fetuses<sup>13</sup> and these differences should be considered while interpreting flow patterns and making decisions regarding the delivery of a baby. Fetuses with critical cardiac defects and those with multiorgan malformations should be delivered at or near specialised centres wherever possible.

### Fetal cardiology unit – what is necessary?

Fetuses with cardiovascular problems should be seen and assessed in fetal cardiology units. These units can be stand-alone units or be integrated into either the obstetric or paediatric cardiology departments.

#### General

##### 1. Aims of the service

- To make an accurate diagnosis of fetal cardiac abnormalities. This includes the diagnosis of structural defects, functional problems, and rhythm disturbances.
- To initiate prenatal treatment when appropriate.
- To arrange further assessment of the baby by a fetomaternal specialist to exclude extracardiac abnormalities where appropriate.
- To provide appropriate counselling and support for parents and families following prenatal diagnosis. This includes providing detailed up to date information about the heart problem, the treatment options before and after birth, and the expected outcomes.
- To communicate results to the referring obstetrician or general practitioner. To plan the further management in collaboration with the obstetrician, and all personnel likely to be involved in the perinatal management after counselling the parents regarding the possible options. This may include continuation of the pregnancy or not, depending on the parental wishes and regulations of the country within which they live. To maintain a database to enable regular audits of activity, quality control, and monitoring of outcomes.

##### 2. Place

- The fetal cardiac unit can be located as an outpatient clinic within or outside the hospital. Close links to the obstetric, genetics, neonatal, paediatric cardiology, and paediatric cardiothoracic surgery departments are necessary. How this type of cooperation is achieved may vary both within countries and between countries.
- Ideally, a minimum of 250–500 fetal heart scans should be performed, and at least 50 fetal cardiac abnormalities should be seen yearly in such a centre.

##### 3. Staff

- A fetal cardiology consultant should be the head of the unit.
- Experienced fetal echocardiography specialists are required to perform the fetal echocardiographic examinations and check screening scans as necessary. Depending on the country, these individuals can be specialised sonographers, radiologists, paediatric cardiologists, obstetricians or fetomaternal specialists, specialist midwives, or specialist clinical nurse practitioners, all of whom should have been trained in scanning the fetal heart.
- Regular interdisciplinary meetings should occur to discuss the prenatally diagnosed cases and their management. Involvement of other specialties include the obstetric team and fetal medicine specialists, midwives, geneticists, neonatologists, and psychologists or equivalent.

##### 4. Equipment

- Premium ultrasound machines with high-quality 2D imaging and functions such as M-Mode, colour Doppler, pulsed Doppler, and continuous wave Doppler, as well as appropriate transducers are required.

**Table 1.** Conditions for and elements of prenatal counselling<sup>7,8,9</sup>

<p><b>Optimal basic conditions</b></p> <ul style="list-style-type: none"> <li>• <b>Time:</b> Counselling should be performed immediately after making the cardiac diagnosis.</li> <li>• <b>Local conditions:</b> Separate room, extra time, no interruptions.</li> <li>• <b>Counsellor:</b> Show empathy, use simple language, adjust to the needs of the parents, consider the impact on the whole family.</li> <li>• <b>Team:</b> Fetal cardiologist is the main counsellor, but the organisation depends on the institution. An experienced obstetrician, geneticist in cases with genetic problems, neonatologists, cardiac surgeon and other specialists as necessary may be involved after the information about the type of cardiac problem and predicted outcome has been given. The presence of a midwife, specialist nurse, psychologist or counsellor – depending on the regional organisation can be beneficial. Ideally both parents should be present during the counselling session.</li> <li>• <b>Counselling from the parent's point of view:</b> functional outcomes and limitations, quality of life, prognosis for an independent life.</li> </ul> <p><b>Elements of prenatal counselling for fetal heart disease:</b></p> <ul style="list-style-type: none"> <li>• <b>Diagnosis:</b> Provide a structural explanation of the normal heart and the diagnosis. Use a hand drawing/ diagram/ heart models/ online material depicting the cardiac defect compared to the normal heart anatomy and discuss the important physiologic alterations from normal.</li> <li>• <b>Prognosis:</b> Give an honest account of the long-term outcomes, expected interventions, neurodevelopmental and functional outcomes, family and long-term issues based on the literature and local outcomes.</li> <li>• <b>Extracardiac abnormalities:</b> Discuss the possible effect these have on the postnatal prognosis and management. Remember some extracardiac disease may only be detected after birth.</li> <li>• <b>Genetic associations and testing:</b> Review the prenatal screening results, discuss possible genetic syndromes or associations and the available prenatal genetic tests.</li> <li>• <b>Diagnostic limitations and uncertainties:</b> Discuss how factors such as gestational age (especially in the first trimester), fetal position, maternal habitus affect the certainty of the diagnosis.</li> <li>• <b>Potential for progression of disease or fetal demise:</b> Discuss any anticipated deterioration and need for follow-up for the remainder of the pregnancy.</li> <li>• <b>Increased risks to outcome:</b> Discuss prematurity, growth restriction, extracardiac abnormalities, heterotaxy syndromes, genetic syndromes, as appropriate.</li> <li>• <b>Fetal cardiac intervention options:</b> Discuss if applicable.</li> <li>• <b>Pregnancy options:</b> Discuss all available options including continuation of pregnancy, termination of pregnancy and compassionate/ palliative care if applicable.</li> <li>• <b>Expected perinatal management:</b> Discuss the expected timing, mode and site of delivery, site of postnatal care, based on the expected management and perinatal risk group.</li> <li>• <b>Expected postnatal management:</b> ICU or neonatal unit admission, vessel cannulation, prostaglandin E1, diagnostic tests (echocardiogram, angiography, CT, MRI), need for immediate postnatal intervention (catheterization or operation); timing and nature of expected cardiac surgery or interventions, survival rates, potential complications.</li> <li>• <b>Expected hospital course and stay in the neonatal period:</b> Ventilation, vasoactive support, feeding issues (nasogastric feedings tube, expressing breast milk); medications; length of stay; practical and economic issues for example parental accommodation and visiting times.</li> <li>• <b>Long-term issues:</b> Expected cardiothoracic or extracardiac surgery or catheterisation, physical limitations, neurodevelopmental issues, cardiology follow-up into adulthood, possible development of heart failure and need of heart transplantation.</li> <li>• <b>Family issues:</b> Planning for parental leave from work and home; housing needs, financial considerations, insurance issues, psychological support, sibling support.</li> <li>• <b>Allow parents to express their sorrows, fears and uncertainties</b> and ask parents if they need further support (e.g. psychologist, social worker etc.).</li> <li>• <b>Offer resources for parents:</b> Provide written materials on the heart defect, of postnatal therapeutic interventions, websites for CHD information, information on support groups; offer to connect parents with other CHD families with a similar diagnosis.</li> <li>• <b>Provide contact information:</b> For fetal nurse coordinator and fetal cardiology physician and offer continued support during pregnancy.</li> <li>• <b>If possible, provide tours:</b> Of delivery department, neonatal or cardiac intensive care units, or organise the special course for parents expecting the delivery of the child with a cardiac problem.</li> </ul>
--

CHD = congenital heart disease, CT = computerized tomography, ICU = intensive care unit, and MRI = magnetic resonance imaging.

- The ultrasound machine should have obstetric and cardiac calculation packages.

In tertiary centres, it may be of benefit to perform advanced techniques for fetal cardiac imaging, such as 3/4D imaging as spatio-temporal image correlation or real-time 4D echocardiography, as well as power Doppler and tissue Doppler.

#### 5. Database

- All studies should be recorded and stored, preferably in DICOM format or as advised for compatibility with the local IT system.
- A database should be available for the recording of patient and pregnancy data. The reason for referral for fetal echocardiography, family history, maternal health, drugs taken during pregnancy, results of first-trimester screening if available, and any other relevant history should be recorded. A detailed description of the study including the final diagnosis and recommendation for further management should be available. It is recommended to use the International Paediatric and Congenital Cardiac Code in conjunction with the International Society for Nomenclature of Paediatric and Congenital Heart Disease<sup>14</sup> for the cardiac diagnosis.

- The legal requirements may differ per country, but patient privacy should be always protected.

#### 6. Reports

- A written report should be provided after each examination and the patient should have access to a copy.
- The report should include the diagnosis and recommendations for the further management pre-, peri-, and postnatally. The final conclusions and recommendations should be written as the commentary in the report or in a separate consultant letter, depending on the regional organisation of the medical care.

#### 7. Follow-up

- Follow-up after live birth, stillbirth, intrauterine death, and termination of pregnancy should be sought, and where available, the data entered into the database.

### Training

One of the aims of the Association for European Paediatric and Congenital Cardiology has been to provide recommendations for training requirements for certification as a paediatric cardiologist in Europe. The training for specialisation in paediatric cardiology should include a general knowledge of

**Table 2.** Management of specific groups of fetal cardiac defects

<p><b>1. Critical congenital heart defects</b> in which emergency treatment of the neonate is necessary based on the prenatal diagnosis—<b>precise perinatal organisation is mandatory</b></p> <ul style="list-style-type: none"> <li>• Transposition of the great arteries with restrictive oval foramen (be aware of the risk of persistent pulmonary hypertension)</li> <li>• Hypoplastic left heart syndrome with severely restrictive/ closed oval foramen (prenatal treatment is possible)</li> <li>• Mitral valve dysplasia syndrome</li> <li>• Ebstein's anomaly of the tricuspid valve or tricuspid valve dysplasia with "circular shunt"</li> <li>• Restrictive total anomalous pulmonary venous connection (very difficult prenatal diagnosis)</li> </ul>
<p><b>2. Critical congenital defects with regurgitant valves and or cardiac overload</b> in which emergency treatment of the neonate might be necessary based on the prenatal diagnosis—<b>precise perinatal organisation is mandatory</b></p> <ul style="list-style-type: none"> <li>• Common arterial trunk with dysplastic regurgitant truncal valve</li> <li>• Absent pulmonary valve syndrome</li> <li>• Aorto-left ventricular tunnel</li> <li>• Atrio-venous fistulas (pulmonary, hepatic, vein of Galen malformation etc.)</li> <li>• Atrioventricular septal defect with severe valve regurgitation and prenatal heart failure</li> </ul>
<p><b>3. Critical ductal dependent congenital heart defects</b> in which intravenous prostaglandin E1 should stabilise the neonatal condition</p> <ul style="list-style-type: none"> <li>• Left heart lesions: aortic stenosis, hypoplastic left heart syndrome</li> <li>• Other systemic ductal dependent lesions in more complex forms of cardiac defects (tricuspid atresia with transposition of the great arteries, double inlet left ventricle with hypoplastic aortic arch etc.)</li> <li>• Transposition of the great arteries with wide interatrial communication</li> <li>• Double outlet right ventricle – transposition type (Taussig – Bing anomaly)</li> <li>• Critical pulmonary stenosis and pulmonary atresia with intact ventricular septum</li> <li>• Other ductal dependent pulmonary circulation (all defects in which there is a left to right or bi-directional shunt across the arterial duct on fetal echocardiography)</li> <li>• Coarctation of the aorta or interrupted aortic arch</li> </ul>
<p><b>4. Severe congenital heart defects</b> in which emergency neonatal treatment is usually not necessary, but cardiac surgery will be necessary usually in the first year of life.</p> <ul style="list-style-type: none"> <li>• Tetralogy of Fallot with antegrade pulmonary flow, well-developed pulmonary arteries and no signs of ductal dependency</li> <li>• Double outlet right ventricle—Fallot type, as above</li> <li>• Common arterial trunk with good truncal valve</li> <li>• Univentricular atrioventricular connection with no evidence of pulmonary or aortic obstruction and well-developed pulmonary arteries and aorta</li> <li>• Complex congenital heart disease associated with abnormalities of cardiac position and situs with well-developed pulmonary arteries and aorta, and no evidence of outflow tract obstruction</li> <li>• Atrioventricular septal defect</li> </ul>
<p><b>5. Mild to moderate cardiac defects</b> requiring treatment usually later in life, but neonatal evaluation should be performed</p> <ul style="list-style-type: none"> <li>• Mild to moderate pulmonary stenosis</li> <li>• Mild to moderate aortic stenosis</li> <li>• Right aortic arch/double aortic arch</li> </ul>
<p><b>6. Cardiac findings</b> requiring no immediate postnatal treatment</p> <ul style="list-style-type: none"> <li>• Small muscular ventricular septal defects</li> <li>• Hyperechogenic focus</li> <li>• Premature atrial contractions</li> <li>• Anomalous origin of the right subclavian artery (ARSA)</li> </ul>
<p><b>7. Cardiac problems unique for fetuses</b></p> <ul style="list-style-type: none"> <li>• Premature restriction/ closure of the arterial duct—risk of pulmonary hypertension of the newborn</li> <li>• Right ventricular outflow tract obstruction or atresia due to twin-to-twin transfusion syndrome</li> <li>• Hypertrophic cardiomyopathy due to twin-to-twin transfusion syndrome</li> <li>• Hypertrophic cardiomyopathy due to maternal diabetes</li> <li>• Premature closure of the oval foramen—in fetuses with normal anatomy of the cardiovascular system commonly secondary to arrhythmia (junctional ectopic tachycardia, atrial ectopic tachycardia)</li> <li>• Ductus venosus agenesis—difference between intrahepatic and extrahepatic type and its consequence for the prenatal and perinatal period.</li> </ul>
<p><b>8. Fetal arrhythmia</b></p> <ul style="list-style-type: none"> <li>• Supraventricular tachycardia or atrial flutter</li> <li>• Ventricular tachycardia</li> <li>• Complete congenital atrioventricular block with normal cardiac anatomy (check for SS-A and SS-B antibodies)</li> <li>• Complete atrioventricular block with congenital heart disease (CHD) (most commonly left atrial isomerism or double discordance)</li> <li>• Fetal sinus bradycardia (risk for long QT syndrome—neonatal electrocardiogram mandatory)<sup>32</sup></li> </ul>
<p><b>9. Palliative care planned before delivery</b><sup>33</sup> (e.g. CHD with lethal chromosomal abnormality, severe CHD with cardiomyopathy and cardiac failure if transplantation in not available or is not an option) Always after extensive counselling</p> <ul style="list-style-type: none"> <li>• Psychological support mandatory</li> <li>• Vaginal delivery with full support for both parents</li> <li>• Possibility to be with a baby for as long as possible</li> <li>• Possibility for home palliative care if available</li> </ul>



fetal cardiology, preferably introduced after a basic understanding of general paediatric cardiology has been ascertained.<sup>5</sup> Should the trainee wish to become a consultant in fetal cardiology, he/she/they should then follow a more extensive educational programme (See 4.2).

### *Prenatal cardiology training for the aspirant Association of European Paediatric Cardiology paediatric cardiologist*

The paediatric cardiologist does not have to perform a fetal echocardiogram but should be able to interpret fetal cardiac examinations performed by a sonographer/other person and their reports, be able to detect warning signs, discuss possible treatment options, and know what care the baby will require after birth.<sup>5</sup>

The following educational activities are recommended:

- Fetal cardiology course—a national or an Association of European Paediatric Cardiology internationally approved course.
- 1–2 weeks training in a referral centre for fetal cardiology (this can be divided into days, with a total of 10 days).

### *Theoretical knowledge required*

#### 1. Knowledge of screening:

- The trainee must know the indications for referral for fetal echocardiography. This includes the high-risk groups<sup>6</sup> but as most babies with CHD are born to mothers with no recognisable risk factors, knowledge of screening in the low-risk population is essential. This typically occurs during the obstetric anomaly scan around 18–22 gestational weeks.
- The trainee should have a clear knowledge of the different cardiac views used for screening as well as their benefits and pitfalls. These views are the abdominal situs view, the four-chamber view, the left ventricular outflow tract view, the right ventricular outflow tract view, and the three-vessel and trachea view (Table 3, Fig. 1).
- The trainee should be familiar with first-trimester screening markers for CHD, such as an increased nuchal translucency, abnormal venous duct flow, and tricuspid regurgitation, and know what action to take when the screening is abnormal.<sup>15</sup>
- Additionally, in some countries, cardiac screening is now occurring during a 12–14 week anomaly scan, and the trainee should have an understanding of the potential and limitations of the early scan.

#### 2. Embryology of the cardiovascular system.

#### 3. Physiology of the fetal cardiovascular system in various periods of pregnancy:<sup>16</sup>

- Fetal circulation: importance of the essential shunts; the oval foramen, venous duct, and the arterial duct.
- Fetal physiology, pathophysiology, and cardiac function and how this differs from the postnatal physiology. Knowledge of cardiovascular problems that can deteriorate during pregnancy and why (examples can be seen in sections 2 and 8 of Table 2). Understanding which heart defects will be dependent on one or more of the prenatal essential shunts postnatally and the postnatal management they require.

- Transitional circulation in healthy cases and those with cardiovascular problems.
  - Conditions causing a high cardiac output (see Tables 2 and 4 for some examples).
4. Segmental analysis of CHD.
  5. Genetic problems:
    - Knowledge of the associations between specific CHD and genetic problems.
    - Knowledge of the currently available genetic tests, their indications, and their interpretation in cooperation with geneticists.
  6. Prenatal evolution of CHD. This is of particular importance in the current era of increasing early fetal echocardiography.
  7. Indications for prenatal cardiac interventions.
  8. Fetal arrhythmia:
    - The patient with fetal arrhythmia should be referred to a fetal cardiologist for further diagnosis and management.
    - Knowledge of the normal fetal heart rate in different periods of pregnancy.<sup>17</sup>
    - Ability to recognise a fetal tachycardia<sup>18</sup> and abnormal heart rhythms in the fetus (recognition of abnormal M-mode and Doppler recordings).
    - Knowledge of the differentiation and significance of atrial and ventricular ectopy.
    - Ability to recognise fetal bradycardia<sup>19</sup> and the risk of long QT syndrome.<sup>20,21</sup>
    - Ability to recognise congenital heart block.
    - How to organise care of pregnant women with positive SS-A and SS-B antibodies.<sup>22</sup>
    - How to treat a fetus with an arrhythmia and avoid premature delivery if possible.
  9. Fetal cardiac failure and cardiomyopathies:
    - Understanding of scores for the assessment of fetal heart failure (for example, the Cardiovascular Profile Score).<sup>23</sup>
    - The differences between prenatal and postnatal causes of cardiac failure and treatment options.
  10. Functional changes in the fetal cardiovascular system:
    - Tricuspid regurgitation.
    - Disproportion between right and left side of the heart.
    - Regurgitation of the other cardiac valves (mitral, aortic, and pulmonary).
    - Prenatal closure/restriction of the arterial duct and/or oval foramen:
      - Aetiology
      - Consequences for the neonatal condition
      - Perinatal management/treatment options.
  11. Communication skills
    - For good continuation of care postnatally, an awareness of prenatal counselling and documentation there of is necessary.<sup>7</sup>

### *Advanced training programme to become an Association of European Paediatric Cardiology consultant in fetal cardiology*

In addition to the basic knowledge of fetal cardiology listed above, a consultant in fetal cardiology should have knowledge of performing a basic general fetal ultrasound examination and must be able to perform a complete detailed fetal echocardiogram. (Table 3, Figure 2).

**Table 3.** What a fetal heart evaluation should include—screening and advanced fetal echocardiography

SCREENING	
Abdominal cavity—situs	Stomach on the left side, Intrahepatic part of the umbilical vein Ductus venosus to the inferior caval vein (IVC) Descending aorta on the left side IVC on the right side, anterior and to right of the aorta
Position of the heart	Within the chest Apex to the left 1/3 on the left side; 2/3 on the right side Cardiac axis approximately 45°
Size of the heart	1/3 of the chest (Heart area/Chest area 0,25 – 0,35)
Four-chamber view	Right and left side equal in size and formed the apex Right and left ventricles similar contractility Both atrioventricular valves open and close equally Tricuspid valve slightly more apical insertion Foramen ovale flap visible in the left atrium (LA) Thoracic aorta on the left side
Outflow tracts	Aorta (Ao) arises from the left ventricle (LV), and is the first vessel seen moving up from four-chamber view Pulmonary artery arises anteriorly from the right ventricle (RV), The Ao and pulmonary artery (PA) crossover in their direction when leaving heart
Mediastinum	<i>Three vessel view:</i> Three vessels visible, superior caval vein (SVC), Ao and PA from right to left. PA > Ao > SVC <i>Three vessel and trachea view:</i> Ductal arch < aortic arch Ductal and aortic arch meet in 'V' to left of the trachea
Fetal heart rhythm	Between 130 and 170 bpm, depending on the gestational age
FULL FETAL ECHOCARDIOGRAPHY – SEGMENTAL ANALYSIS	
Veno – atrial connection	<i>Sagittal view</i> ICV and SCV to the right atrium (RA) <i>4 chamber and /or short axis view</i> Pulmonary veins to the left atrium (colour or power Doppler important)
Atrio -ventricular connections	<i>4 chamber view and short axis views</i> LA connected to the LV through the mitral valve (MV) RA connected to the RV through the tricuspid valve (TV), which inserts more apically than MV
Ventriculo – arterial connections	Aorta arises from the LV ( <i>5 chamber view, lateral view</i> ) Pulmonary artery arises from the RV ( <i>long axis view, short axis view</i> )
Morphology of the ventricles	
Left ventricle	<i>4 chamber view, lateral view, short axis view</i> Ellipsoid shape MV is not attached to the septum, but to the papillary muscles on the free wall Two papillary muscles seen Smooth ventricular septum
Right ventricle	<i>4 chamber view, lateral view, short axis view</i> Triangle shape Moderator band and trabeculations in the apex TV attached to the anterior wall and the ventricular septum, closer to the apex
Outflow tracts	
LV Outflow Tract	<i>Long axis view</i> Ventricular septum – anterior aortic wall continuity Anterior mitral valve leaflet – posterior aortic wall continuity <i>Long and short axis views</i> Aortic valve leaflets open and close
RV Outflow Tract	<i>Short and long axes views</i> PA anteriorly from the RV Both branches of PA are seen Arterial duct (AD) connected to the descending aorta, caudally to the aortic arch
Arches	<i>Sagittal view</i> Aortic arch upper Ductal arch lower

(Continued)

Table 3. (Continued)

SCREENING	
FULL FETAL ECHOCARDIOGRAPHY -DOPPLER	
Colour Doppler	The flow in the fetal cardiovascular system should not be turbulent with correct machine settings, except for the venous duct. In some situations, Colour Doppler may be helpful in the appreciation of anatomy (identification of pulmonary veins and in the young fetus, for example).
Intracardiac Doppler	Flow through both atrioventricular valves: character of flow, duration of flow, velocity of A and E waves, regurgitant flow—describe
Pulmonary artery and aortic flow	Measurements just above the semilunar valves
Peripheral pulmonary artery flow	If necessary
Aortic isthmus flow	Always towards the descending aorta
Ductus arteriosus flow	The highest velocity <2 m/s; Pulsatility Index >1.95
Pulmonary vein flow	From both the right and left side, always towards the LA
Systemic veins flow	Reversed A wave always present (<20cm/s)
Peripheral Doppler	Umbilical artery and veins, middle cerebral artery, ductus venosus

#### Additional knowledge recommended

- Basic knowledge of obstetric ultrasound<sup>24</sup> and other commonly used diagnostic methods in obstetrics<sup>25</sup>:
  - Fetal position, how to distinguish between left and right of the baby.
  - Fetal biometry.
  - Doppler flow patterns of specific fetal vessels such as the venous duct, arterial duct, umbilical vessels, and middle cerebral artery in different periods of pregnancy and their interpretation.
  - General knowledge of cardiotocography interpretation and its limitations in cases of fetal arrhythmia and other cardiac problems.
  - Diagnosis of the hyperdynamic fetal circulation and its interpretation in cases of fetal anaemia, placental chorioangiomas,<sup>26</sup> or fetal atrio-venous malformations.
  - Ultrasonographic markers of genetic abnormalities.
  - Extracardiac disease (see Table 4).
  - Placenta—position and appearance.
- Safety of the ultrasound examination, thermal and mechanical index.
- How to perform a complete fetal echocardiogram (see Table 3).<sup>27</sup>
- Detailed description of fetal wellbeing (scoring systems).<sup>21</sup>
- Knowledge of new techniques in fetal echocardiography and other diagnostic methods—indication, feasibility, and limitations:
  - Tissue Doppler.
  - Speckle tracking.
  - Three-dimensional and 4D fetal echocardiography.
  - Fetal cardiac MRI
  - Magnetocardiography.
- Indications for genetic testing in various cardiac defects.
- Specific knowledge of fetal cardiac defects and their management (See Table 2).
- The role of prenatal cardiac interventions.

The fetal cardiologist should be aware that cardiac interventions can be performed successfully in experienced centres worldwide.<sup>28</sup>

The aim of these interventions is to diminish the ultimate severity of the defect by altering the prenatal natural history,<sup>29</sup> decrease the symptoms of fetal cardiac failure, or save life before or after birth.

There are three groups of fetuses, who possibly might benefit from fetal cardiac interventions:

- critical aortic stenosis with impaired left ventricular function/evolving hypoplastic left heart syndrome,<sup>30</sup>
- membranous pulmonary atresia or severe pulmonary stenosis with intact ventricular septum and impaired function of the right ventricle,<sup>31</sup>
- hypoplastic left heart syndrome with closed or highly restrictive interatrial septum.

National and international cooperation with experienced centres is thus advised. Careful follow-up programmes are mandatory to check long-term outcomes in comparison to those children without prenatal treatment.

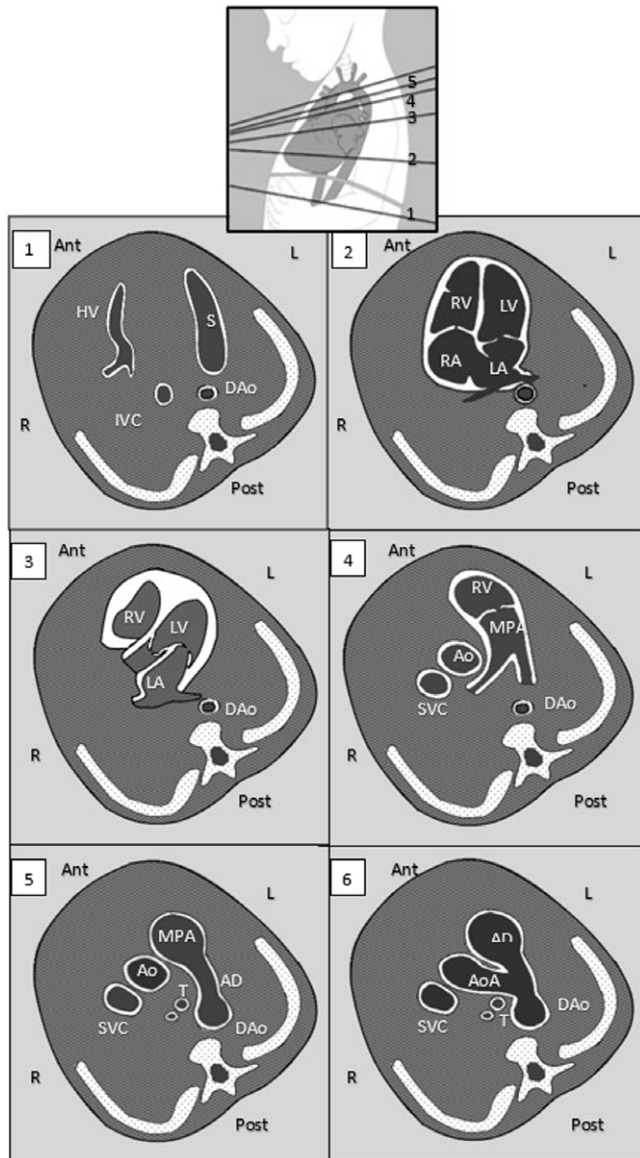
- Obstetric problems, extracardiac malformations and pharmacotherapy affecting the fetal cardiovascular system (see Table 4).
- Ethics and special problems in prenatal cardiology.

This is very important as prenatal diagnosis has always raised many ethical dilemmas and discussions. Counselling should be individualised and take the regional/national legislation regarding pregnancy termination into consideration.

The fetal cardiologist should have knowledge of and understand the following:

- Laws in different countries concerning termination of pregnancy
- Lethal fetal problems
- Compassionate care and perinatal hospice

- Counselling: See Table 1<sup>7,8,9</sup>
- Additionally, a fetal cardiologist should be able to:
  - Explain indications and limitations of fetal echocardiography.
  - Explain the necessity for genetic tests.



**Figure 1.** wFetal cardiac screening views. 1: abdominal situs view. DAo = descending aorta, HV = hepatic vein, IVC = inferior caval vein, S = stomach. 2: four chamber view. LA = left atrium, LV = left ventricle, RA = right atrium, RV = right ventricle. 3: left ventricular outflow tract view. 4: right ventricular outflow tract view. Ao = aorta, MPA = main pulmonary artery, SVC = superior caval vein. 5: three vessel view. AD = arterial duct, T = trachea. 6: three vessel and trachea view. Ant = anterior, L = left, post = posterior, R = right.

- Decide when a fetal MRI is indicated.
- Arrange appropriate follow-up and plan perinatal care.
- Provide a full report after each examination.

#### Practical training requires

- In total, 200 normal full fetal echocardiograms were performed independently.
- Fifty fetal echocardiograms were performed in cases with cardiac abnormalities, with full reports and parental counselling.
- Ability and knowledge to perform obstetric Dopplers in conjunction with fetal medicine specialists: umbilical artery, umbilical vein, venous duct, middle cerebral artery, and uterine arteries.

**Table 4.** Obstetric problems, extracardiac malformations and pharmacotherapy affecting the fetal cardiovascular system

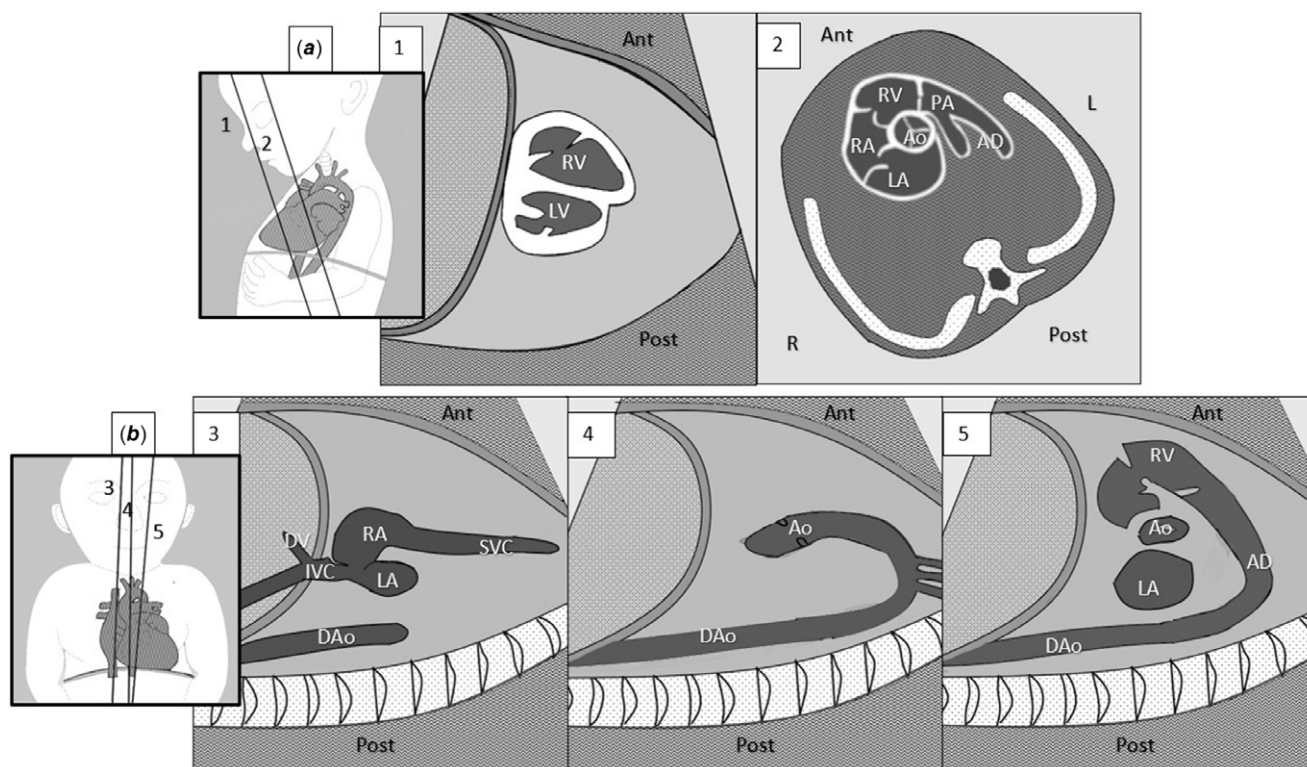
<p><b>Fetal hydrops</b></p> <ul style="list-style-type: none"> <li>• Immune and non-immune hydrops</li> <li>• Fetal hydrops and fetal heart failure</li> </ul>
<p><b>Cardiac signs in fetuses with anaemia</b></p>
<p><b>Extracardiac malformations affecting the cardiovascular system</b></p> <ul style="list-style-type: none"> <li>• Congenital diaphragmatic hernia,</li> <li>• Congenital pulmonary airway malformation,</li> <li>• Omphalocele,</li> <li>• Gastroschisis,</li> <li>• Renal agenesis and severe failure,</li> <li>• Skeletal dysplasia,</li> <li>• Sacro-coccygeal teratoma,</li> <li>• Vascular malformations and shunts: vein of Galen aneurysm, pulmonary vascular malformations, liver vascular malformations, placental aneurysm, abnormal, placento-fetal circulation such as absent venous duct, and the implications for the foetal and postnatal condition.</li> </ul>
<p><b>Fetal cardiac problems in multiple pregnancy</b></p> <ul style="list-style-type: none"> <li>• Twin-to-twin transfusion syndrome,</li> <li>• Twin anaemia - polycythaemia syndrome,</li> <li>• Twin reverse arterial perfusion - acardiac twin,</li> <li>• Conjoined twins.</li> </ul>
<p><b>Drugs and the fetal cardiovascular system. Knowledge of drugs and food which can potentially restrict the arterial duct.</b></p>

- Preparation of the history and perinatal course of the disease in at least 20 fetuses with CHD.
- Presentation and discussion of the results of fetal echocardiography examinations and the postnatal diagnosis.
- Participation in decision-making for final diagnosis, perinatal organisation, and possible fetal therapy.
- Take part with an experienced fetal cardiologist during fetal cardiac sessions: counselling and giving bad news, be aware of the necessity of psychological support for parents.
- Participate in research in an institution where fetal cardiology training is provided.
- Cooperation with obstetricians, fetomaternal specialists, geneticists, and neonatologists should be an obligatory part of such training and interventional treatment in a fetus with a cardiac problem.

#### Duration of training and evaluation of knowledge

In general, it should take about 1–2 years to become a consultant in fetal cardiology with the trainee participating in fetal cardiology clinics and case discussion sessions at least once a week. However, this will vary depending on the size of the unit and the number of weekly sessions undertaken. Consequently, the supervisor should have the right to decide when the trainee's knowledge is sufficient to become a consultant in fetal cardiology within the framework of local national regulations. Participation in international fetal cardiology live courses and webinars is recommended, as well as scientific activity in the field of fetal cardiology with the publication of at least one paper on a fetal cardiology topic. Passing a theoretical and practical exam is advised. The practical exam should consist of two parts: performance of a full fetal echocardiography examination in a healthy fetus and one with a severe cardiac defect, with a full report and parental counselling. The final decisions regarding who will become a fetal cardiologist will differ between countries, according to the national health care systems.





**Figure 2.** Advanced cardiac views. A1: biventricular view. LV = left ventricle, RV = right ventricle, A2: short axis view. AD = arterial duct, ao = aorta, LA = left atrium, RA = right atrium, B3: bicaaval view. DAo = descending aorta, DV = venous duct, IVC = inferior caval vein, SVC = superior caval vein. B4: sagittal aortic arch view. Ao = aorta, MPA = main pulmonary artery, SVC = superior caval vein. B5: sagittal arterial duct view. Ant = anterior, L = left, post = posterior, R = right.

### Social media synopsis

Association of European Paediatric Cardiology fetal cardiology recommendations highlight that a paediatric cardiologist should always make the final fetal cardiac diagnosis and provide counselling to parents.

### References

- Carvalho JS, Allan LD, Chaoui R, et al. ISUOG Practice Guidelines (updated): sonographic screening examination of the fetal heart. *Ultrasound Obstet Gynecol* 2013; 41 (3): 348–359.
- van Velzen CL, Clur SA, Rijlaarsdam ME, et al. Prenatal detection of congenital heart disease—results of a national screening programme. *BJOG* 2016; 123 (3): 400–407.
- Everwijn SMP, van Nisselrooij AEL, Rozendaal L, et al. The effect of the introduction of the three-vessel view on the detection rate of transposition of the great arteries and tetralogy of Fallot. *Prenat Diagn* 2018; 38 (12): 951–957.
- Allan L, Dangel J, Fesslova V, et al. Recommendations for the practice of fetal cardiology in Europe. *Cardiol Young* 2004; 4 (1): 109–114.
- Heying R, Albert DC, Voges I, et al. Association for European Paediatric and Congenital Cardiology recommendations for basic training in paediatric and congenital cardiology 2020. *Cardiol Young* 2020; 30 (11): 1572–1587.
- Donofrio MT, Moon-Grady AJ, Hornberger LK, et al. Diagnosis and treatment of fetal cardiac disease: a scientific statement from the American Heart Association. *Circulation* 2014; 129 (21): 2183–2242.
- Moon-Grady AJ, Donofrio MT, Gelehrter S, et al. Guidelines and recommendations for performance of the fetal echocardiogram: an update from the American Society of Echocardiography. *J Am Soc Echocardiogr* 2023; 36 (7): 679–723.
- Keelan JA, Moon Grady AJ, Arya B, et al. Current state of fetal heart disease counseling and training: room for improvement?: endorsed by the Fetal Heart Society. *Pediatr Cardiol* 2022; 43 (7): 1548–1558.
- Lee CK. Prenatal counseling of fetal congenital heart disease. *Curr Treat Optics Cardiovasc Med* 2017; 19 (1): 5.
- Kovacevic A, Elsässer M, Fluhr H, et al. Counseling for fetal heart disease—current standards and best practice. *Transl Pediatr* 2021; 10 (8): 2225–2234.
- Jicinska H, Vlasin P, Jicinsky M, et al. Does first-trimester screening modify the natural history of congenital heart disease? Analysis of outcome of regional cardiac screening at 2 different time periods. *Circulation* 2017; 135 (11): 1045–1055.
- Costello JM, Polito A, Brown DW, et al. Birth before 39 weeks' gestation is associated with worse outcomes in neonates with heart disease. *Pediatrics* 2010; 126 (2): 277–284.
- Mebius MJ, Clur SAB, Vink AS, et al. Growth patterns and cerebroplacental hemodynamics in fetuses with congenital heart disease. *Ultrasound Obstet Gynecol* 2019; 53 (6): 769–778.
- [www.IPCCC.net](http://www.IPCCC.net).
- Nicolaidis KH, Heath V, Cicero S. Increased fetal nuchal translucency at 11–14 weeks. *Prenat Diagn* 2002; 22 (4): 308–315.
- Dangel J. Changing physiology in the first- to third-trimester foetal circulation. *Cardiol Young* 2014; 24 (S2): 13–18.
- Mitchell JL, Cuneo BF, Etheridge SP, Horigome H, Weng H-Y, Benson DW. Fetal heart rate predictors of long QT syndrome. *Circulation* 2012; 126 (23): 2688–2695.
- O'Leary ET, Alexander ME, Bezzerides VJ, et al. Low mortality in fetal supra-ventricular tachycardia: outcomes in a 30-year single-institution experience. *J Cardiovasc Electrophysiol* 2020; 31 (5): 1105–1113.
- Cuneo BF, Strasburger JF. We only find what we look for: fetal heart rate and the diagnosis of long-QT syndrome. *Circ Arrhythmia Electrophysiol* 2015; 8 (4): 760–762.
- Cuneo BF, Strasburger JF, Wakai RT. The natural history of fetal long QT syndrome. *J Electrocardiol* 2016; 49 (6): 807–813.

21. Clur SB, Vink AS, Etheridge SP, et al. Left ventricular isovolumetric relaxation time is prolonged in fetal long-QT syndrome. *Circ Arrhythmia Electrophysiol* 2018; 11 (4): e005797.
22. Mawad W, Hornberger L, Cuneo B, et al. Outcome of antibody-mediated fetal heart disease with standardized anti-inflammatory transplacental treatment. *J Am Heart Assoc* 2022; 11 (3): e023000.
23. Huhta JC. Diagnosis and treatment of foetal heart failure: foetal echocardiography and foetal hydrops. *Cardiol Young* 2015; 25 (S2): 100–106.
24. Norton ME, Scoult LM, Veldstein VA. *Callen's Ultrasonography in Obstetrics and Gynecology*. 6th edn. Oxford: Elsevier, 2016.
25. Mounghmaithong S, Lam MSN, Kwan AHW, et al. Prediction of labour outcomes using prelabour computerised cardiotocogram and maternal and fetal Doppler indices: a prospective cohort study. *BJOG* 2024; 131 (4): 472–482.
26. Buca D, Iacovella C, Khalil A, et al. Perinatal outcome of pregnancies complicated by placental chorioangioma: systematic review and meta-analysis. *Ultrasound Obstet Gynecol* 2020; 55 (4): 441–449.
27. Lee W, Allan L, Carvalho JS, et al. ISUOG consensus statement: what constitutes a fetal echocardiogram? *Ultrasound Obstet Gynecol* 2008; 32 (2): 239–242.
28. Friedman KG, Tworetzky W. Fetal cardiac interventions: where do we stand? *Arch Cardiovasc Dis* 2020; 113 (2): 121–128.
29. Tulzer A, Arzt W, Gitter R, et al. Valvuloplasty in 103 fetuses with critical aortic stenosis: outcome and new predictors for postnatal circulation. *Ultrasound Obstet Gynecol* 2022; 59 (5): 633–641.
30. Patel ND, Nageotte S, Ing FF, et al. Procedural, pregnancy, and short-term outcomes after fetal aortic valvuloplasty. *Catheter Cardiovasc Interv* 2020; 96 (3): 626–632.
31. Hogan WJ, Grinenco S, Armstrong A, et al. Fetal cardiac intervention for pulmonary atresia with intact ventricular septum: international fetal cardiac intervention registry. *Fetal Diagn Ther* 2020; 7 (10): 1–9.
32. Cuneo BF, Kaizer AM, Clur SA, et al. Mothers with long QT syndrome are at increased risk for fetal death: findings from a multicenter international study. *Am J Obstet Gynecol* 2020; 222 (3): 263.e1–263.e11.
33. Dangel T, et al. Standards of perinatal palliative care 2019. <https://perinata.lne.pl/pl/a/standards-and-medical-procedures-for-pediatric-palliative-home-care>.