



# The effect of anti-scatter grids on radiation exposure during transcatheter patent ductus arteriosus closure in premature infants



## Original Article

**Cite this article:** Khallaf M, Aldoss O, Bischoff AR, Windsor J, Stopak J, Mukundan C, McNamara PJ, and Mohammad Nijres B (2025) The effect of anti-scatter grids on radiation exposure during transcatheter patent ductus arteriosus closure in premature infants. *Cardiology in the Young* **35**: 361–367. doi: [10.1017/S1047951124036382](https://doi.org/10.1017/S1047951124036382)

Received: 24 November 2023  
Revised: 16 October 2024  
Accepted: 11 November 2024  
First published online: 13 December 2024

**Keywords:**  
premature infants; patent ductus arteriosus closure; radiation

**Corresponding author:**  
Bassel Mohammad Nijres;  
Email: [bassel.publication@gmail.com](mailto:bassel.publication@gmail.com)

Mohamed Khallaf<sup>1,2</sup>, Osamah Aldoss<sup>1,3</sup>, Adrienne Rahde Bischoff<sup>4</sup> ,  
Jimmy Windsor<sup>5</sup>, Joshua Stopak<sup>5</sup>, Chaitra Mukundan<sup>5</sup>, Patrick J. McNamara<sup>4</sup> and  
Bassel Mohammad Nijres<sup>1,6</sup> 

<sup>1</sup>Division of Pediatric Cardiology, University of Iowa Stead Family Children's Hospital, Iowa City, IA, USA; <sup>2</sup>Mount Sinai Kravis Children's Heart Center, The Mount Sinai Hospital, New York, NY, USA; <sup>3</sup>Pediatric Cardiology, Herma Heart Institute, Children's Wisconsin and the Medical College of Wisconsin, Milwaukee, USA; <sup>4</sup>Division of Neonatology, University of Iowa Stead Family Children's Hospital, Iowa City, IA, USA; <sup>5</sup>Division of Pediatric Anesthesia, University of Iowa Stead Family Children's Hospital, Iowa City, IA, USA and <sup>6</sup>Pediatric Cardiology, King Faisal Specialist Hospital and Research Centre, Jeddah, Saudi Arabia.

### Abstract

**Background:** Radiation exposure and the effect of anti-scatter grids are not well studied in premature infants during transcatheter patent ductus arteriosus closure.

This study aimed to investigate whether the use of anti-scatter grids altered the level of radiation exposure to premature infants undergoing transcatheter patent ductus arteriosus closure. **Methods and Results:** Demographic and radiation exposure data for premature infants who underwent transcatheter patent ductus arteriosus closure at the Stead Family Children's Hospital from 10/2019 to 10/2021 were retrospectively reviewed and analyzed. Twenty-four patients (41%) underwent transcatheter patent ductus arteriosus closure with anti-scatter grids, while 34 (59%) underwent the procedure without using anti-scatter grids. At the time of catheterization, the median age, corrected age, and weight were 4.3 weeks (3.4–6), 29 weeks (28.1–30.9), and 1200g (1000–1600), respectively. Total radiation exposures for the dose area product and air kerma were 2.73  $\mu\text{Gy}\cdot\text{m}^2$  (1.65–4.16), and 1.63 mGy (1.15–2.58), respectively. Radiation doses were higher in the group in whom the anti-scatter grids were utilized with dose area product of 3.33  $\mu\text{Gy}\cdot\text{m}^2$  (2.39–5.43) and air kerma of 2.27 mGy (1.41–3.06) versus 1.86  $\mu\text{Gy}\cdot\text{m}^2$  (1.46–3.60) and air kerma of 1.40 mGy (1.08–1.92). When radiation doses were adjusted to the radiation time, no difference in radiation exposure was noticed between the groups. **Conclusions:** Transcatheter patent ductus arteriosus closure in premature infants can be safely performed with minimal radiation exposure. In the authors' laboratory, the use of anti-scatter grids does not impact radiation exposure in premature infants.

### Introduction

Persistent ductus arteriosus is commonly encountered in preterm infants, with the prevalence being inversely proportional to the gestational age. Exposure to a haemodynamically significant patent ductus arteriosus exposes preterm infants to increased mortality and major morbidities, including necrotising enterocolitis, intraventricular haemorrhage, heart failure, chronic lung disease, and pulmonary hypertension.<sup>1–3</sup> Historically, the treatment options were drug-mediated or surgical closure. Although surgical ligation achieves definitive patent ductus arteriosus closure, it is invasive and is associated with short- and long-term side effects, including adverse neurodevelopmental outcomes, scoliosis, vocal cord paresis, and worsening chronic lung disease.<sup>4,5</sup> In the past, transcatheter patent ductus arteriosus closure was mostly reserved for larger children and adults.<sup>6</sup> Over the past decade, several reports of successful patent ductus arteriosus closure in premature infants have been published.<sup>7–12</sup> Recently, the experience with transcatheter patent ductus arteriosus closure has proliferated since the advent of the Amplatzer Piccolo Occluder (Abbott, Plymouth, MN), which is the first and only Food and Drug Administration approved device for use in premature infants weighing  $\geq 700$  g.<sup>13</sup>

One of the side effects of catheterisation remains ionising radiation exposure, which can be grouped into two main categories: tissue reactions and stochastic effects. The former is secondary to radiation-induced cell death or damage, such as skin ulceration and hair loss. Stochastic effects result from radiation-induced mutations; this can especially impact rapidly dividing cells. Paediatric patients have a relatively increased risk given their faster-dividing cells and longer expected life span following the exposure during which cancer can develop.<sup>14,15</sup>

Radiation exposure is commonly measured by air kerma, which indicates the radiation dose received by the skin and dose area product, which is the radiation indexed to the exposure area. Dose area product is commonly considered a surrogate for a patient's stochastic risk.<sup>16,17</sup> Although there is growing interest in utilising echocardiography for guidance during transcatheter patent ductus arteriosus closure, the procedure is still largely performed under fluoroscopic guidance, which exposes infants to radiation.<sup>18,19</sup> Radiation exposure in premature infants secondary to patent ductus arteriosus closure is poorly studied. Moreover, the effect of the anti-scatter grids (radiation filters) on radiation exposure has not been described in this age group.

The primary purpose of this study was to investigate whether the use of anti-scatter grids alters the level of radiation exposure to premature infants undergoing transcatheter patent ductus arteriosus closure.

## Materials and methods

This is a retrospective single tertiary centre study on neonatal ICU patients who underwent successful percutaneous patent ductus arteriosus closure at the Stead Family Children's Hospital from October 1, 2019, to October 31, 2021. This study was approved by the institutional review board at the University of Iowa. It was determined that informed consent was not needed to conduct this study.

The procedure was defined as successful when the patient left the catheterisation lab alive with a patent ductus arteriosus device in place. Patients with successful procedures were included in the analysis. Patients were excluded when the procedure was not attempted, unsuccessful, or when a major complication arose, such as cardiac perforation or device embolisation, as complication management usually prolongs the procedure and fluoroscopy times and increases radiation exposure.

### Patient selection

All premature infants with haemodynamically significant patent ductus arteriosus whose medical therapy failed or was contraindicated were referred for transcatheter patent ductus arteriosus device closure. The neonatal hemodynamic team determined the significance of the patent ductus arteriosus based on standardised echocardiographic criteria. Patent ductus arteriosus care before and after transcatheter closure and the criteria for transcatheter device closure at the University of Iowa were previously described.<sup>20</sup>

### Device placement

All procedures were performed using the Siemens Artis Zee Biplane fluoroscopy system (Siemens Healthcare AG, Erlangen, Germany).

After stabilising the patients on the catheterisation lab table with special attention to maintaining normal core body temperature, baseline transthoracic echocardiogram was performed in the catheterisation lab to confirm the presence of the patent ductus arteriosus and assess the flow in the aortic arch and the branch pulmonary arteries.

All cases were performed through a single 4-Fr venous access. The patent ductus arteriosus was crossed in antegrade fashion using a combination of a 4-Fr Angled Glide catheter (Terumo, Somerset, NJ) with a 0.035" Tiger wire (Abbott Cardiovascular,

Plymouth, MN) inserted in the femoral venous sheath. Angiogram was obtained in the patent ductus arteriosus to determine patent ductus arteriosus's dimensions and shape to aid device selection. Then, the appropriate delivery system was used to deploy the occluder device exclusively in the intraductal domain. While the device was still attached to the delivery cable, an angiogram through the delivery catheter and transthoracic echocardiogram were obtained to assess the adequacy of the device position, and flow pattern in the left pulmonary artery and the aorta. The device was released when a satisfactory positioning was confirmed, and a detailed transthoracic echocardiogram was obtained. The sheath was removed, and the patient returned to the neonatal ICU after achieving hemostasis.

Our catheterisation lab has adopted the following strategies to reduce radiation exposure to patients and staff while maintaining image quality. The aim is to perform the procedures safely with minimal radiation aligning with the "as low as reasonably achievable" (ALARA) radiation principle.<sup>14,15</sup>

1- The fluoroscopy machine was set up to deliver the low radiation dose by optimising fluoroscopy tube voltage and current settings.

2- A 7.5 frames/sec is utilised for fluoroscopy and cine modes. Of note, with our current low fluoroscopy tube voltage and current settings, using a lower frame rate would reduce the visualisation ability.

3- Excessive collimation (frame the image) is practised to show only the area of interest. Collimation significantly reduces radiation and helps counter the magnification's negative effect on radiation.

4- The frontal camera is utilised unless the lateral camera is superior to show a catheter course or angiogram.

5- Simultaneous use of frontal and lateral projections during catheter manipulation is avoided. Rather, one camera is used and the other one is intermittently utilised to confirm the catheter position and help adjust its direction.

6- Stepping on the pedal is avoided unless catheters/wires are manipulated or when angiograms are taken. One frame fluoroscopy image is sufficient to confirm the position of the endotracheal tube, catheter, etc.

7- Unnecessary body parts or equipment are removed from the field, especially metals, as they trigger the automatic exposure control to increase the intensity of the X-ray.

Before 01/2021, we kept the grids in place for all patients regardless the size. Then, we decided to remove the grids for patients under 20 kg, hoping to lower radiation exposure.<sup>14</sup>

## Outcomes

The primary outcome was radiation doses when the anti-scatter grids were and were not utilised. Secondary outcomes included procedure time, fluoroscopy time, and procedure success rate.

## Data collection

Basic demographic data were collected, including gestational age, corrected gestational age, birth weight, age at catheterisation, weight at catheterisation, and body surface area. The duration of the procedure and radiation data were collected from the intraoperative radiation exposure sheet. The use of anti-scatter grids, radiation exposure from the lateral and frontal cameras, and the total exposure doses were also collected.

**Table 1.** The table summarises procedure time and radiation times and doses (total and between groups). IQR = interquartile range. M–W = Mann–Whitney AK = air kerma. mGy = milliGray. DAP = dose area product.  $\mu\text{Gy}\cdot\text{m}^2$  = microGray meter squared

Parameter	Median (IQR)			M-W test
	Total (n = 58)	Group #1 Grid in (n = 24)	Group # 2 Grid out (n = 34)	p value
Procedure time (min)	31.5 (25.75–39)	38 (30–46)	28 (23–34.25)	<0.001
Total fluoroscopy + cine time (min)	4.3 (3.58–6.1)	5.25 (4.30–7.21)	3.9 (3.2–5.9)	0.006
Cine time only (sec)	17.6 (13.95–27.15)	24 (16.80–29.65)	15.9 (12.8–21.12)	0.002
Total frontal and lateral cameras AK radiation dose (mGy)	1.63 (1.15–2.58)	2.27 (1.41–3.06)	1.4 (1.08–1.92)	0.018
Total frontal camera AK radiation dose (mGy)	0.6 (0.4–0.9)	0.75 (0.6–0.98)	0.5 (0.38–0.7)	<0.001
Total lateral camera AK radiation dose (mGy)	1 (0.7–1.75)	1.35 (0.9–2.20)	0.95 (0.70–1.3)	0.103
Total frontal and lateral cameras DAP radiation dose ( $\mu\text{Gy}\cdot\text{m}^2$ )	2.73 (1.65–4.16)	3.33 (2.39–5.43)	1.86 (1.46–3.6)	0.008
Total frontal camera DAP radiation dose ( $\mu\text{Gy}\cdot\text{m}^2$ )	1.16 (0.7–1.16)	1.48 (1.14–1.94)	0.81 (0.61–1.37)	<0.001
Total lateral camera DAP radiation dose ( $\mu\text{Gy}\cdot\text{m}^2$ )	1.4 (0.91–2.79)	1.86 (1.08–3.39)	1.19 (0.87–2.31)	0.107
Frontal and lateral cameras AK radiation dose from cine only (mGy)	0.7 (0.5–1.13)	1 (0.58–1.4)	0.6 (0.48–0.8)	0.01
Frontal camera AK radiation dose from cine only (mGy)	0.3 (0.2–0.53)	0.5 (0.3–0.6)	0.25 (0.2–0.4)	0.08
Lateral camera AK radiation dose from cine only (mGy)	0.4 (0.3–0.7)	0.55 (0.40–0.88)	0.35 (0.28–0.4)	0.029
Frontal and lateral cameras DAP radiation dose from cine only ( $\mu\text{Gy}\cdot\text{m}^2$ )	1.26 (0.7–1.92)	1.58 (1.21–2.06)	0.81 (0.61–1.55)	0.006
Frontal camera DAP radiation dose from cine only ( $\mu\text{Gy}\cdot\text{m}^2$ )	0.56 (0.35–0.98)	0.88 (0.56–1.16)	0.35 (0.28–0.73)	<0.001
Lateral camera DAP radiation dose from cine only ( $\mu\text{Gy}\cdot\text{m}^2$ )	0.56 (0.35–0.96)	0.74 (0.46–1.08)	0.45 (0.28–0.71)	0.024
Total frontal and lateral cameras AK radiation dose indexed to the time (mGy/min)	0.35 (0.3–0.45)	0.37 (0.31–0.45)	0.34 (0.28–0.47)	0.625
Total frontal and lateral cameras DAP radiation dose indexed to the time ( $\mu\text{Gy}\cdot\text{m}^2/\text{min}$ )	0.52 (0.44–0.73)	0.62 (0.45–0.74)	0.47 (0.40–0.72)	0.106
Frontal and lateral cameras AK radiation dose from cine only indexed to the time (mGy/sec)	0.04 (0.03–0.05)	0.04 (0.03–0.06)	0.04 (0.03–0.05)	0.151
Frontal and lateral cameras DAP radiation dose from cine only indexed to the time ( $\mu\text{Gy}\cdot\text{m}^2/\text{sec}$ )	0.06 (0.04–0.09)	0.07 (0.05–0.09)	0.05 (0.04–0.08)	0.570

### Statistical analysis

Descriptive analyses were performed on the total population. The normality of the data was assessed using Shapiro–Wilk test. Non-normally distributed data were reported as a median and interquartile range. Patients were divided into two groups. Group # 1 is the group in whom the anti-scatter grids were utilised. Group # 2 included the patients who underwent patent ductus arteriosus closure without using anti-scatter grids (grids were removed before starting the procedure). Mann–Whitney test was used to compare the two groups with non-parametric data. To account for the difference in the fluoroscopy time as a confounding factor, radiation doses in the two groups were indexed to the radiation time. A “P” value of <0.05 was chosen to be the cut-off of significant differences between the groups.

## Results

### Demographics

Sixty-two premature patients were referred for transcatheter patent ductus arteriosus closure. The median gestational age and birth weight were 25.1 weeks (23.7–26.6) and 687 g (576–915), respectively. The median age, corrected age, and weight at the time of catheterisation were 4.3 weeks (3.4–6), 29 weeks (28.1–30.9), and 1200 g (1000–1600), respectively. Of the eligible patients,

twenty-four underwent transcatheter patent ductus arteriosus closure with the anti-scatter grids in place, and 34 underwent the procedure without using the anti-scatter grids. No difference between the groups was found in gestational age, birth weight, procedural age, procedural corrected age, procedural weight, and procedural body surface area.

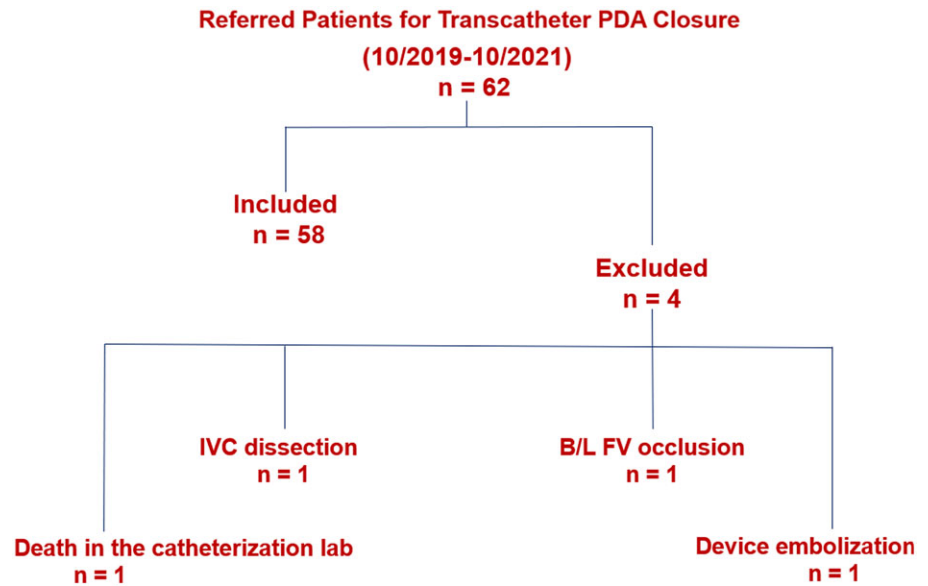
### Primary outcomes

The median total skin radiation dose and the total dose area product were 1.63 mGy (1.15–2.58) and  $2.73 \mu\text{Gy}\cdot\text{m}^2$  (1.65–4.16), respectively.

When comparing the total (cine and fluoroscopy) and from cine air kerma and dose area product radiation doses between the two groups, group # 1 was found to have significantly higher radiation doses from frontal, lateral, and both cameras. Likewise, group # 1 was found to have a higher fluoroscopy and cine times. No difference was noticed between the groups when radiation doses were adjusted to the time Table 1.

### Secondary outcomes

The procedure was successful in 58 (94%) patients in whom statistical analysis was performed. Four patients were excluded Figure 1.



**Figure 1.** Censor diagram summarises the excluded patients. PDA = patent ductus arteriosus. IVC = inferior vena cava. B/L FV = bilateral femoral vein.

Procedure time (the time from placing to removing the sheath) had a median of 31.5 minutes (25.8–39). Fluoroscopy time had a median of 4.3 minutes (3.6–6.1).

Most of the devices used were Piccolo devices in 56 patients (96.6%), with the KA micro plug (KA Medical, Minneapolis, MN) used in two patients (3.4%). Specifically, the devices included a 3/2 mm Piccolo in 26 patients (44.8%), a 4/2 mm Piccolo in 25 patients (43.1%), a 4/4 mm Piccolo in five patients (8.6%), a 5 mm KA micro plug-in one patient (1.7%), and a 3 mm KA micro plug-in one patient (1.7%).

Small residual shunt was observed in four patients (6.7%). Two patients were transferred back to their referring institutions within a few days after the procedure, with no available follow-up data. In one patient, the residual flow resolved within 1 month, while in the fourth patient, a tiny residual flow was still present at the 6-week follow-up.

New moderate tricuspid valve regurgitation was observed in one patient (1.7%), which improved to mild at a 3-week follow-up transthoracic echocardiogram. Another patient (1.7%) developed mild left pulmonary artery stenosis, with the peak gradient increasing from 16 mmHg at baseline to 25 mmHg after the procedure. At the 3-month follow-up, the left pulmonary artery stenosis resolved, with the peak gradient improving to 6 mmHg. None of the patients developed early or late iatrogenic coarctation of the aorta.

## Discussion

Historically, for premature infants with haemodynamically significant patent ductus arteriosus, surgical ligation was considered the standard of care for definitive patent ductus arteriosus closure when medical therapy failed or was contraindicated. Although transcatheter closure was sporadically attempted, it was often associated with complications, mainly attributed to the lack of appropriate devices for premature infant use. Recently, following the introduction of the Piccolo device, transcatheter closure has rapidly become the preferred definitive patent ductus arteriosus closure modality in many programmes, including ours.<sup>13,18–20</sup> Our institutional experience supports what has been

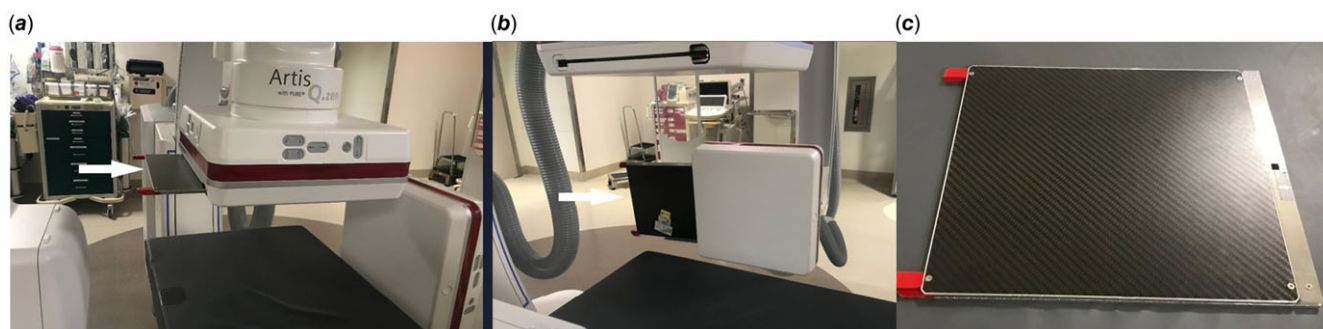
published in the literature that transcatheter patent ductus arteriosus closure is safe with a high success rate.<sup>13,18,19,21</sup>

To mitigate the risk of adverse events, avoiding unnecessary catheter manipulation is crucial, as maintaining short procedure time and reducing X-ray radiation exposure whenever possible.<sup>13</sup>

Increasing the kilovoltage peak of the fluoroscopy machine, commonly known as “tube voltage,” increases the penetrating power, in other words, the strength of the X-ray beam. Whereas increasing the “tube current” measured in milliamperes-seconds increases the number of the produced photons by the X-ray tube.<sup>15,22</sup>

As the X-ray photons pass through tissues, it has three fates. First, photons pass through the tissue reaching the image detector (X-ray receptor). Second, photons get entirely absorbed by the tissue. Third, photons that get deflected, which usually called “scatter.” Scatter is more significant in larger patients due to the thicker and denser tissues and more calcified bones. When more photons reach the receptor, a dark black colour will be formed on the receptor. On the contrary, as fewer photons hit the receptor, a white colour is created; that contrast forms the black-and-white picture we are familiar with. Scattered X-ray is like noise. It reduces the image quality and is a source of radiation exposure to catheterisation lab personnel and patients with no imaging benefits.<sup>15,22</sup>

The anti-scatter grid comprises alternating lead and relatively less radiation-absorbing materials like aluminium or carbon fibre and is removable from the catheterisation systems when needed (Figure 2). However, removing the grids is cumbersome and time-consuming in some catheterisation lab fluoroscopy models.<sup>15</sup> The anti-scatter grid is placed between the patient and the image detector. It improves the quality of the images by filtering the scattered radiation, thereby preventing the scatter rays from reaching the receptor. Nevertheless, as fewer photons reach the detector, image brightness decreases. The automatic exposure control of the fluoroscopy machine gets the feedback and is triggered to increase radiation to maintain image brightness at an acceptable range.<sup>17,23</sup> Anti-scatter grid is more beneficial in larger patients due to the significantly scattered rays. The substantial improvement in the image quality commonly justifies the increase



**Figure 2.** **A and B** show partial removal of the anti-scatter grids (white arrows) from the frontal (*a*) and lateral (*b*) camera image detectors (white arrow). **C.** Shows the anti-scatter grid is fully removed.

in radiation. Yet, in smaller children with less scattered rays, no meaningful improvement in image quality is expected by using anti-scatter grids. Increasing the radiation by keeping the anti-scatter grids in place is not justified by the theoretical improvement in the image quality.<sup>15,24,25</sup> Hence, removing the anti-scatter grids for small children with body weight less than 20 kg is recommended to fulfil the as low as reasonably achievable radiation principle.<sup>14,15</sup>

In the catheterisation lab, the operator can use two different radiation modalities. The most used one is “fluoroscopy mode,” which utilises much lower radiation but produces images with less quality. This mode is usually used to guide the manipulation of equipment (wires, catheters, etc.). The obtained images aren’t routinely stored but can be by hitting the store button when needed. The second mode is “cine mode.” This mode utilises much higher radiation exposure (approximately 15 times higher) but provides superior image quality, and the obtained images get routinely stored and can be replayed if needed. This mode is frequently utilised for angiograms or when fine details are needed to be visualised. The frequency (frame rate/second) of the pulsation in fluoroscopy and cine modes can be increased or decreased. A higher frame rate leads to sharper images but at the expense of higher radiation exposure.<sup>15</sup>

Due to the small heart size, aggressive image magnification is usually required during transcatheter patent ductus arteriosus closure. Although magnification provides better visualisation, it comes at the expense of increased radiation exposure. Moreover, due to the small patient size, the operator needs to stay close to the patient, which places the interventionalist at a greater risk of primary and scattered X-ray beam exposure. This risk is also aggravated because the hanging acrylic shield can’t be easily utilised due to the operator’s proximity to the patient’s chest. Limiting radiation exposure as much as possible protects not only the patients but also the operator and catheterisation lab staff.<sup>15,22</sup>

Since children are at a higher risk of developing cancers, it is crucial to focus on standardising radiation exposure based on the procedure and patient size, with an emphasis on reducing radiation.<sup>26,27</sup> However, this standardisation is still in its early stages, with only a few available reports. Additionally, because patent ductus arteriosus closure in premature infants is a relatively new procedure, there is currently no data on standard radiation doses. This study confirmed that patent ductus arteriosus closure in premature infants can be done with low doses of median dose area product  $2.73 \mu\text{Gy}\cdot\text{m}^2$  (1.65–4.16) and median air kerma 1.63 mGy (1.15–2.58). It is worth mentioning that radiation doses in this study are much lower (4.3–15.7 times less) than other

studies dealing with transcatheter patent ductus arteriosus closure in premature infants.<sup>8,19,21,28,29</sup> This is probably attributed to adopting the as low as reasonably achievable principle in our cardiac catheterisation lab and being diligent about the risk of radiation to the patients and the staff.

Infants born prematurely are likely at increased risk of developing cancers, such as acute myeloid leukaemia, hepatoblastoma, breast cancer in females, retinoblastoma, germ cell tumours, etc.<sup>30–33</sup> It remains unclear what exact radiation exposure level in preterm infants would increase their cancer risk. However, it has been demonstrated that children’s exposure to radiation during CT scans with cumulative doses of approximately 50 mGy can increase the risk of leukaemia with three folds, while doses exceeding 60 mGy can triple the risk of brain tumours.<sup>34</sup> Another study demonstrated an overall increased cancer risk of 24% in children and adolescents exposed to a CT scan at least one year before the cancer diagnosis. That risk is attributed to radiation exposure during that procedure.<sup>35</sup>

Cumulative radiation exposure in congenital cardiac patients can increase the cancer risk to 6.5% above the general population.<sup>36</sup> The lower the birth weight and gestational age, the greater the number of total X-ray studies done. Premature infants will likely need multiple exams during their neonatal ICU stay according to their underlying disease and associated comorbidities.<sup>37</sup> It is estimated that extremely low birth infants weighing less than 1000 gm require a median of 32 X-ray imaging studies during their neonatal ICU stay.<sup>38</sup> Moreover, with the fast-dividing cells and the longer expected survival, premature infants are at a relatively increased of developing cancer because of the stochastic effect of radiation exposure.<sup>14</sup> Therefore, minimising the additional radiation exposure during patent ductus arteriosus closure is crucial.

It is worth mentioning that the recommendation of removing the anti-scatter grids in infants weighing less than 20 kg was made in the era before widespread transcatheter patent ductus arteriosus closure in premature infants. Previously, cardiac catheterizations in premature infants were rarely performed, and no data are available on the effect of anti-scatter grids on radiation. In this study, radiation doses were higher in group # 1, which is the group that had the anti-scatter grids. However, this group also has longer procedure and radiation times. When adjusting radiation doses to the fluoroscopy and cine times, no difference was found among the groups in terms of radiation exposures. This is probably related to the near absence of scattered rays due to the soft non calcified bones and small chest thickness in premature babies. With minimal scattered X-rays, the grids don’t significantly absorb

radiation. Therefore, the automatic exposure control is not triggered to increase radiation. In our current catheterisation lab setting, we conclude that removing the grids doesn't significantly affect the level of radiation exposure. Our staff doesn't need to remove the grids before and put them back at the end of the procedure. This helps improve our workflow.

This study has a few limitations. First, this study is a retrospective, and a prospective randomised trial involving multiple centres would be better powered to answer this question. Second, as the patients in group # 1 were early in our experience, the procedure and radiation times were longer than in group # 2. This resulted in increased overall radiation exposure during our "learning curve." Third, the effect of anti-scatter grids on image quality was not studied. However, the operators report that they didn't notice a difference in image quality when the grids were removed. Fourth, the radiation doses and the effect of grids on radiation probably can't be generalised as it is specific to our current fluoroscopy tube settings. Until the effect of anti-scatter grids is specifically studied in other cardiac catheterisation laboratories, it is recommended to remove them for premature infants. Finally, the long-term ramifications of radiation exposure in extremely preterm babies represent a knowledge gap. Further studies are needed to verify the findings across different fluoroscopy machine vendors and tube settings.

## Conclusion

Transcatheter patent ductus arteriosus closure in premature infants is safe and feasible. It can be done with minimal radiation exposure when appropriate fluoroscopy machine settings are applied and the "as low as reasonably achievable" concept is practised. In the authors' laboratory, the anti-scatter grids do not affect radiation exposure in premature infants.

**Competing interests.** None.

**Ethical standards.** The authors assert that all procedures contributing to this work comply with the ethical standards of the relevant national guidelines on human experimentation and with the Helsinki Declaration of 1975, as revised in 2008, and has been approved by the institutional committees (the Institutional Review Board at the University of Iowa).

## References

- Noori S, McCoy M, Friedlich P, et al. Failure of ductus arteriosus closure is associated with increased mortality in preterm infants. *Pediatrics* 2009; 123: e138–144.
- Dollberg S, Lusky A, Reichman B. Patent ductus arteriosus, indomethacin and necrotizing enterocolitis in very low birth weight infants: a population-based study. *J Pediatr Gastroenterol Nutr* 2005; 40: 184–188.
- Gentle SJ, Travers CP, Clark M, Carlo WA, Ambalavanan N. Patent ductus arteriosus and development of bronchopulmonary dysplasia-associated pulmonary hypertension. *Am J Respir Crit Care Med* 2023; 207: 921–928.
- Koehne PS, Bein G, Alexi-Meskishvili V, Weng Y, Bühner C, Obladen M. Patent ductus arteriosus in very low birthweight infants: complications of pharmacological and surgical treatment. *J Perinat Med* 2001; 29: 327–334.
- Janz-Robinson EM, Badawi N, Walker K, Bajuk B, Abdel-Latif ME, Network NICU. Neurodevelopmental outcomes of premature infants treated for patent ductus arteriosus: A population-based cohort study. *J Pediatr* 2015; 167: 1025–1032.e1023.
- Backes CH, Kennedy KF, Locke M, et al. Transcatheter occlusion of the patent ductus arteriosus in 747 infants <6 kg: insights from the NCDR IMPACT registry. *JACC Cardiovasc Interv* 2017; 10: 1729–1737.
- Zahn EM, Nevin P, Simmons C, Garg R. A novel technique for transcatheter patent ductus arteriosus closure in extremely preterm infants using commercially available technology. *Catheter Cardiovasc Interv* 2015; 85: 240–248.
- Sathanandam S, Balduf K, Chilakala S, et al. Role of transcatheter patent ductus arteriosus closure in extremely low birth weight infants. *Catheter Cardiovasc Interv* 2019; 93: 89–96.
- Francis E, Singhi AK, Lakshminenkateshaiah S, Kumar RK. Transcatheter occlusion of patent ductus arteriosus in pre-term infants. *JACC Cardiovasc Interv* 2010; 3: 550–555.
- Zahn EM, Peck D, Phillips A, et al. Transcatheter closure of patent ductus arteriosus in extremely premature newborns: Early results and midterm follow-up. *JACC Cardiovasc Interv* 2016; 9: 2429–2437.
- Sathanandam S, Agrawal H, Chilakala S, et al. Can transcatheter PDA closure be performed in neonates ≤1000 grams? The Memphis experience. *Congenit Heart Dis* 2019; 14: 79–84.
- Bentham J, Meur S, Hudsmith L, Archer N, Wilson N. Echocardiographically guided catheter closure of arterial ducts in small preterm infants on the neonatal intensive care unit. *Catheter Cardiovasc Interv* 2011; 77: 409–415.
- Sathanandam SK, Gutfinger D, O'Brien L, et al. Amplatzer piccolo occluder clinical trial for percutaneous closure of the patent ductus arteriosus in patients ≥700 grams. *Catheter Cardiovasc Interv* 2020; 96: 1266–1276.
- Hill KD, Frush DP, Han BK, et al. Radiation safety in children with congenital and acquired heart disease: A scientific position statement on multimodality dose optimization from the image gently alliance. *JACC Cardiovasc Imaging* 2017; 10: 797–818.
- Justino H. The ALARA concept in pediatric cardiac catheterization: techniques and tactics for managing radiation dose. *Pediatr Radiol* 2006; 36: 146–153.
- The 2007 Recommendations of the International Commission on Radiological Protection. ICRP publication 103. *Ann ICRP* 2007; 37: 1–332. StatPearls. In., 2023. PMID: 18082557.
- Tapiovaara MJ, Sandborg M, Dance DR. A search for improved technique factors in paediatric fluoroscopy. *Phys Med Biol* 1999; 44: 537–559.
- Paudel G, Johnson JN, Philip R, et al. Echocardiographic versus angiographic measurement of the patent ductus arteriosus in extremely low birth weight infants and the utility of echo guidance for transcatheter closure. *J Am Soc Echocardiogr* 2021; 34: 1086–1094.
- Guyon P, Duster N, Katheria A, et al. Institutional trend in device selection for transcatheter PDA closure in premature infants. *Pediatr Cardiol* 2022; 43: 1716–1722.
- Shibbani K, Mohammad Nijres B, McLennan D, et al. Safety, and Short-term outcomes of transcatheter patent ductus arteriosus closure in premature infants on high-frequency jet ventilation. *J Am Heart Assoc* 2022; 11: e025343.
- Sathanandam S, Justino H, Waller BR, Radtke W, Qureshi AM. Initial clinical experience with the medtronic micro vascular plug™ in transcatheter occlusion of PDAs in extremely premature infants. *Catheter Cardiovasc Interv* 2017; 89: 1051–1058.
- Sy E, Samboju V, Mukhdomi T. X-ray Image Production Procedures. StatPearls. StatPearls Publishing, StatPearls Publishing LLC, Treasure Island (FL), 2023. PMID: 33232022.
- Brown PH, Thomas RD, Silberberg PJ, Johnson LM. Optimization of a fluoroscope to reduce radiation exposure in pediatric imaging. *Pediatr Radiol* 2000; 30: 229–235.
- Partridge J, McGahan G, Causton S, et al. Radiation dose reduction without compromise of image quality in cardiac angiography and intervention with the use of a flat panel detector without an antiscatter grid. *Heart* 2006; 92: 507–510.
- Chamberlain RC, Shindhelm AC, Wang C, Fleming GA, Hill KD. Estimating radiation exposure during paediatric cardiac catheterisation: a potential for radiation reduction with air gap technique. *Cardiol Young* 2019; 29: 1474–1480.
- Giannone A, De Monte F, Colangelo M, et al. Standardized diagnostic reference levels for paediatric interventional cardiology: data from an Italian referral centre. *Phys Med* 2024; 124: 104487.

27. "Radiation Protection N° 185. European guidelines on diagnostic Reference Levels fo Pediatric Imaging," 2018. [Online]. PMID: 39084137. Available at: [https://www.eurosafeimaging.org/wp/wp-content/uploads/2018/09/rp\\_185.pdf](https://www.eurosafeimaging.org/wp/wp-content/uploads/2018/09/rp_185.pdf).
28. Malekzadeh-Milani S, Akhavi A, Douchin S, et al. Percutaneous closure of patent ductus arteriosus in premature infants: a french national survey. *Catheter Cardiovasc Interv* 2020; 95: 71–77.
29. Nasef MA, Sullivan DO, Ng LY, et al. Use of the medtronic microvascular plug 7Q for transcatheter closure of large patent ductus arteriosus in infants weighing less than 2.5 kg. *Catheter Cardiovasc Interv* 2022; 99: 1545–1550.
30. Huang QT, Gao YF, Zhong M, Yu YH. Preterm birth and subsequent risk of acute childhood Leukemia: A meta-analysis of observational studies. *Cell Physiol Biochem* 2016; 39: 1229–1238.
31. Ekbom A, Erlandsson G, Hsieh C, Trichopoulos D, Adami HO, Cnattingius S. Risk of breast cancer in prematurely born women. *J Natl Cancer Inst* 2000; 92: 840–841.
32. Seppälä LK, Vettenranta K, Leinonen MK, Tommiska V, Madanat-Harjuoja LM. Preterm birth, neonatal therapies and the risk of childhood cancer. *Int J Cancer* 2021; 148: 2139–2147.
33. Paquette K, Coltin H, Boivin A, Amre D, Nuyt AM, Luu TM. Cancer risk in children and young adults born preterm: a systematic review and meta-analysis. *PLOS ONE* 2019; 14: e0210366.
34. Pearce MS, Salotti JA, Little MP, et al. Radiation exposure from CT scans in childhood and subsequent risk of leukaemia and brain tumours: a retrospective cohort study. *Lancet* 2012; 380: 499–505.
35. Mathews JD, Forsythe AV, Brady Z, et al. Cancer risk in 680,000 people exposed to computed tomography scans in childhood or adolescence: data linkage study of 11 million Australians. *BMJ* 2013; 346: f2360–f2360.
36. Johnson JN, Hornik CP, Li JS, et al. Cumulative radiation exposure and cancer risk estimation in children with heart disease. *Circulation* 2014; 130: 161–167.
37. Ono K, Akahane K, Aota T, et al. Neonatal doses from X ray examinations by birth weight in a neonatal intensive care unit. *Radiat Prot Dosimetry* 2003; 103: 155–162.
38. Iyer NP, Baumann A, Rzeszotarski MS, Ferguson RD, Mhanna MJ. Radiation exposure in extremely low birth weight infants during their neonatal intensive care unit stay. *World J Pediatr* 2013; 9: 175–178.