

Yuxi Jin<sup>1</sup>, Tiange Li<sup>1,2</sup>, Shaoying Wu<sup>3</sup>, Zhongqiang Liu<sup>1</sup> and Yifei Li<sup>1</sup>

## Brief Report

**Cite this article:** Jin Y, Li T, Wu S, Liu Z, and Li Y (2024) MFAP5 variant-induced multiple giant thoracic aortic aneurysm. *Cardiology in the Young* 34: 212–217. doi: [10.1017/S1047951123004122](https://doi.org/10.1017/S1047951123004122)

Received: 30 March 2023  
Revised: 1 July 2023  
Accepted: 4 November 2023  
First published online: 30 November 2023

**Keywords:**

Heritable thoracic aortic aneurysm; MFAP5; case report; whole-exome sequencing

**Corresponding authors:**

Z. Liu; Email: [liu\\_zh\\_qiang@163.com](mailto:liu_zh_qiang@163.com)  
and Y. Li; Email: [liyfwcsh@scu.edu.cn](mailto:liyfwcsh@scu.edu.cn)

The authors Yuxi Jin, Tiange Li and Shaoying Wu contributed equally to this article.

<sup>1</sup>Department of Pediatrics, Key Laboratory of Birth Defects and Related Diseases of Women and Children of MOE, West China Second University Hospital, Sichuan University, Chengdu, SC, China; <sup>2</sup>Department of Cardiovascular Surgery, West China Hospital, Sichuan University, Chengdu, SC, China and <sup>3</sup>Department of Pediatrics, The Second People's Hospital of Liangshan Yi Autonomous Prefecture, Xichang, SC, China

**Abstract**

Heritable thoracic aortic aneurysms are complex conditions characterised by the dilation or rupture of the thoracic aorta, often occurring as an autosomal-dominant disorder associated with life-threatening complications. In this case report, we present a de novo variant, MFAP5 c.236\_237insA (p.N79Kfs9), which is implicated in the development of inherited thoracic aortic aneurysm. The proband, a 15-year-old male, presented with recurrent cough, dull chest pain, chest distress, vomiting, and reduced activity tolerance, leading to the diagnosis of heritable thoracic aortic aneurysms. Whole-exome sequencing identified a novel heterozygous variant in MFAP5 (NM\_003480, c.236\_237insA, and p.N79Kfs9). MutationTester and PolyPhen-s predicted this variant to be damaging and disease-causing (probability = 1), while the SIFT score indicated protein damage (0.001). Structural analysis using the AlphaFold Protein structure database revealed that this mutation disrupted the N-linked glycosylation site, resulting in a frameshift, amino acid sequence alteration, and truncation of an essential protein site. To our knowledge, this is the first case report describing a young patient with heritable thoracic aortic aneurysm carrying the novel MFAP5 c.236\_237insA (p.N79Kfs\*9) variant. This variant represents the third identified mutation site associated with heritable thoracic aortic aneurysm. Given the high mortality and morbidity rates associated with thoracic aortic aneurysms, the prevention of severe and fatal complications is crucial in the clinical management of this condition. Our case highlights the importance of whole-exome sequencing and genetic screening in identifying potential pathogenic or likely pathogenic variants, particularly in early-onset patients with aortic dilation, to inform appropriate management strategies.

Thoracic aortic aneurysm is a grave cardiovascular disorder, with a prevalence estimated to range from 5 to 10 individuals per 100,000, as per the most recent American Heart Association guidelines on the management of aortic diseases. Despite its significant risk for adverse outcomes, approximately 95% of thoracic aortic aneurysms remain undetected until emergency situations arise, such as aortic rupture. Once diagnosed, immediate action should be taken to prevent severe complications. The extent of dilation in the thoracic aorta can be influenced by factors such as age, sex, weight, and body surface area. Aortic Z-scores and other diameter indexing methods may aid in risk assessment. The most commonly encountered types of thoracic aortic aneurysms involve the aortic root and ascending aorta. Aneurysms in the aortic root can result in severe aortic regurgitation, exacerbating heart failure, and producing diastolic murmurs. In young children, heart failure is often the initial presenting symptom. Hypertension, degenerative diseases, atherosclerosis, congenital disorders, prior aortic dissections, inflammatory aortitis, infectious aortitis, previous traumatic aortic injuries, and heritable genetic variants are recognised as underlying causes of thoracic aortic aneurysm.<sup>1</sup>

Heritable thoracic aortic aneurysms represent around 20% of the thoracic aortic aneurysm population, essentially multifactorial diseases.<sup>1</sup> However, it often presents an autosomal-dominant disorder with major life-threatening complications.<sup>2</sup> Genetic determinants are now understood to represent significant factors in risk for the individual patient. Aneurysms of the aortic root and ascending thoracic aorta tend to have a heritable influence and are present at younger ages. Two significant gene alterations are involved. The first involves genes associated with transforming growth factor beta, and the second is related to smooth muscle contractile aneurysms apparatus.<sup>3</sup> Previous studies have highlighted that syndromic heritable thoracic aortic aneurysms are commonly associated with genetic variants found in conditions such as Marfan syndrome (FBN1 variant), Loeys-Dietz syndrome (TGFBR1, TGFBR2, and SMAD3 variants), and other related syndromes involving genetic variants such as COL3A1, SLC2A10, FLNA, and ACTA2. Additionally, non-syndromic heritable thoracic aortic aneurysms have been associated with familial cases, with MYH11, PRKG1, and MAT2A identified in several instances. The advancement of sequencing techniques has facilitated the identification of more genetic

variants involved in heritable thoracic aortic aneurysms, contributing to a better understanding of the molecular mechanisms underlying thoracic aortic dilation and aneurysm formation. In this report, we present the third recorded familial case of a thoracic aortic aneurysm induced by a variant in the *MFAP5* (Microfibril-Associated Protein 5) gene, representing the first documented case in a child.<sup>4</sup> Furthermore, we provide a comprehensive summary of previously reported cases and their clinical manifestations, further expanding our knowledge of the relationship between *MFAP5* and thoracic aortic aneurysms.

## Case presentation

### Medical history and physical examination

The study received ethical approval from the Ethics Committee of the West China Second Hospital of Sichuan University (approval no. 2014-034). Written informed consent was obtained from the patient's parents prior to conducting whole-exome sequencing and including the patient's clinical and imaging details in publications.

The proband, a 15-year-old male, was admitted to our hospital with a history of recurrent cough, palpitations, chest distress, and vomiting persisting for more than 10 days. These symptoms appeared to worsen in recent days. The patient also experienced a significant reduction in activity tolerance and severe dull chest pain attacks. Walking a distance of only 100–200 m became challenging, and climbing stairs was impossible. Additionally, the patient experienced shortness of breath after mild activity. The nature of the chest pain was distinct from that of acute coronary artery syndrome, as it lacked qualities such as aching, tightness, and radiating discomfort. The patient also reported feeling exhausted with decreased food intake. There were no accompanying fever, syncope, or diarrhoea. The patient denied any history of cardiovascular diseases and rheumatic disorders, as well as any recent symptoms of viral or bacterial infections.

No surface wounds, particularly in the chest area, indicated the absence of accidental injuries. The patient had a breathing rate of 20–35 breaths per minute. Bilateral lung respiratory movements were symmetrical, with rough breath sounds and significantly apparent bilateral wet rales. The apex of the heart was displaced to the lower left, and a lift sensation was present in the precordial area. Severe cardiac enlargement was observed, accompanied by an extremely dull heart sound. Level I systolic and diastolic murmurs were audible at the aortic valve auscultation site. The abdomen was soft, the liver was palpable 3 cm below the subcostal margin and 1 cm below the xiphoid process, with a medium texture, and the spleen was not palpable below the subcostal margin. Muscle strength and tension in all four extremities were normal, and no pathological or meningeal irritation signs were observed.

Furthermore, the patient's parents denied any positive family history of cardiac events, cardiovascular diseases, hypertension, coronary artery diseases, diabetes, or obesity among their family members. No inherited diseases, including cardiomyopathies and metabolic disorders, were identified within the family.

### Imaging and laboratory examinations

Initial laboratory tests revealed a standard range of routine blood cell test and blood gas analysis. The C-reactive protein increased to 58.0 mg/L (n.v. < 8.0 mg/L). Besides, the results of hepatic and renal function yielded significant elevation of alanine aminotransferase (310 U/L, n.v. < 49 U/L) and raised aspartate aminotransferase (710 U/L, n.v. < 40 U/L). At the same time,

other parameters were primarily located in a normal range. Additionally, the significant elevation of serum cardiac troponin I (1.325 ug/L, n.v. < 0.06 ug/L) and B-type natriuretic peptide (20,276 pg/mL, n.v. < 146 pg/mL) had been identified.

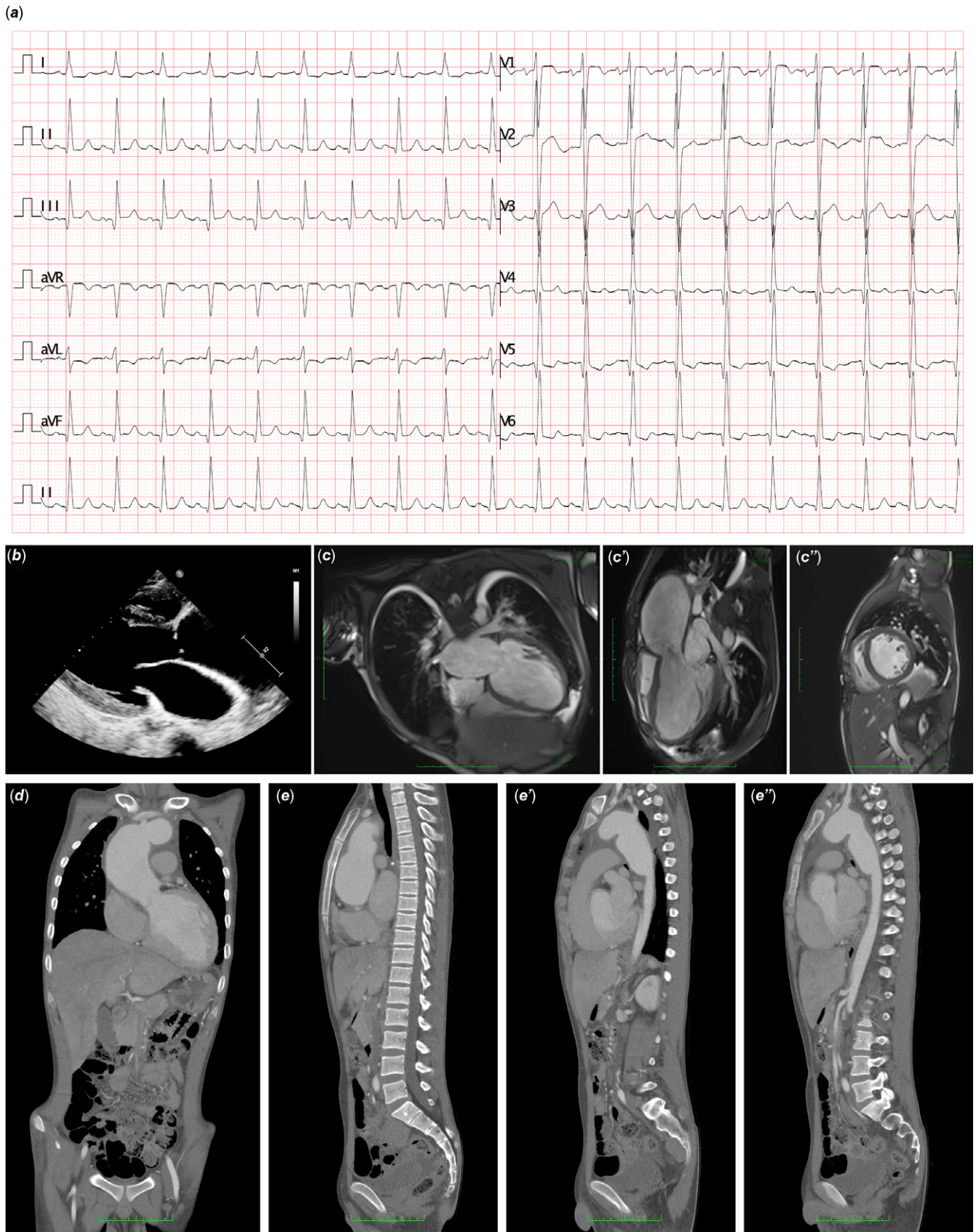
According to the history of illness, physical examination and initial laboratory tests strongly suggested cardiovascular system impairments. So, a series of examinations on the cardiovascular system was launched. Electrocardiography indicated abnormal left heart signalling with ST-T segment changes (lead V5–V6 ST depression > 0.05 mV, lead I, aVL depressed or inverted T waves) and prolonged QTc interval (Fig 1a). Interestingly, echocardiography demonstrated global severe heart enlargement (left ventricle = 62 mm, right ventricle = 22 mm, left atrium = 38 x 66 x 44 mm, and right atrium = 62 x 42 mm), decreased left ventricular ejection fraction (34–38%), severe multi-valve insufficiency (mitral valves, tricuspid valves, and aortic valves regurgitation), and a significant dilated aortic root (51 mm) (Fig 1b). Then the aortic CT angiography revealed multiple severe dilations of the aorta, including root, ascending, arch, and descending parts. Moreover, the most dilated segment was measured as 66.5 mm at the start of descending aorta (Fig 1d, e). Cardiac MRI presented heart enlargement and multiple aortic aneurysms. Besides, the delayed enhancement in the myocardium and subepicardial myocardial had been detected, indicating a disorder of myocardial perfusion (Fig 1c). To assess the clinical characteristics of the proband's parents, scanning of aortic CT angiography had been applied to them, and there was no positive results according to imaging measurement.

After that, the potential causes for multiple aortic dilations were systematically screened. The autoimmune antibodies were negative in this patient. While rheumatic analyses were also recorded as negative, the erythrocyte sedimentation rate elevated slightly. T-spots and Xpert were involved to exclude the potential infection of tuberculosis. Furthermore, a set of viral antigens or qPCR detecting viral DNA tests had been performed, and all the results were negative. Bacterial cultures of blood and sputum also failed to address an identical infected pathogen. So, the autoimmune-associated giant vasculitis and infection-related vascular injuries had been excluded and inherited, or genetic variant-induced thoracic aortic aneurysms were suspected.

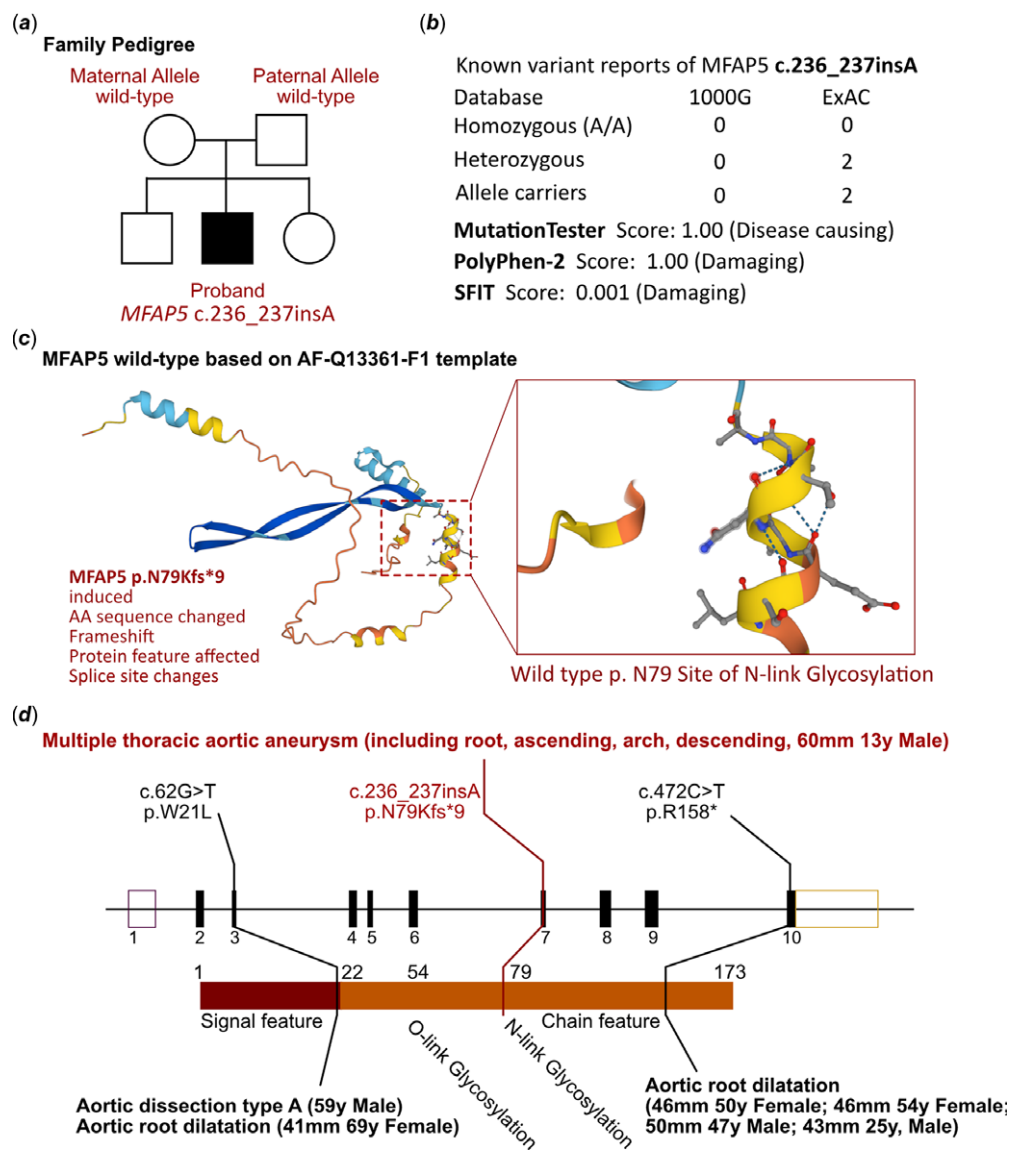
### Molecular results

Based on the clinical manifestations and laboratory analyses, a genetic disorder was strongly suspected. Whole-exome sequencing was performed using the above-mentioned protocol. Based on the molecular genetic screening, a novel heterozygous variant of *MFAP5* (NM\_003480, c.236\_237insA, p.N79Kfs\*9) was found. This was a de novo variant as his parents failed to identify the same variant site (Fig 2a). While this variant was only reported in large-scale population sequencing results, which had not elucidated the association between thoracic aortic aneurysms. Although there were two records which could be retrieved from ExAC database (Fig 2b), but this was first study to draw a link between *MFAP5* c.236\_237insA and thoracic aortic aneurysms. So that, we also considered this variant as a novel one in thoracic aortic aneurysms patients.

Additionally, any other cardiovascular-related variants had not been retrieved between this proband and his parents. The molecular crystal structure had been built in AlphaFold (AF-Q13361-F1, Fig 2c). And this proband would be the first identified patient with heterozygous variant change on c.236\_237insA of



**Figure 1.** Electrocardiography and radiology manifestation in the current proband. (a) Electrocardiography indicated abnormal left heart signalling with ST-T segment changes and prolonged QTc interval. (b) Echocardiography demonstrated global severe heart enlargement and a significant dilated aortic root. (c-c'') Cardiac MRI presented heart enlargement and multiple aortic aneurysms. (d-e) The aortic CT angiography revealed multiple severe dilations of the aorta, including root, ascending, arch, and descending parts. D panel presented coronal view and E panel presented sagittal views.



**Figure 2.** The *MFAP5* mutations in this family. **(a)** The proband exhibited a heterozygous variant of *MFAP5* (c.236\_237insA). **(b)** The variant of *MFAP5* c.236\_237insA has been predicted protein damaging by PolyPhen-2 and SFIT, while only two records had been retrieved of the *MFAP5* c.236\_237insA variant. **(c)** Protein structure predicted by AlphaFold (AF-Q13361-F1). This mutation site was regulated by N-link glycosylation modification, which induced frameshift, amino acid sequence changes, protein structure changes, and splice site changes. **(d)** All the reported patients with *MFAP5* variants have been presented.

*MFAP5*. This mutation site was regulated by N-link glycosylation modification, which induced frameshift, amino acid sequence changes, protein structure changes, and splice site changes. According to MutationTester analysis, the variant was considered as a disease-causing mutation, and the probability value was 1.00. And PolyPhen-2 analysis demonstrated a damaging change of this protein (1.00). While the SFIT score predicted protein damaging (0.001). We have summarised all the reported variant sites of *MFAP5* which was validated in thoracic aortic aneurysms. However, there were only two family with two different variants of *MFAP5* had been reported before (c.62G > T, p.W21L and c.472C > T, p.R158\*). Both of the reported patients with heritable thoracic aortic aneurysm were heterozygous variant carrier. The site of c.62G > T located in signal feature, while the site of c.472C > T located in chain feature. Differently, all the reported patients with *MFAP5* variant-induced thoracic aortic aneurysms were limited in aortic root segment, and the age of first time on proband identified was more than 45 years old (Fig 2d). There was no other potential variant had been identified to be related with cardiovascular diseases, especially for *FBN1* and *FBN2* of Marfan syndrome.

### Final diagnosis and treatment

Following a series of examinations and molecular tests, the child was diagnosed with heritable thoracic aortic aneurysm induced by the *MFAP5* variant. Upon admission to our hospital, the patient presented with severe heart failure caused by prolonged and significant aortic valvular regurgitation. Although the patient's parents declined artificial aortic replacement and valvar implantation, the primary therapeutic objective was to alleviate and improve the heart failure symptoms. During the hospitalisation, the patient received a combination of milrinone, dobutamine, spironolactone, furosemide, and enalapril to manage heart failure. Aspirin was administered for anticoagulation purposes, while prednisone acetate and methotrexate were prescribed for anti-inflammatory effects. Surgical correction was recommended as there are no established guidelines specifically tailored for children with heritable thoracic aortic aneurysm. Given the severity of the heart failure, the patient was initiated on Empagliflozin (10 mg daily) and Sacubitril Valsartan Sodium (100 mg twice a day) to enhance and maintain cardiac contractile function. Recently, the proband underwent thoracic aorta replacement surgery, followed

by cardiac rehabilitation to improve the overall prognosis. As a result, the patient has regained the ability to engage in mild activities, and his heart function has improved to NYHA III level.

## Discussion

Thoracic aortic aneurysms and thoracic aortic dissections can be classified into three main categories. Inherited syndromes account for less than 5% of all thoracic aortic aneurysm cases. Familial thoracic aortic aneurysm, which can be inherited from maternal or paternal alleles or arise as de novo variants, comprises approximately 20% of thoracic aortic aneurysm cases. The remaining three-quarters of thoracic aortic aneurysm patients do not exhibit genetic disorders or have a positive family history and are classified as “sporadic” cases.<sup>5</sup> Given the high mortality and morbidity rates associated with thoracic aortic aneurysms, preventing severe and fatal complications is crucial in clinical management. Non-syndromic or non-genetic thoracic aortic aneurysms may be caused by autoimmune or infectious diseases, typically requiring regular follow-up. However, heritable thoracic aortic aneurysms are often observed in the context of heart failure or aneurysm ruptures. Therefore, conducting whole-exome sequencing in thoracic aortic aneurysm patients is necessary, and genetic screening is recommended for all patients with aortic dilation in any segment to identify potential pathogenic or likely pathogenic variants.

*MFAP5* is a protein-coding gene encoding a 25-kD microfibril-associated glycoprotein MFAP5 which consists of 173 amino acids. As a component of microfibrils of the extracellular matrix, MFAP5 promotes the attachment of cells to microfibrils via alpha-V-beta-3 integrin. Also, MFAP5 has a conserved proprotein convertase cleavage site within this domain, making it a substrate for multiple proprotein convertase family members. The results of the current study showed the association between familial thoracic aortic aneurysm and MFAP5. Mechanically, MFAP5 has been identified to bind with several members of the TGF- $\beta$ /BMP superfamily, such as TGF- $\beta$ 1, TGF- $\beta$ 2, and BMP2, possibly through the acidic region of the N-terminus of the protein. MFAP5 loss-of-function results in thoracic aortic aneurysm, which has been considered to be related to impaired TGF- $\beta$ /BMP superfamily molecular signalling.<sup>6</sup> Second, MFAP5 is involved in fetal development as its expression can be detected in embryonic tissues and stem cells. Moreover, in the postnatal stage, it is expressed differently among tissues. It is highly expressed in nerve, tibia, adipose-subcutaneous, and uterus tissues. The cardiovascular system contributes to maintaining the homeostasis of atrioventricular node cells and matures cardiac or vascular fibroblasts. Collectively, the dysfunction of fibroblasts could lead to the malformation of aortic walls.<sup>6</sup> Third, MFAP5 may play a role in haematopoiesis by regulating growth factors participating in maintaining large vessel integrity.<sup>7</sup> As a component of the elastin-associated microfibrils, there are three Reactome pathways involved with MFAP5, including elastic fibre formation, extracellular matrix organisation, and affecting molecules associated with elastic fibres. Similarly, MFAP5 participates in the regulation of signal transduction and affects vascular integrity by such signalling pathways. Also, *MFAP5* knock-out mice presented misleading extracellular matrix modelling. Besides, studies showed that FAK/CREB/TNNC1 signalling pathways mediate the effect of MFAP5 on ovarian cancer cell motility and invasion potential. MFAP5 affects on permeability and motility of endothelial cells via cytoskeleton rearrangement.<sup>8</sup> Other studies show how MFAP5 promotes breast cancer and tongue carcinoma progression.<sup>9,10</sup> Accordingly, the experimental

results elucidate the convincing evidence between the MFAP5 variant and thoracic aortic aneurysm formation.

In this study, we present a novel de novo variant in *MFAP5* (c.236\_237insA, p.N79Kfs9) that leads to the development of thoracic aortic aneurysm. The duplication of a single base in *MFAP5* (c.236\_237insA, p.N79Kfs9) causes a frame shift, resulting in a truncated protein structure and impaired functionality. Both MutationTester and PolyPhen predict this variant to be damaging and disease-causing. Previous literature reports have described *MFAP5* variants associated with thoracic aortic aneurysm in two families, including a nonsense mutation (c.472C > T, p.R158\*) and a missense mutation (c.62G > T, p.W121L). Notably, all previously reported cases involved elderly adults, making our study the first to report a child patient with thoracic aortic aneurysm and an *MFAP5* variant. Comparatively, the variant identified in our case (c.236\_237insA) specifically impairs the N-link glycosylation site and results in a significant truncation of the protein. This distinction suggests that the *MFAP5* variant (c.236\_237insA) may contribute to a more severe manifestation of thoracic aortic aneurysm compared to other reported variants with potentially milder impacts on protein function.

## Conclusion

This case report presents the first documented instance of heritable thoracic aortic aneurysm in a young patient with a novel MFAP5 variant. The identified variant, c.236\_237insA, represents the third confirmed mutation site associated with heritable thoracic aortic aneurysm. It is noteworthy that this variant results in impairment of the modification site and the formation of a significantly truncated protein structure, which is likely to contribute to more severe clinical manifestations. The utilisation of whole-exome sequencing holds promise in establishing a hierarchical management strategy for patients with thoracic aortic aneurysms.

**Acknowledgements.** None.

**Data availability.** Datasets used in this study are available from the corresponding author upon reasonable request.

**Author contribution.** Jin Y, Li T, and Wu S contributed equally to this work. Jin Y, Lu G, and Li Y were the patient's physicians. Jin Y, Li T, and Wu S reviewed the literature and contributed to manuscript drafting. Jin Y and Wu S performed the mutation analysis. Liu Z and Li Y conceptualised and designed the study, coordinated and supervised the data collection, and critically reviewed the manuscript for important intellectual content. Li Y and Liu Z were responsible for the revision of the manuscript for important intellectual content. All authors issued final approval for the version to be submitted.

**Financial support.** This work was supported by grants from Technology Project of Sichuan Province of China (2021YFQ0061) and the National Natural Science Foundation of China (82270249). The funding did not participate in the design of the study and collection, analysis, and interpretation of data and in writing the manuscript.

**Competing interests.** None.

**Ethics approval.** This study was approved by the Ethics Committee of West China Second Hospital of Sichuan University (2014-034). For the participants who were under the age of 16 years, we obtained the written informed consent to participate in this research from all the reported seven patient's parents before performing exome sequencing and for the inclusion of the patient's clinical and imaging details in subsequent publications. And written informed consents were obtained from all the involved adults in this study.

**Consent.** For patients who are under the age of 16 years, written informed consent was obtained from the patient's parents for publication of this case report and any accompanying images. And we also obtained the written informed consent from adults involved in this study for publication of related clinical data. A copy of the written consent is available for review by the Editor of this journal.

## References

1. Jondeau G, Boileau C. Familial thoracic aortic aneurysms. *Curr Opin Cardiol* 2014; 29: 492–498.
2. Barbier M, Gross MS, Aubart M, et al. MFAP5 loss-of-function mutations underscore the involvement of matrix alteration in the pathogenesis of familial thoracic aortic aneurysms and dissections. *Am J Hum Genet* 2014; 95: 736–743.
3. Isselbacher EM, Lino Cardenas CL, Lindsay ME. Hereditary influence in thoracic aortic aneurysm and dissection. *Circulation* 2016; 133: 2516–2528.
4. Sencer EM, Misra S, Henkin S. Thoracic aortic aneurysm: a clinical review. *Cardiol Clin* 2021; 39: 505–515.
5. Hannuksela M, Stattin EL, Nyberg P, Carlberg B. [Familial thoracic aortic aneurysms and dissections can be divided into three different main categories]. *Lakartidningen* 2014; 111: 399–403.
6. Combs MD, Knutsen RH, Broekelmann TJ, et al. Microfibril-associated glycoprotein 2 (MAGP2) loss of function has pleiotropic effects in vivo. *J Biol Chem* 2013; 288: 28869–28880.
7. Gibson MA, Hatzinikolas G, Kumaratilake JS, et al. Further characterization of proteins associated with elastic fiber microfibrils including the molecular cloning of MAGP-2 (MP25). *J Biol Chem* 1996; 271: 1096–1103.
8. Leung CS, Yeung TL, Yip KP, et al. Calcium-dependent FAK/CREB/TNNC1 signalling mediates the effect of stromal MFAP5 on ovarian cancer metastatic potential. *Nat Commun* 2014; 5: 5092.
9. Wu Y, Wu P, Zhang Q, Chen W, Liu X, Zheng W. MFAP5 promotes basal-like breast cancer progression by activating the EMT program. *Cell Biosci* 2019; 9: 24.
10. Principe S, Mejia-Guerrero S, Ignatchenko V, et al. Proteomic analysis of cancer-associated fibroblasts reveals a paracrine role for MFAP5 in human oral tongue squamous cell carcinoma. *J Proteome Res* 2018; 17: 2045–2059.