

# A CASE OF SIMULTANEOUS INTERSTITIAL BILATERAL PREGNANCY

M. PEZZANI

Department of Obstetrics and Gynecology, General Hospital, Ceprano, Frosinone, Italy

---

*Twin pregnancies may present tubal involvement in the following cases: (1) simultaneous intra- and extrauterine pregnancy; (2) interstitial bilateral pregnancy (either simultaneous or not); (3) multiple pregnancy in the same tube; and (4) simultaneous interstitial and ovarian pregnancy.*

*Interstitial bilateral pregnancy appears to be by far the rarest kind of tubal twin pregnancy, apparently only one case having been reported in the literature, and this referring to a nonsimultaneous pregnancy. A case is now reported that therefore appears to represent the first observation of simultaneous interstitial bilateral pregnancy.*

---

Extrauterine pregnancy localized in the interstitial tract of the Fallopian tube is a rare event: the localization of two pregnancies involving the interstitial segment of the Fallopian tube in a contemporaneous and symmetrical manner is highly exceptional. According to Stewart (1950) the ratio between bilateral and unilateral ectopic pregnancies is 1 : 725, while that existing between bilateral contemporaneous tubal pregnancy and uterine pregnancy is evaluated at about 1 : 200,000.

According to McIlrath (1937) and Langley (1934) the seats of twin pregnancies involving the Fallopian tubes may be the following: (1) an ectopic pregnancy contemporaneous with a single intrauterine pregnancy; (2) an ectopic pregnancy contemporaneous with a twin intrauterine pregnancy; (3) bilateral tubal pregnancy (contemporaneous or not); (4) multiple pregnancy in the same Fallopian tube; (5) contemporaneous tubal and ovaric pregnancy.

According to the majority of authors, the rarest form of biovular twin pregnancy is bilateral ectopic pregnancy. Bilateral ectopic pregnancy may be contemporaneous or successive. The etiopathogenesis of bilateral ectopic pregnancy, in fact, raises a problem common to all multiple pregnancies, i.e., whether it is a phenomenon of superfetation (i.e., fertilization has taken place during a pregnancy already in course) or of superfertilization (i.e., fertilization of ovules either freed together or within a short space of time).

Ovulation during pregnancy as a cause of bilateral ectopic pregnancy can be admitted either on the basis of anatomic-pathological data (ovaries removed during pregnancy with dehiscent follicles) or on the basis of experimental data.

The possibilities appearing in the classification of bilateral ectopic pregnancies are the following: (a) two pregnancies of the same period or of different periods, both in evolution; (b) two pregnancies, one of which develops regularly while the other is interrupted.

The presence of pregnancies of different periods in each tube, or of corpus luteum with different stages of evolution in the two ovaries should not necessarily lead to the conclusion that the two pregnancies are not contemporaneous (Nicoletti 1939), as in one Fallopian tube the pregnancy might be interrupted for local reasons (hemorrhage in the intervillous spaces) while in the other it continues to develop (Bloch 1931).

From a review of the literature on the subject, there emerges that the most frequent occurrence is the noncontemporaneity of bilateral ectopic pregnancies; the only reported case of interstitial bilateral

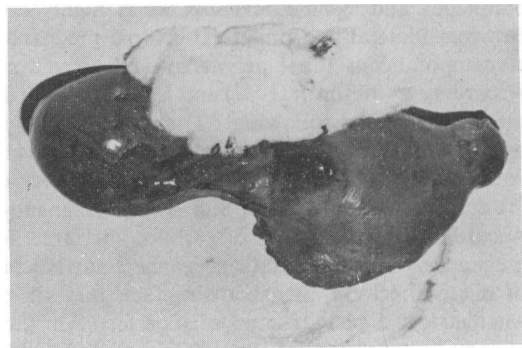
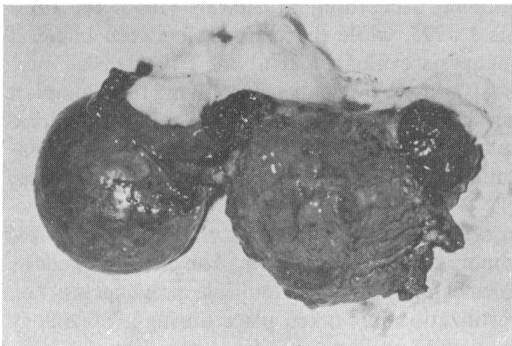
pregnancy is of this type; it was illustrated by Bergstrand et al. (1952); both the clinical background and the histological findings showed that it consisted of two pregnancies, developing at different periods (one exactly a year after the other); the woman was in fact operated on the occasion of the second pregnancy and histological examinations allowed a retrospective diagnosis to be made of the first pregnancy, which had not been diagnosed as such at its time.

The etiopathogenesis of bilateral ectopic pregnancy is the same as that of unilateral pregnancy. There are local or general causes, congenital or acquired causes (genital infantilism, malformations, inflammatory factors, endometriosis, etc.).

The case involved a woman of 38, Ipara, with regular menses ( $4-5 \times 35$ ) who after an involuntary 6-year period of sterility was hospitalized during the 8th week of pregnancy with the symptoms of a hemoperitoneum on 16-4-1970. She immediately underwent surgery and on opening the abdomen free blood was found in the cavity; the bottom of the uterus appeared deformed by two blackish smooth formations placed symmetrically at the two angles and continuing along the homolateral tubes. The sierosa showed fissures at some points and blood issued from the said fissures. The left-hand ovary was transformed into a dark coloured cyst the size of a tangerine. A subtotal hysterectomy was evedcted with left-hand annexotomy and right-hand salpingotomy.

The forward section of the uterine body effected in correspondence to the bottom and the two nodular formations allowed it to be observed that they were subject to hemorrhagic swelling with net margins towards the surrounding miometrial tissue and extending to the angles of the uterine cavity which however appeared to have been respected.

The histological examination of the interstitial tracts of the Fallopian tubes showed generally necrotic corial villus, corial elements of the syncytial type, deciduo-similar elements spread among muscular fibrocells disassociated from the hemorrhagic spread. Sections carried out on the isthmic and angular tracts of the two Fallopian tubes brought to light chronic inflammatory factors. The histological examination of the walls of the cysts showed they were luteinic cysts.



The rarity of true cases of interstitial pregnancy is due to the fact that when pregnancy has caused sufficient symptomatology to lead to surgery the egg has developed to a point going beyond the limits of the interstice; and this takes place very soon if we take into account the shortness of the interstitial tract of the Fallopian tube and the fast development of the blastocysts which should on the fifth day after fertilization already reach the uterine cavity and on the sixth/seventh day should establish themselves in the mucosa (Hertig et al. 1956); it is therefore inevitable that the structure next to the interstice-uterine angle or first tract of the isthmus-should be compromised. It must therefore be considered that many pregnancies diagnosed as angular or isthmic were originally interstitial.

With regard to the period of the two pregnancies it may be affirmed, after taking into account the possibility of overlapping the histological features found on both sides, that they were coeval pregnancies with contemporaneous breakage owing to the identical implantation seat.

With reference to the etiopathogenesis, the hypothesis may be put forward, on the basis of histological findings, and the sterility conditions the woman underwent for many years, that the inflammatory conditions in the Fallopian tubes conditioned the implantation of the two pregnancies in them.

## REFERENCES

- Bergstrand A., Englund A., Odeblad F. 1952. A case of bilateral interstitial pregnancy. *Acta Obstet. Gynecol. Scand.*, 32: 349-335.
- Bloch P. 1931. Sur un nouveau cas de grossesse tubaire bilaterale simultanée. *Rev. Franç. Gynecol. Obstet.*, 26: 538-541.
- Hertig A.T., Rock J.J., Adams E.C. 1956. A description of 34 human ova within the first 17 days of development. *Am. J. Anat.*, 98: 435-438.
- Langley G. 1934. Simultaneous bilateral tubal gestation. *Lancet*, 226: 571-572.
- McIlrath M.B. 1937. Bilateral tubal pregnancy. *Br. Med. J.*, 2: 1065-1066.
- Nicoletti G. 1939. Gravidanza tubarica bilaterale contemporanea. *Rass. Ost. Gin.*, 48: 23-26.
- Stewart H.L. 1950. Bilateral ectopic pregnancy. *West. J. Surg.*, 58: 648-651.