


Tahereh Saedi<sup>1</sup>, Rashide Siami<sup>2</sup>, Amir J. Ghaffari<sup>2</sup>, Danial Farmani<sup>2</sup> and Sedigheh Saedi<sup>3</sup> 

## Brief Report

**Cite this article:** Saedi T, Siami R, Ghaffari AJ, Farmani D, and Saedi S (2024) Aortic dilation in adults with repaired tetralogy of Fallot: a single-centre study. *Cardiology in the Young* **34**: 1128–1130. doi: [10.1017/S1047951124000143](https://doi.org/10.1017/S1047951124000143)

Received: 10 November 2023  
 Revised: 5 January 2024  
 Accepted: 6 January 2024  
 First published online: 27 February 2024

### Keywords:

Tetralogy of Fallot; surgery; aorta; aortic dissection; CHD

### Corresponding author:

S. Saedi; Email: [sedsaedi@gmail.com](mailto:sedsaedi@gmail.com)

<sup>1</sup>Iran University of Medical Sciences, Tehran, Iran; <sup>2</sup>Rajaei Cardiovascular Medical and Research Center, Iran University of Medical Sciences, Tehran, Iran and <sup>3</sup>Congenital Heart Disease Research Center, Rajaei Cardiovascular Medical and Research Center, Iran University of Medical Sciences, Tehran, Iran

## Abstract

**Background:** Tetralogy of Fallot is the most prevalent cyanotic CHD. With the advent of advanced surgical methods, the majority of tetralogy of Fallot patients reach adulthood. However, many need re-intervention for the residual anomalies including residual right ventricular outflow obstruction, pulmonary regurgitation, residual ventricular septal defects, and progressive aortic dilatation. Aortic dilation could lead to aortic regurgitation or dissection requiring surgical correction. In the current study, we aimed to determine the prevalence and outcomes of aortic root dilatation in adults with repaired tetralogy of Fallot in our tertiary care centre. **Methods:** In this retrospective study, 730 consecutive patients with history of repaired tetralogy of Fallot were included. Aortic diameter at the level of annulus, the sinus of Valsalva, sinotubular junction, and the ascending aorta as measured by echocardiography were evaluated. Prevalence of outcomes necessitating re-intervention including aortic regurgitation and dissection were recorded. **Results:** The mean size of annulus, sinus of Valsalva, sinotubular-junction, and ascending aorta in the latest available echocardiography of patients were 2.4±0.4 cm, 3.3±0.5 cm, 2.9±0.5cm, and 3.2±0.5cm, respectively. Prevalence of dilatation of sinus of Valsalva, dilation of Ascending aorta, sinotubular-junction, and aortic annulus was 28.7%, 21%, 8.3%, and 1 %, respectively. Five patients had severe aortic regurgitation (0.6%) and underwent surgical repair. One of these patients presented with acute aortic dissection. **Conclusion:** Aortic dilation is common in tetralogy of Fallot but prevalence of redo surgery for aortic dilation, regurgitation, and adverse events including acute dissection is low.

Tetralogy of Fallot is the most prevalent cyanotic CHD with a frequency of nearly 10% of all CHD.<sup>1,2</sup> Tetralogy of Fallot anomaly is comprised of ventricular septal defect, overriding of aorta, pulmonary and right ventricular outflow tract stenosis, and right ventricular hypertrophy. Surgical total correction of tetralogy of Fallot was first described by Lillehei et al in 1955 and consisted of relief of right ventricular outflow tract obstruction and closure of ventricular septal defect. Since then the surgical and management methods have remarkably progressed resulting in highly improved long-term survival. However; many patients suffer from residual defects including pulmonary regurgitation or right ventricular outflow tract obstruction requiring re-intervention in adulthood.<sup>3–6</sup> Aortopathy is also a known feature in tetralogy of Fallot. Aortic dilation is reported in a significant subset of patients and could lead to aortic valve malcoaptation and aortic regurgitation. Aortic dissection could occur but appears to be rare. The pathophysiology, extent, and late outcomes of aortopathy remain controversial in repaired and unrepaired tetralogy of Fallot patients.<sup>6–10</sup> In the current study, we sought to investigate the prevalence and outcomes of aortic dilatation in adults with repaired tetralogy of Fallot in our referral cardiovascular centre.

## Methods

In a retrospective study, 730 consecutive adult patients (≥18 years of age) with history of surgical repair of tetralogy of Fallot were evaluated. The study population's demographic data, including age, sex echocardiographic, and operative details were extracted from the patients' records. Patients with palliative surgery or no surgery and no available post-op and follow-up echocardiography data were excluded. Echocardiographic images were acquired using GE Vivid and Philips ultrasound machines. Aortic root dilatation was defined as greater than 37 mm or more than 2.5cm/m<sup>2</sup> in our study based on guideline of the American Society of Echocardiography.<sup>11</sup> Aortic root dimensions were measured in a parasternal long-axis view in systole and at the levels of the annulus of the aortic valve, the sinus of the Valsalva, the sinotubular junction, and the proximal ascending aorta.

**Table 1.** Prevalence of aortic regurgitation (AR) by echocardiography in patients with repaired tetralogy of Fallot.

Echocardiographic severity of AR	n (%)
No AR	302(41)
Trivial AR	80(11)
Mild AR	209(28.6)
Mild to moderate AR	92(12.6)
Moderate AR	38(5.2)
Moderate to severe AR	4(0.5)
Severe AR	5(0.6)

Severity of aortic regurgitation was assessed by the proximal regurgitation jet width in parasternal long-axis view and the presence of diastolic flow reversal in the aortic arch or descending aorta.

### Statistical analysis

Categorical variables were described as frequency (percentages) and compared between groups by Pearson's chi-square or Fisher's exact test for nominal and chi-square or trend test for ordinal variables. Numerical variables were assessed for normal distribution via one sample Kolmogorov-Smirnov test. They were described by median and compared between groups using Mann Whitney U or Kruskal Wallis test. P-values < 0.05 were considered statistically significant. Statistical analysis was performed using IBM SPSS Statistics 24 for Windows (IBM Inc., Armonk, NY, USA).

### Results

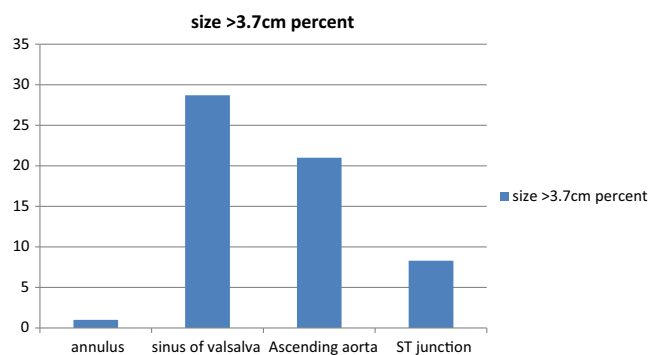
The study population consisted of 730 adult patients who had undergone total repair. Mean age of patients was 31+/-8 years. The median age at time of repair was between 4 and 8 years. The youngest participant was 18 and the eldest was 61 years old, respectively. Sixty-one per cent of patients were male. Mean left ventricular ejection fraction was 45+/-5%. The mean size of annulus, sinus of Valsalva, sinotubular-junction, and ascending aorta in the latest available echocardiography of patients were 2.4+/-0.4 cm, 3.3+/-0.5 cm, 2.9+/-0.5 cm, and 3.2+/-0.5 cm, respectively. Prevalence of dilatation of sinus of Valsalva, dilation of Ascending aorta, sinotubular-junction, and aortic annulus was 28.7, 21, 8.3, and 1 %, respectively.

Size of sinus of Valsalva was < 3.7 cm in 77.4%, between 3.7 and 4 cm in 11%, between 4 and 4.5 cm in 9.7%, between 4.5 and 5 cm in 1.5%, and > 5.5 cm in 0.4% of patients.

Eighty-three per cent of patients had ascending aorta size of < 3.7 cm, 10.3% between 3.7 and 4 cm, 6.4% between 4.5 and 5 cm, and 0.3%. > 5.5 cm. Severe aortic regurgitation was present in 0.7 %. No patient had sinotubular-junction or aortic annulus above 4.5 cm. Ten patients had sinotubular-junction measuring between 4 and 4.5 cm. (Fig. 1)

The rate of no aortic regurgitation was 41%, Trivial aortic regurgitation 11%, Mild aortic regurgitation 28.6%, Mild to moderate aortic regurgitation 12.6%, Moderate aortic regurgitation 5.2%, moderate to severe aortic regurgitation 0.5%, and severe aortic regurgitation 0.6 % (Table 1).

One patient had acute type A dissection of aorta and severe aortic regurgitation and underwent emergent surgery. The patient

**Figure 1.** Prevalence of aortic root dilation in repaired tetralogy of Fallot.

had aortic root size of 72 mm at the age of 24 years. Four other patients with severe aortic regurgitation all had concomitant severe pulmonary regurgitation and had aortic valve replacement during redo surgery for pulmonary valve replacement.

### Discussion

Our study showed that aortic dilation following repair of tetralogy of Fallot is common; however, adverse events including acute aortic dissection are not prevalent. Progression of aortic dilation is slow over the post-operative years and severe aortic regurgitation and dilation requiring redo surgery have a low rate of occurrence.

These findings are in accordance with the data from previous studies. Prevalence of aortic dilatation in tetralogy of Fallot has been reported over a wide range most probably due to differences in patient selection criteria. François-Pierre Mongeon et al in a study of 474 adults with repaired tetralogy of Fallot who were over 18 years of age reported nearly one third of adults had an aortic root diameter of  $\geq 40$  mm but the prevalence of significant aortic regurgitation was low.<sup>12</sup> Abd El Meguid et al in a multicentre observational study consisting of 100 repaired and unrepaired tetralogy of Fallot patients reported significant aortic root dilatation in 22% of patients in repaired tetralogy of Fallot and 70% of un-operated patients.<sup>13</sup>

Cruz et al evaluated the aorta in 78 patients with repaired tetralogy of Fallot by cardiovascular MRI. They described dilatation of ascending aorta as an observed-to-expected ratio of > 1.5 and reported a prevalence of 11.5%.<sup>7</sup> In another study of 126 corrected tetralogy of Fallot patients, Cruz et al reported dilatation of the sinus of Valsalva and ascending aorta in 29 and 24% of patients, respectively, as well as a higher aortic stiffness index.<sup>8</sup> Senzaki H et al showed in their study of 38 repaired tetralogy of Fallot patients that aortic pulse wave velocity and impedance were increased and aortic compliance was decreased in these patients. These abnormalities in aortic wall stiffness could contribute to increased diameter of aorta.<sup>14,15</sup> Schäfer M et al used 4D-flow MRI flow analysis to assess aortic flow in repaired tetralogy of Fallot patients and found that abnormal aortic flow persists even after total repair.<sup>16</sup>

Tan et al evaluated the aortic histology in 17 tetralogy of Fallot patients ranging from infants to adults and found a spectrum of histologic abnormalities including cystic medial necrosis, elastic lamellae fragmentation, and medio-necrosis. The changes are present from a very early age and could be responsible for progressive aortic dilation.<sup>17</sup> Chowdhury et al found lamellar

destruction and medial changes to be more noticeable in older patients.<sup>18</sup>

Other studies propose that severe right ventricular outflow tract obstruction in un-operated patients and resultant right to left shunting of blood through the ventricular septal defect could lead to left-sided volume overload and consequent aortic root dilation. Thus delayed total repair and pulmonary atresia might increase the rate of aortic root dilation. Bhat et al reported normalisation of aortic root dilation in those who were repaired in infancy whereas dilation persisted if correction was performed over one year of age.<sup>19</sup>

Katrien Francois et al performed a retrospective analysis of the aortic root dimensions in 88 patients with repaired tetralogy of Fallot at a mean age of  $9.7 \pm 7.4$  months. In their study, all patients had dilated aortic roots pre-operatively; however, indexed root diameter regressed over time with normalisation of size of the annulus and sinotubular junction within 7 years post-operatively.<sup>20</sup>

Total correction of tetralogy of Fallot is performed at a much younger age than before in recent years thus eliminating the overflow from right to left shunting. Future research could better delineate the role of earlier surgery on the course of the inherent aortopathy in these patients.

Our findings emphasise that adult patients with repaired and unrepaired tetralogy of Fallot need lifelong close clinical and imaging follow-up. Effective medical therapy to delay the aortic dilation is not well established. Many repaired tetralogy of Fallot patients require redo surgery for residual right ventricular outflow tract abnormalities, pulmonary regurgitation, and residual ventricular septal defect. Currently, aortic root dilatation exceeding 55 mm is considered as an indication for surgical repair but the threshold for concomitant repair of a dilated aorta below 55 mm in the subset undergoing pulmonary valve replacement is not defined.<sup>3,4,8,21</sup> Further research in this field and an individualised management strategy based on patient's underlying anatomy, comorbidities, and surgical risk is necessary.

## Conclusion

Aortic dilation and varying degrees of aortic regurgitation are prevalent in tetralogy of Fallot patients. The rate of progression of dilation, need for redo surgery, and occurrence of adverse outcomes seems to be low. Future studies encompassing patients that have been repaired at an earlier age could help delineate the natural history of aortopathy in this patient population.

## References

1. Moons P, Sluysmans T, De Wolf D, et al. Congenital heart disease in 111 225 births in Belgium: birth prevalence, treatment and survival in the 21st century. *Acta Paediatr* 2009; 98: 472–477.
2. Therrien J, Webb G. Clinical update on adults with congenital heart disease. *Lancet* 2003; 362: 1305–1313.
3. Baumgartner H. The task force on the management of grown-up congenital heart disease of the European society of cardiology (ESC): ESC guidelines for the management of grown-up congenital heart disease (new version 2010). *Eur Heart J* 2010; 31: 2915–2957.
4. Lui GK, Saidi A, Bhatt AB, et al. Diagnosis and management of noncardiac complications in adults with congenital heart disease: a scientific statement from the American heart association. *Circulation* 2017; 136: e348–e392.
5. Mueller AS, McDonald DM, Singh HS, Ginns JN. Heart failure in adult congenital heart disease: tetralogy of Fallot. *Heart Fail Rev* 2020; 25: 583–598.
6. van der Ven JPG, van den Bosch E, Bogers AJCC, Helbing WA. Current outcomes and treatment of tetralogy of Fallot. *F1000 Research* 2019; 8: F1000 Faculty Rev-1530. doi: [10.12688/f1000research.17174.1](https://doi.org/10.12688/f1000research.17174.1).
7. Cruz C, Pinho T, Madureira AJ, et al. Is it important to assess the ascending aorta after tetralogy of Fallot repair? *Rev Port Cardiol* 2018; 37: 773–779.
8. Niwa K, Siu SC, Webb GD, Gatzoulis MA. Progressive aortic root dilatation in adults late after repair of tetralogy of Fallot. *Circulation* 2002; 106: 1374–1378.
9. Cruz C, Pinho T, Ribeiro V, Dias CC, Cardoso JS, Maciel MJ. Aortic dilatation after tetralogy of Fallot repair: a ghost from the past or a problem in the future? *Rev Port Cardiol* 2018; 37: 549–557.
10. Dodds III GA, Warnes CA, Danielson GK. Aortic valve replacement after repair of pulmonary atresia and ventricular septal defect or tetralogy of fallot. *J Thorac Cardiovasc Surg* 1997; 113: 736–741.
11. Lang RM, Badano LP, Mor-Avi V, et al. Recommendations for cardiac chamber quantification by echocardiography in adults: an update from the American society of echocardiography and the European association of cardiovascular imaging. *J Am Soc Echocardiogr* 2015; 28: 1–39.e14.
12. Mongeon FP, Gurvitz MZ, Broberg CS, et al. Aortic root dilatation in adults with surgically repaired tetralogy of fallot: a multicenter cross-sectional study. *Circulation* 2013; 127: 172–179.
13. Abd El Meguid KR, Mahmoud HB, Mohammad MM. Predictors for dilated aorta in repaired and unrepaired tetralogy of Fallot. *World J Cardiovasc Dis* 2015; 5: 233–253.
14. Senzaki H, Iwamoto Y, Ishido H, et al. Arterial haemodynamics in patients after repair of tetralogy of Fallot: influence on left ventricular after load and aortic dilatation. *Heart* 2008; 94: 70–74.
15. Chong WY, Wong WH, Chiu CS, Cheung YF. Aortic root dilation and aortic elastic properties in children after repair of tetralogy of Fallot. *Am J Cardiol* 2006; 97: 905–909.
16. Schäfer M, Barker AJ, Jagers J, et al. Abnormal aortic flow conduction is associated with increased viscous energy loss in patients with repaired tetralogy of Fallot. *Eur J Cardio Thorac* 2020; 57: 588–595.
17. Tan JL, Davlouros PA, McCarthy KP, Gatzoulis MA, Ho SY. Intrinsic histological abnormalities of aortic root and ascending aorta in tetralogy of Fallot: evidence of causative mechanism for aortic dilatation and aortopathy. *Circulation* 2005; 112: 961–968.
18. Chowdhury UK, Mishra AK, Ray R, Kalaivani M, Reddy SM, Venugopal P. Histopathologic changes in ascending aorta and risk factors related to histopathologic conditions and aortic dilatation in patients with tetralogy of Fallot. *J Thorac Cardiovasc Surg* 2008; 135: 69–77.
19. Bhat AH, Smith CJ, Hawker RE. Late aortic root dilatation in tetralogy of Fallot may be prevented by early repair in infancy. *Pediatr Cardiol* 2004; 25: 654–659.
20. François K, Zaqout M, Bové T, et al. The fate of the aortic root after early repair of tetralogy of Fallot. *Eur J Cardio Thorac* 2010; 37: 1254–1258.
21. Warnes CA, Child JS. Aortic root dilatation after repair of tetralogy of Fallot: pathology from the past? *Circulation* 2002; 106: 1310–1311.