



# Penumbra Indigo<sup>®</sup> system to safely remove intracardiac thrombus in a 7-month-old infant with severe immunodeficiency disorder

## Brief Report

**Cite this article:** Haddad RN, Adel Hassan A, Al Soufi M, and Kasem M (2024) Penumbra Indigo<sup>®</sup> system to safely remove intracardiac thrombus in a 7-month-old infant with severe immunodeficiency disorder. *Cardiology in the Young* **34**: 2039–2041. doi: [10.1017/S104795112402599X](https://doi.org/10.1017/S104795112402599X)


Received: 2 November 2023  
Revised: 30 April 2024  
Accepted: 27 May 2024  
First published online: 28 October 2024

### Keywords:

Children; congenital heart disease; mechanical thrombectomy; transcatheter intervention; thrombosis

### Corresponding author:

Raymond N. Haddad;  
Email: [raymondhaddad@live.com](mailto:raymondhaddad@live.com)

Raymond N. Haddad<sup>1</sup> , Ahmed Adel Hassan<sup>2</sup>, Mahmoud Al Soufi<sup>2</sup> and Mohamed Kasem<sup>2</sup>

<sup>1</sup>Centre de Référence Malformations Cardiaques Congénitales Complexes—M3C, Assistance Publique—Hôpitaux de Paris, Hôpital Universitaire Necker-Enfants Malades, Paris, France and <sup>2</sup>Department of Pediatric Cardiology, Heart Centre of Excellence, Al Jalila Children's Speciality Hospital, Dubai, United Arab Emirates

### Abstract

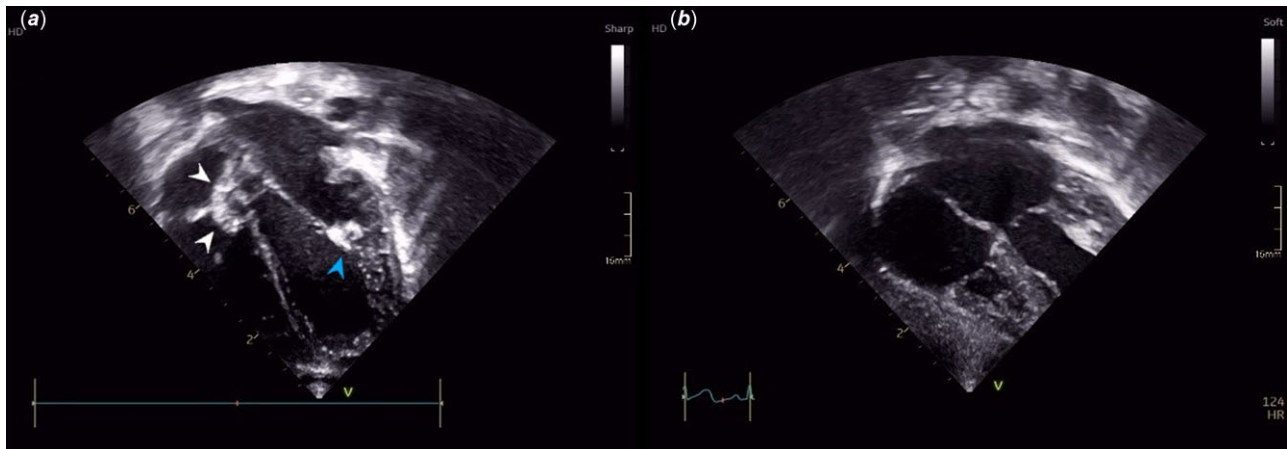
We report on a 7-month-old boy (4.2 kg/60 cm) with severe immunodeficiency disorder and bacterial septicaemia who was referred for an infected atrial thrombus secondary to a jugular central line. The echocardiogram showed a teardrop-shaped thrombus with a wide base adherent to the interatrial wall and a flimsy tail moving freely in the right atrium. Chest CT scan showed multiple lesions in both lungs consistent with infected micro-thrombi. The thrombus increased in size despite 2 weeks of antibiotics and anticoagulation. We applied the Indigo<sup>®</sup> Lightning<sup>®</sup> 7 aspiration system from Penumbra<sup>®</sup> (Alameda, USA) and removed percutaneously the thrombus under transoesophageal ultrasound and biplane fluoroscopic guidance. At 6 weeks of follow-up, the patient is alive, under enoxaparin with no procedure-related complication.

### Case presentation

We report on a 7-month-old boy (4.2 kg/60 cm) with severe primary immunodeficiency disorder who was referred for an infected atrial thrombus secondary to a jugular central line. The patient was diagnosed with leukocyte adhesion deficiency, had a history of recurrent bacterial infections with growth delay, and was listed for haematopoietic stem cell transplantation. He had a triple lumen right internal jugular vein line to receive intravenous antibiotics for *Klebsiella pneumoniae* septicaemia. The echocardiogram showed a thrombus located at the atrial septum starting from the superior caval vein down to the mid-part of the atrial septum. The thrombus was teardrop-shaped with a wide base adherent to the interatrial wall and a friable tail moving freely in the mid-right atrium and across the tricuspid valve (Figure 1a, Video 1, 2). He also had other smaller thrombus fixed to the mitral valve apparatus without mitral valve regurgitation or stenosis (Figure 1, Video 2). There was no intracardiac shunt or anomaly. The chest CT scan showed multiple lesions in both lungs and branch pulmonary arteries consistent with infected micro-embolic events and mycotic aneurysms.

We discussed the case during a multidisciplinary meeting and concluded that the atrial thrombus is showering infected embolic clots into the pulmonary circulation. The jugular catheter was then removed and the child received intravenous meropenem and amikacin combination therapy and a therapeutic dose of subcutaneous enoxaparin, which brought his inflammatory markers down without normalising. Two weeks later, the inflammatory markers were going up again, and ultrasound assessments showed that the thrombus size was increasing. A decision was made to remove the atrial thrombus percutaneously.

A 6-Fr right femoral access was obtained under fluoroscopic guidance to make sure the guiding wire was not crossing the upper part of the inferior caval vein. A 4-Fr multipurpose glide catheter and a J-tip 0.035-inch Terumo wire were navigated carefully into the superior caval vein. After parking a 0.035-inch Emerald PTFE Guidewire from Cordis, the glide catheter was exchanged with an 8.5-Fr Destino<sup>™</sup> Reach steerable guiding sheath from Biotronik. Under transoesophageal ultrasound and biplane fluoroscopy, the tip of the steerable sheath was deflected 75 degrees toward the interatrial septum. We advanced a 7-Fr 130 cm long Penumbra Lightning<sup>®</sup> 7 aspiration catheter (XTORQ Tip) through the right femoral vein, connected to the Lightning<sup>®</sup> aspiration tubing and the Penumbra ENGINE<sup>®</sup> (Figure 2). We exteriorised the tip of the catheter a few millimetres beyond the tip of the sheath. We confirmed the catheter position on transoesophageal ultrasound and used the manual on/off suction mode. The clot came out fragmented to the collector tank. The aspiration catheter was then moved caudally to sweep down the intra-atrial septum. Ultrasound showed that the clot was removed. 60 ml of blood loss was replaced during the procedure with cross-matched blood. No change in serum haemoglobin was noted. The procedure time was 15 minutes. The child was extubated on the table. The



**Figure 1.** (a) Modified four cavities subcostal ultrasound view showing the atrial thrombus adherent to the interatrial wall with a flimsy tail across the tricuspid valve (white arrow). Note the smaller thrombus fixed to the mitral valve apparatus (blue arrow). (b) Postoperative transthoracic ultrasound showing complete atrial thrombus removal.

thrombus was sent for culture and came back positive for *Klebsiella pneumoniae*. Next day, echocardiogram showed normal caval flow with an absence of effusion, tricuspid regurgitation, and residual thrombus (Figure 1b). The c-reactive protein levels came down from 220 mg/ml to 76 mg/ml after 3 days post-procedure. He was discharged from the hospital at 3 weeks postoperative after two negative blood cultures, a c-reactive protein at 15 mg/dl, and a negative procalcitonin. At 6 weeks of follow-up, the patient is alive, under enoxaparin with no procedure-related complication.

## Discussion

Antithrombotic treatment encompasses a range of interventions, including thrombolysis, pharmacologic anticoagulation, and thrombectomy (either catheter-based or surgical), which may be employed individually or in combination.<sup>1</sup> The more intensive treatment, the more likely the risk of bleeding increases. Thrombolytics have bleeding risks, particularly in small infants and vulnerable patients. In addition, the risk of intracranial and other major haemorrhage remains a main limiting factor to the use of thrombolytics in patients already on high-dose heparin.<sup>1</sup> Local thrombolytic therapy has been used successfully in some infants, but the experience is limited.<sup>1</sup> In this patient, we chose aspiration thrombectomy with Indigo because this novel device offers two key advantages. It does not require the use of thrombolytics and provides immediate thrombus removal. However, despite the favourable outcome, one could still argue for the merits of attempting thrombolytic therapy in this specific scenario, which involves infected and disseminated multiple lesions, besides the aspirated right atrial one. Furthermore, it is prudent to consider the composition and age of the thrombus, as these factors can influence the puncture-to-reperfusion time, the number of required manoeuvres, and ultimately, the associated clinical outcomes.<sup>2</sup> Larger real-world studies will provide a clearer understanding of the impact of thrombus characteristics in paediatric cases.

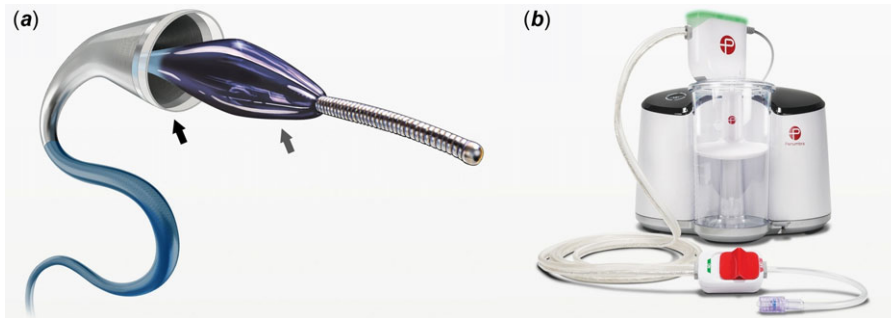
Mechanical thrombectomy catheters are extensively documented as both primary and adjunctive therapies for thrombus removal in adults and older children. Particularly, the Indigo device has been applied recently in adult-sized patients in the management of pulmonary embolism, peripheral arterial and venous thrombus, and coronary vessel occlusion.<sup>3–5</sup> However, data on the intracardiac use of this device in children is limited to one

case report. Soszyn N et al. from Children's Hospital Colorado described in January 2023 the case of a 53-day-old girl with central shunt thrombosis in the setting of pulmonary atresia where they successfully applied the Indigo aspiration system to remove the thrombus from her central shunt and left pulmonary artery facilitating stent placement in her narrowed left pulmonary artery.<sup>6</sup> Subsequently, the same team reported an extracardiac use of the Indigo aspiration system to remove a thrombus from the pericardial space of a 4-year-old boy with complex pericardial effusion associated with kaposiform lymphangiomatosis.<sup>7</sup> Herein, we report the second intracardiac use of the Indigo aspiration system in a small infant with safety and immediate efficacy.

In comparison to alternative mechanical thrombectomy systems like the AngioJet rheolytic, the Penumbra® Indigo system stands out as a sophisticated, computer-assisted device.<sup>8,9</sup> The built-in microprocessor features a proprietary thrombus removal algorithm that automatically controls the valve in the tubing to provide nearly pure continuous or intermittent aspiration (-29 inHg or 98.2 kPa) with intraprocedural audio-visual cues. This algorithm helps the operator quickly identify the thrombus location and detect patent flow to reduce potential blood loss. The device has three components: an aspiration catheter, a separator, and a pump. The separators are intended to mobilise the clot and clean the catheter lumen, therefore restoring flow for continuous aspiration (Figure 2).

In this patient, the use of the low-profile 7-Fr device effectively removed the atrial thrombus with minimal blood loss, vessel trauma, or cardiac injury. While the aspiration catheter boasts a soft atraumatic edge, excessive manipulation of the separator in distal anatomies or near intracardiac valves may result in vascular injury. Consequently, steerable guiding sheath, double fluoroscopic, and most importantly transoesophageal ultrasound guidance were essential to navigate the aspiration catheter with extra care and prevent it from going through the tricuspid valve or to the right atrial appendage.

Indigo continuous aspiration thrombectomy (CAT) catheters range in diameter from 3.4 to 12 Fr and lengths from 50 to 150 cm. However, Penumbra's Indigo aspiration system in the Middle East has been approved and introduced with Lightning® 7 and Lightning® 12, featuring CAT7 and CAT12 aspiration catheters, respectively. As of now, the utilisation of the Indigo aspiration system is confined to paediatric patients with a body weight suitable for a 7-Fr catheter.



**Figure 2.** Illustration of components of the Penumbra's Indigo Lightning peripheral mechanical thrombectomy system. (a) Lightning® 7 aspiration catheter (black arrow) and Separator™ 7 (grey arrow). (b) Penumbra ENGINE® aspiration source and Lightning aspiration tubing.

## Conclusion

The Penumbra Indigo aspiration system is a viable new tool in the armamentarium of paediatric cardiologists to safely remove intracardiac thrombus in children without increasing the systemic risk of bleeding.

**Supplementary material.** The supplementary material for this article can be found at <https://doi.org/10.1017/S104795112402599X>

**Financial support.** None.

**Competing interests.** None declared.

**Ethical standard.** The procedure contributing to this work is by the ethical standards laid down in the 1964 Declaration of Helsinki and its later amendments. We obtained written informed consent from the patient's parents to use and publish their clinical data.

## References

- Williams MD. Thrombolysis in children. *Br J Haematol* 2010; 148: 26–36. DOI: [10.1111/j2141](https://doi.org/10.1111/j2141).
- Shimizu H, Hatakeyama K, Saito K et al. Age and composition of the thrombus retrieved by mechanical thrombectomy from patients with acute ischemic stroke are associated with revascularization and clinical outcomes. *Thromb Res* 2022; 219: 60–69. DOI: [10.1016/j.thromres.2022.09.004](https://doi.org/10.1016/j.thromres.2022.09.004).
- Sista AK, Horowitz JM, Tapson VF et al. Indigo aspiration system for treatment of pulmonary embolism: results of the EXTRACT-PE trial. *JACC Cardiovasc Interv* 2021; 14: 319–329. DOI: [10.1016/j.jcin.2020.09.053](https://doi.org/10.1016/j.jcin.2020.09.053).
- Rossi M, Tipaldi MA, Tagliaferro FB et al. Aspiration thrombectomy with the Indigo system for acute lower limb ischemia: preliminary experience and analysis of parameters affecting the outcome. *Ann Vasc Surg* 2021; 76: 426–435. DOI: [10.1016/j.avsg.2021.04.016](https://doi.org/10.1016/j.avsg.2021.04.016).
- Mathews SJ, Parikh SA, Wu W et al. Sustained mechanical aspiration thrombectomy for high thrombus burden coronary vessel occlusion: the multicenter CHEETAH study. *Circ Cardiovasc Interv* 2023; 16: e012433. DOI: [10.1161/CIRCINTERVENTIONS.122](https://doi.org/10.1161/CIRCINTERVENTIONS.122).
- Soszyn N, Morgan GJ, Kim JS, Zablah JE. Case report: catheter-based mechanical thrombectomy using the Indigo aspiration system in a case of systemic-to-pulmonary shunt thrombosis. *Front Pediatr* 2023; 11: 1114044–1114044. DOI: [10.3389/fped.2023](https://doi.org/10.3389/fped.2023).
- Soszyn N, Leahy R, Morgan GJ. The novel use of an advanced thrombectomy system to manage a complex pericardial effusion associated with kaposiform lymphangiomatosis. *Cardiol Young* 2023; 33: 1–3. DOI: [10.1017/S104795112300032X](https://doi.org/10.1017/S104795112300032X).
- Qureshi AM, Petit CJ, Crystal MA, Liou A, Khan A, Justino H. Efficacy and safety of catheter-based rheolytic and aspiration thrombectomy in children. *Catheter Cardiovasc Interv* 2016; 87: 1273–1280. DOI: [10.1002/ccd.26399](https://doi.org/10.1002/ccd.26399).
- Yamada R, Adams J, Guimaraes M, Schönholz C. Advantages to Indigo mechanical thrombectomy for ALI: device and technique. *J Cardiovasc Surg (Torino)* 2015; 56: 393–400.