

## Main Article

Victoria Evans takes responsibility for the integrity of the content of the paper

Poster presentation (commended) at the British Academic Conference in Otolaryngology, 17 February 2023, Birmingham, UK.

**Cite this article:** Evans V, Prades E, Passant C, Owens D, Harris A. Stratifying risk of malignancy in cystic lateral neck lumps: a multivariate analysis of demographic, radiological and histological investigation factors and the development of a patient-centred risk-predictive tool for malignancy. *J Laryngol Otol* 2024;**138**:99–104. <https://doi.org/10.1017/S002221512300097X>

Received: 16 March 2023

Revised: 3 May 2023

Accepted: 13 May 2023

First published online: 23 May 2023

### Keywords:


Branchial cleft cyst; squamous cell carcinoma; malignancy; metastases; lymph node

### Corresponding author:

Victoria Evans;

Email: [evans.victoria.ann@gmail.com](mailto:evans.victoria.ann@gmail.com)

# Stratifying risk of malignancy in cystic lateral neck lumps: a multivariate analysis of demographic, radiological and histological investigation factors and the development of a patient-centred risk-predictive tool for malignancy

Victoria Evans<sup>1</sup> , Eduard Prades<sup>2</sup>, Carl Passant<sup>1</sup>, David Owens<sup>3</sup> and Andrew Harris<sup>1</sup>

<sup>1</sup>Department of Otolaryngology, Aneurin Bevan University Health Board, Newport, Wales, UK, <sup>2</sup>Department of Otolaryngology, Betsi Cadwaladr University Health Board, Rhyl, Wales, UK and <sup>3</sup>Department of Otolaryngology, Cardiff and Vale University Health Board, Cardiff, Wales, UK

## Abstract

**Background.** Management of lateral cystic neck masses with no apparent upper aerodigestive tract primary tumour in adults is controversial. Imaging modalities and fine needle aspiration cytology often struggle to distinguish the presence of malignancy.

**Method.** This study entailed a multicentre retrospective review of all patients with isolated lateral cystic neck masses from 2012 to 2018 in three Welsh health boards, utilising demographic data and first-line investigations (ultrasound scanning and fine needle aspiration cytology) to develop an evidence-based predictive tool for risk of malignancy.

**Results.** It was found that 29.1 per cent of cystic lesions were malignant on final histology. Age, male gender, non-benign ultrasound scan findings and fine needle aspiration cytology were significant risk factors on univariate analysis. The final multivariate analysis predicted a risk of malignancy ranging from 2.1 to 65.0 per cent depending on the covariate pattern. Smoking status was non-significant.

**Conclusion.** A rigorous, risk-stratified approach to the management of these patients should aid the clinician in minimising morbidity and optimising resources.

## Introduction

The investigation and subsequent management of lateral, non-thyroid, non-salivary, cystic neck masses is controversial and a source of contention for head and neck surgeons. Patients presenting with such a neck mass and no overt upper aerodigestive tract malignancy are most likely to have either a branchial cleft cyst anomaly or a necrotic squamous cell carcinoma (SCC) metastasis within a cervical lymph node.

The pathogenesis of branchial cleft cysts remains unproven. Several theories have been proposed and the most commonly accepted is that these are congenital anomalies originating from a failure of involution of one of the first four pharyngeal clefts (most commonly the second cleft). The majority of these benign lesions present in childhood, although a significant number may not be apparent until adulthood is reached. Clinical presentation is in the form of a cystic neck mass, typically felt at the anterior border of the sternocleidomastoid muscle and usually found in level II, in close proximity to the carotid sheath and the spinal accessory nerve.<sup>1</sup>

Squamous cell carcinomas represent the majority of head and neck cancers, developing from the mucosal epithelium lining the oral and nasal cavities, the pharynx and the larynx.<sup>2</sup> They are associated with a diverse range of risk factors, as defined by the International Agency for Research on Cancer (part of the World Health Organization).<sup>3</sup> These include tobacco and alcohol consumption, environmental pollution and infection with viruses, specifically human papillomavirus (HPV) and Epstein–Barr virus. Head and neck SCC has a predilection for regional metastasis to the cervical lymph nodes, which may be cystic or non-cystic, according to the lymphatic drainage pathways of the involved mucosal area, most commonly affecting levels II–III.<sup>4</sup> A subset of head and neck SCC presents in the first instance with a regional metastatic lymph node, with no primary index mucosal site. These subclinical primaries are often later found to originate from the oropharynx; indeed, the presence of cystic malignant metastases in level II is often considered to be the hallmark of HPV-related oropharyngeal SCC.<sup>5</sup>

Both ultrasound scanning and cross-sectional imaging such as computed tomography (CT) and magnetic resonance imaging (MRI) struggle to differentiate between these two very different diagnoses.<sup>6,7</sup> Additionally, fine needle aspiration cytology (FNAC) and core

biopsy often prove inadequate given the difficulty in obtaining a representative sample of the thin epithelial cyst wall, with a high likelihood of acellular or minimally cellular aspirate. If a representative sample is obtained, there can still be significant diagnostic challenges, as squamous cells in an inflamed branchial cleft cyst may show significant cytological atypia and nuclear hyperchromatism compatible with metastatic SCC, whilst well-differentiated metastatic SCC may be cytologically bland, suggestive of a branchial cleft cyst. As a result, the false-negative rate of FNAC in cystic neck lesions can be as high as 67 per cent.<sup>8</sup> Mass excision allows for definitive histology, but at the expense of tissue disruption and the potential seeding of malignant cells, especially if performed as a non-oncological resection.<sup>9</sup>

Investigation and management of these patients can vary greatly, even, in the authors' experience, within the same multidisciplinary team (MDT). In 2017, a clinical practice guideline was published for the 'evaluation of the neck mass in adults', but there is no clear guidance specifically for cystic masses, only that 'clinicians should continue evaluation of patients... until a diagnosis is obtained and should not assume that the mass is benign'.<sup>10</sup> Some surgeons would advocate a pre-operative positron emission tomography (PET)-CT, or a combination of panendoscopy, blind biopsies, tonsillectomy or mucosectomy either prior to or as part of a combined operation with excision. This may also be via a variety of approaches: as a simple excision (with or without a 'defensive incision'), with intra-operative frozen section, with the patient prepared to proceed to neck dissection, or as an oncological dissection to remove the cyst and clear associated lymph node levels.<sup>11-13</sup>

Inevitably, there is a risk that patients with true branchial cysts are over-investigated or undergo unnecessary diagnostic procedures; conversely, patients with metastatic SCC may have their pathway prolonged, or require additional treatment such as completion neck dissection or adjuvant non-surgical treatment. This may also lead to a subset of patients who receive triple modality treatment (surgery, chemotherapy and radiotherapy), which may have been avoided if a cancer diagnosis was made prior to cyst excision.

This diagnostic conundrum is becoming ever more pertinent with the increasing prevalence of patients presenting with cystic neck metastases secondary to HPV-related carcinoma of the oropharynx. There is a growing body of evidence to suggest that these patients may represent a different demographic subset compared with traditional head and neck malignancies; they are often younger, with a reduced or absent smoking and alcohol history.<sup>14</sup> The old adage that a young patient is more likely to have a benign cyst may be becoming increasingly false, but the evidence here is sparse, and age is still given much credence by some as a gauge of risk of malignancy.

This study therefore aimed to develop an evidence-based predictive tool for risk of malignancy in patients presenting with an isolated lateral cystic neck lump, following ultrasound scanning and FNAC, according to readily available patient demographics. Such a tool could be used to assist clinicians in the next diagnostic and therapeutic steps for these patients, including choice of imaging and surgery.

## Materials and methods

### Study design and setting

This was a multicentre retrospective review of all patients presenting with isolated lateral cystic neck masses, from 2012 to

2018 inclusive, in Wales. The centres involved were the Aneurin Bevan University Health Board (based at the Royal Gwent Hospital, Newport), Cardiff and Vale University Health Board (based at the University Hospital of Wales, Cardiff) and Betsi Cadwaladr University Health Board (based at Glan Clwyd Hospital, Rhyl). All centres routinely undertake head and neck surgical oncology.

Radiology databases were searched for ultrasound scan neck reports containing 'cyst, cystic, necrotic or branchial', and pathology databases were searched for reports containing 'neck + cyst, cystic, necrotic or branchial'.

### Data collected

Primary data were collected on patients' age, gender, smoking status, ultrasound scan report, FNAC outcome and final histological results or site-specific carcinoma-free follow up if the patient was managed conservatively.

Unlike in thyroid disease, no ultrasound scan staging system exists to differentiate between benign and malignant lateral neck lumps. Therefore, for the purpose of this paper, in order to allow statistical analysis, written ultrasound scan reports were categorised into 'strongly suggestive of benign', 'indeterminate' (unclear if benign or malignant) and 'strongly suggestive of malignancy'. All ultrasound scan reports were blinded and three otolaryngology surgeons were independently asked to categorise as above. Any discrepancies were then discussed and resolved. In order to validate this classification, an alpha Cronbach was applied (>0.75 was considered acceptable), with an alpha score of 0.91 generated.

The FNAC was scored as non-diagnostic (cytological grade C1), benign or most likely benign (C2 and C3), suspicious (C4), or malignant (C5). Malignant FNAC (cytological grade C5) was excluded from the study before full data collection in two out of the three centres, and after collection in one centre.

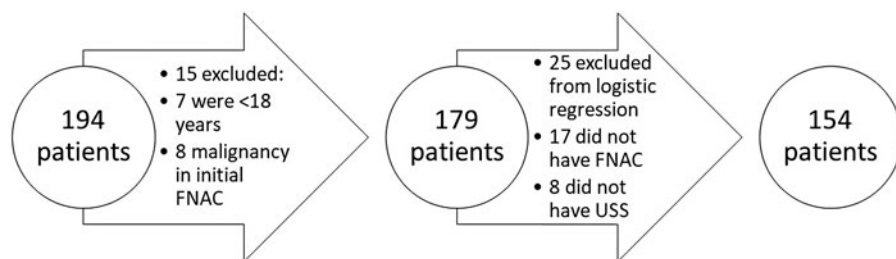
### Inclusion and exclusion criteria

Patients were required to be aged 18 years or older at the time of initial ultrasound scanning, and presenting with an isolated or dominant cystic or necrotic neck mass deep to platysma, in levels Ib, II or III, as these are the most common presenting sites for both branchial cleft cyst and metastatic upper aerodigestive tract SCC.<sup>15,16</sup> If more than one enlarged node was present, there had to be a clearly dominant necrotic or cystic mass, with other nodes at worst only borderline atypical and only mildly enlarged.

Cases were excluded if the mass was felt to arise from the thyroid or salivary glands, or was suggestive of a thyroglossal duct cyst. Cases were also excluded if there was an overt upper aerodigestive tract primary tumour on initial clinical examination, or a previous history of head and neck cancer or irradiation. Finally, patients were excluded if they had initial FNAC or core biopsy diagnostic of malignancy.

### Statistical analyses

Demographic data were described as means with 95 per cent confidence interval (CI) or proportions with 95 per cent CI. A double approach was performed to select the variable introduced into the logistic regressions: an initial researcher-guided parsimonious approach, followed by a subsequent selection of the best model from all possible equations using the lowest



**Figure 1.** Patient selection for logistic regression according to inclusion and exclusion criteria. FNAC = fine needle aspiration cytology; USS = ultrasound scan

Akaike information criterion and Bayesian information criterion scoring from Stata® statistical software version 15.0.

Interaction was checked using a chunk test, with  $p > 0.05$  considered non-significant. Outliers and collinearity were also assessed for the selected models. The Hosmer–Lemeshow test ( $p < 0.05$ ) was then applied.

**Ethical approval**

Ethical approval was not required for this project as it was retrospective. All data were collected by clinicians involved in caring for these patients and were anonymised before transfer to a central point (the lead author and statistician). This is in line with the National Health Service Health Research Authority guidance.<sup>17</sup>

**Results and analysis**

The initial search parameters yielded 194 suitable patients once the initial inclusion criteria were applied. Fifteen patients were subsequently excluded from all analyses: seven patients were less than 18 years of age at time of initial ultrasound scanning and eight patients demonstrated malignant cells on their initial FNAC. A further 25 patients were then excluded from logistic regressions, as 17 of these patients had only ultrasound scanning without FNAC results, and 8 of them had FNAC but not ultrasound scanning results (Figure 1).

Patient data were recorded with the following variables: age, gender, smoking status, ultrasound scan report, FNAC outcome and final histological result or site-specific carcinoma-free follow up if the patient was managed conservatively.

There were 97 males (54.2 per cent) and 82 females (45.8 per cent). The age ranged from 18 to 88 years, with a mean age for all patients of 49.0 years (95 per cent CI = 46.4–51.7). The mean age for males was 52.0 years and for females was 45.5 years. Sixty-three patients (35.2 per cent) were current smokers, 26 patients (14.5 per cent) were ex-smokers (with variable pack-year histories) and 88 patients (49.2 per cent) were never-smokers. Smoking status was unavailable for two patients.

Outcomes of ultrasound scan reports and FNAC are detailed in Table 1.

Of the 179 patients included, 52 had malignancy according to their final histology results (29.1 per cent). For the purpose of statistical analyses, conservatively managed patients with site-specific carcinoma-free follow up were included in the benign outcome group. Of these 38 patients, 17 had less than two years’ follow up, whilst 21 had more than two years follow up. Final outcomes are detailed in Table 2.

Additionally, expression of p16INK4A (p16 positivity), which is highly correlated with HPV-associated oropharyngeal SCC, was tested for in 43 of the 45 proven SCCs on final excisional histology. The results were positive for 34 patients and negative for 9 patients.

**Table 1.** Outcomes of initial USS and FNAC for lateral cervical cystic neck mass patients\*

Parameter	Cases (n (%))
USS report outcome <sup>†</sup>	
– Likely benign	66 (38.6)
– Indeterminate	77 (45.0)
– Likely malignant	28 (16.4)
FNAC outcome <sup>‡</sup>	
– Benign or likely benign	74 (45.7)
– Non-diagnostic	56 (34.6)
– Suspicious for malignancy	32 (19.8)

\*According to independent clinician-verified and validated scoring systems. <sup>†</sup>Total n = 171; <sup>‡</sup>total n = 162. USS = ultrasound scan; FNAC = fine needle aspiration cytology

**Table 2.** Final histology outcomes after lateral cervical cystic mass excision

Final histology	Cases (n)
Squamous cell carcinoma	45
Branchial cleft cyst	82
Conservative management*	38
Other benign disease	7
– Non-specific cyst	3
– Warthin tumour	2
– Dermoid cyst	1
– Neurofibroma	1
Other malignant disease	7
– Lymphoma	2
– Angiosarcoma	1
– Papillary carcinoma	1
– Melanoma	1
– Adenocarcinoma	1
– Non-small cell lung carcinoma	1

\*Conservative management refers to those patients who did not undergo diagnostic open biopsy and were instead observed for a time period prior to discharge.

**Odds ratio**

Independent variables for the 154 patients with complete data were assessed to consider the odds ratios for malignancy according to their presence. Age was categorically assessed by decade, with a cut-off point of 50 years utilised for significance. Gender, ultrasound scan report and FNAC outcome were assessed in a binary fashion. Odds ratios are detailed in Table 3. Smoking status was found to have a non-significant impact on risk of malignancy.

**Table 3.** Final odds ratios for independent variables that significantly impacted the malignancy risk for lateral cystic neck masses

Variable	Odds ratio (95% CI) for malignancy
Age >50 years	3.25 (1.32–7.99)
Female	0.43 (0.19–0.99)
USS report indeterminate or malignant (vs benign)	3.60 (1.22–10.66)
FNAC suspicious or inconclusive (vs benign)	3.10 (1.21–7.96)

CI = confidence interval; USS = ultrasound scan; FNAC = fine needle aspiration cytology

The adjusted prediction of risk of malignancy according to age and delineated via gender was also plotted as a linear graph, categorised by decade (Figure 2).

**Logistic regressions**

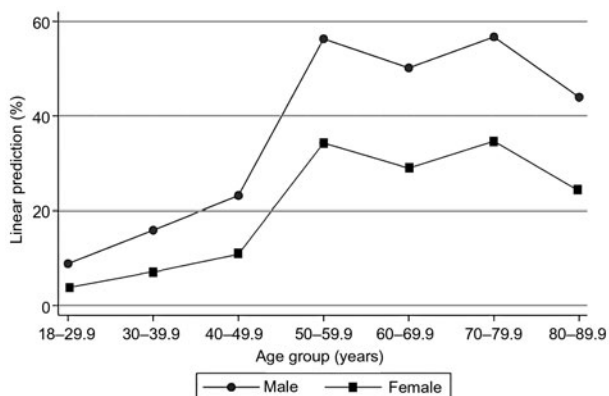
Multiple logistic regressions were developed to predict the probability of a binary outcome, benign versus malignant, using a combination of all the different statistically significant variables, with 16 possible covariate patterns. Interactions between variables for these models were non-significant ( $p > 0.05$ ). Akaike information criterion and Bayesian information criterion were used to determine which regression had the best fit for the data, and therefore would most accurately model the risk of malignancy. The selected model had Akaike information criterion of 148.9, Bayesian information criterion of 164.0, pseudo- $R^2$  of 0.2267 and an area under the curve of 0.81 (95 per cent CI = 0.74–0.88).

Sensitivity and specificity for this model were calculated at 45.45 per cent and 90.00 per cent, respectively. The calculated overall significance was  $p < 0.0001$ , whilst the goodness-of-fit Hosmer–Lemeshow test was not significant ( $p = 0.16$ ).

The outcomes of the selected logistic model for malignancy allow prediction of risk of malignancy for patients with the 16 possible different patterns of variables. The predicted risk of malignancy ranged from 2.1 to 65.0 per cent, as detailed in Table 4.

**Discussion**

Diagnostic uncertainty in adult patients presenting to the ENT out-patient clinic with an isolated cystic neck lump and no clinically obvious primary tumour remains a challenge. This seven-year multicentre retrospective analysis demonstrated



**Figure 2.** Adjusted prediction of risk of malignancy according to age category ( $n = 179$ ).

**Table 4.** Predicted malignancy risk according to logistic regression, utilising FNAC and USS outcomes

Age group	Gender	FNAC result	Predicted risk of malignancy (%)	
			USS benign finding	USS indeterminate or malignant finding
18–49.9 years	Female	Benign	2.1	7.3
		Inconclusive or suspicious	6.4	19.7
	Male	Benign	4.9	15.6
		Inconclusive or suspicious	13.7	36.4
>50 years	Female	Benign	6.7	20.4
		Inconclusive or suspicious	18.1	44.3
	Male	Benign	14.3	37.5
		Inconclusive or suspicious	34.0	65.0

FNAC = fine needle aspiration cytology; USS = ultrasound scan

the risk of malignancy in a large group of patients at their first follow-up appointment when a diagnosis of a lateral cystic neck mass has been made, but clinical examination and FNAC or core biopsy has failed to demonstrate a cancer. This study used sophisticated statistical analysis to provide a risk matrix to assist clinicians with a risk assessment tailored to each patient. It is hoped this tool will: aid decision-making with regard to the choice of investigation and surgical management, help to guide the urgency and therefore timing of those interventions, and be useful in justifying the plan to patients and in enabling a robust consenting process.

Previous studies have demonstrated an elevated risk of malignancy in patients of male gender and advancing age.<sup>8,18–25</sup> Until now, however, to the authors’ knowledge, there has not been a multivariate tool to calculate a tailored risk for an individual patient presenting to a clinician using only their demographic data, as well as their initial ultrasound scan and FNAC results.

Odds ratios for malignancy for independent variables mirror those of previous studies, with regard to smoking status (found to be non-significant), gender (with female sex being protective, odds ratio = 0.43, 95 per cent CI = 0.19–0.99) and advancing age (with risk increasing with each decade). Unlike previous studies, however, the most significant increase in risk of malignancy was found to occur in those aged over 50 years (odds ratio = 3.25, 95 per cent CI = 1.32–7.99), rather than the previously defined cut-off of 40 years, although risk did increase in a fairly linear fashion until the age of 50 years and thereafter remained consistently high.

It is noteworthy that logistic regression modelling restricted to age and gender was significantly less accurate than when the results of ultrasound scan and FNAC were also utilised. A non-benign (i.e. indeterminate/inconclusive or suspicious for malignancy) ultrasound scan or FNAC was associated with independent odds ratios for malignancy of 3.60 (95 per cent CI = 1.22–10.66) and 3.10 (95 per cent CI = 1.21–7.96), respectively.

It is the specific combination of these independent variables to model predicted risk that greatly increases their accuracy, ranging from a risk of malignancy of 2.1 per cent in a female

aged less than 50 years with entirely benign ultrasound scan and FNAC reports, to a risk of malignancy of 65.0 per cent in a male aged over 50 years with indeterminate or malignant ultrasound scan findings and inconclusive or suspicious FNAC. The value of this predictive model is demonstrated by its ability to predict an increased risk even in outliers. In this case series, the two youngest patients presenting with a lateral cystic neck mass that was subsequently histologically proven to be SCC were both female, aged 25 and 26 years, with final diagnoses of p16 positive ipsilateral tongue base and tonsillar SCC, respectively. Their ages are significantly lower than those of other case series published in the literature. Because of their young age and female gender, these patients could traditionally be categorised as low risk, but, in our predictive model, their ultrasound scan and FNAC results increase the risk of malignancy to 19.7 per cent for both.

### Development of risk-stratified treatment pathways

With an evidence-based risk prediction tool for these patients, it should be possible to produce a protocol with different pathways based on risk stratification. It is not the aim of this paper to propose such a protocol; it is for individual MDTs and the wider head and neck community to consider what level of risk warrants more invasive investigation. However, it is possible to discuss how such a protocol might be developed.

Current recommendations for the management of head and neck SCC utilise a cut-off of 15–20 per cent risk of occult nodal metastases to explore the clinical node-negative N<sub>0</sub> neck as per tumour–node–metastasis staging.<sup>26</sup> The authors do not propose the use of absolute percentage risk to determine investigation and treatment, but instead propose that certain thresholds of risk may trigger the consideration of more invasive investigation. Certainly, these data are useful to support patients' understanding of the next steps of their management pathway.

Whilst there is no consensus on the optimal steps with regard to imaging patients with lateral cervical cystic masses and an indolent primary site, a recent study by Jones *et al.* found that the addition of cross-sectional imaging via craniofacial MRI increased sensitivity from 25.00 per cent (ultrasound scanning and FNAC alone) to 40.75 per cent, increased the positive likelihood ratio from 3.22 to 3.49, reduced the negative likelihood ratio from 0.81 to 0.67 and did not significantly affect the accuracy (80.49 per cent, 95 per cent CI = 73.59–86.25).<sup>24</sup> With its growing availability, MRI use in the diagnostic pathway for SCC with an unknown primary tumour has significantly increased over time,<sup>27</sup> and indeed has recently been demonstrated to be of particular use in the detection of small oropharyngeal tumours with p16 positive nodal disease,<sup>28</sup> which represent a large proportion of this cohort. This, coupled with the lack of exposure to ionising radiation, makes craniofacial MRI a pertinent choice of next investigation in low-risk patients (5–15 per cent) before proceeding to cyst excision (with or without rigid endoscopic assessment of the upper aerodigestive tract). In those patients considered to be at very low risk of malignancy (<5 per cent), simple cyst excision alone may be appropriate.

In patients with a higher risk of malignancy, it may be prudent to follow the pathway for head and neck SCC with an unknown primary tumour, which may involve multimodal imaging including neck CT, craniofacial MRI and PET-CT, as well as panendoscopy with or without tonsillectomy and/or mucosectomy, and MDT discussion prior to excision of the mass as an oncological procedure.

It is essential to note that the recommendations based on the risk of malignancy in these patients are for guidance only, and should assist, rather than dictate, the clinician–patient partnership in deciding the next steps of management.

### Limitations

There are several limitations to the scope of this paper. Data were collected retrospectively, leading to inherent bias. Whilst we used broad search parameters for both radiology and pathology databases, there is a risk that some potential patients were missed from the study. This will not, however, have reduced the validity of the data collected. Patients were not excluded from the study if their final histology was different from SCC or branchial cleft cyst; they were instead separated into benign and malignant groups, and their data combined with branchial cleft cyst if benign and SCC if malignant (note that the risk prediction tool is not specific for branchial cleft cyst *vs* SCC, rather benign *vs* malignant). The numbers of non-branchial cleft cyst benign patients and non-SCC malignant patients with final histology were relatively low and reflect the range of potential pathologies that may be found in cystic neck lumps. We attempted to reduce these numbers with strict exclusion criteria, including any midline structures or any indication that cysts might be felt to arise from salivary or thyroid structures. Perhaps more significant is the inclusion of patients who were conservatively managed into the benign group. As these data were retrospectively collected, no specific follow-up criteria were utilised, leading to variabilities in the length of time for which patients were monitored and the method of monitoring (clinical *vs* imaging). Several patients were followed up for less than two years, whereas standard clinical follow up for patients with proven head and neck cancer is typically standardised at five years. It is therefore possible that some of these patients may have been harbouring a slow-growing malignancy, although it would be unusual for cystic metastatic SCC to remain clinically stable for any significant period.

Another inherent limitation to this paper is the use of pathology and radiology reports to generate predictions of risk of malignancy, as both are subjective analyses. As data were collected retrospectively, pathologists were not given a specific set of guidelines as to how to word their reports; instead, they were grouped into 'benign or likely benign', 'non-diagnostic', 'suspicious for malignancy' and 'malignant' (with malignant reports excluded). Reports were generated by a range of individual pathologists, from all three health boards, and not cross-examined. This degree of subjectivity in reporting mirrors real-world events, and we attempted to mitigate for it by using broad categories for analysis.

Similarly, there are inherent biases in radiology outcomes (which again are present in real-world reporting), as these are intrinsically subjective. In order to categorise radiology reports (and attempt to mitigate bias), we asked three independent ENT surgeons to assess each report, blinded for both the report request and the final patient outcome (benign *vs* malignant). Where more than two otolaryngologists disagreed with the outcome, the report was discussed and the outcome resolved. Alpha Cronbach was applied (>0.75 considered acceptable), with an alpha score of 0.91 generated, showing a high degree of inter-assessor concordance. This approach is very similar to that utilised in the MDT, where any patients with obviously benign or malignant radiology findings seen in

clinic typically have the next stages of investigation initiated by an independent clinician prior to MDT discussion with all information. Patients with uncertainty as to the significance of imaging results typically have these findings discussed at the MDT meeting to determine the next phase of investigation or management. Our approach therefore again mirrors real-world events.

Another limitation of this study is the requirement of age categorisation to generate statistical analyses. This means, for example, that a 49-year-old will be assigned to a different risk category than a 50-year-old, despite the fact that they may only be 1 day apart in age. We did not have a large enough dataset to subcategorise age into smaller groups for risk assessment, although it was clear that risk of malignancy did increase relatively linearly with increasing age. This is one of the reasons why the risk assessment tool and odds ratio generated must be interpreted as intended, for guidance only, rather than replacing overall clinical judgement.

- Investigation and management of cystic lateral cervical masses with no overt upper aerodigestive tract primary tumour is controversial, with no accepted clear guidelines
- Conventional imaging modalities and fine needle aspiration cytology (FNAC) can struggle to differentiate metastatic squamous cell carcinoma from benign branchial cleft cysts
- The literature describes a significantly increased malignancy risk in patients aged over 40 years, particularly in males
- Our seven-year retrospective analysis concurs with increased risk with advancing age and male gender
- The analysis also provides a risk matrix for each patient with a cystic lateral neck mass without proven malignancy following clinical examination, ultrasound scanning and FNAC
- The findings can assist clinicians in decision-making with regard to investigation and management, and in explanation of these to patients

Going forwards, we propose the validation of this risk assessment tool by the prospective collection of data across all Welsh health boards, via the Welsh ENT Research Collaborative, for all patients presenting to ENT out-patient clinics with a lateral cystic neck lump and no clinically apparent primary tumour.

## Conclusion

The most common cause of a lateral cervical cystic mass in adults remains a branchial cleft cyst. However, a significant proportion of these cases may be malignant (29.1 per cent in our total cohort). The likelihood of malignancy is statistically significantly greater in patients of increasing age, who are male and who have non-benign ultrasound scan or FNAC reports, and is unchanged by smoking status. A rigorous, risk-stratified approach to the investigation and management of these patients should aid the clinician in minimising morbidity and optimising resources, whilst also assisting in the explanation and discussion of the risks and benefits of management with the patient. A prospective study validating the use of this risk assessment tool would be a worthwhile avenue for further research.

## References

- 1 Coste AH, Lofgren DH, Shermetaro C. *Branchial Cleft Cyst*. Treasure Island, FL: StatPearls Publishing, 2023
- 2 Johnson DE, Burtness B, Leemans CR, Wai Yan Lui V, Bauman JE, Grandis JR. Head and neck squamous cell carcinoma. *Nat Rev Dis Primers* 2020;**6**:92

- 3 International Agency for Research on Cancer. List of classifications by cancer sites with sufficient or limited evidence in humans, Volumes 1 to 127. IARC Monographs on the Identification of Carcinogenic Hazards to Humans. In: <https://monographs.iarc.fr/agents-classified-by-the-iarc> [9 September 2023]
- 4 Mackenzie K, Watson M, Jankowska P, Bhide S, Simo R. Investigation and management of the unknown primary with metastatic neck disease: United Kingdom National Multidisciplinary Guidelines. *J Laryngol Otol* 2016;**130**: S170–5
- 5 Strojan P, Ferlito A, Medina JE, Woolgar JA, Rinaldo A, Robbins KT *et al.* Contemporary management of lymph node metastases from an unknown primary to the neck: I. A review of diagnostic approaches. *Head Neck* 2013;**35**:123–32
- 6 Goyal N, Thomas Zacharia T, Goldenberg D. Differentiation of branchial cleft cysts and malignant cystic adenopathy of pharyngeal origin. *AJR Am J Roentgenol* 2012;**199**:W216–21
- 7 Mittal MK, Malik A, Sureka B, Thukral BB. Cystic masses of the neck: a pictorial review. *Indian J Radiol Imaging* 2012;**22**:334–43
- 8 Gourin CG, Johnson JT. Incidence of unsuspected metastases in lateral cervical cysts. *Laryngoscope* 2000;**110**:1637–41
- 9 McGuirt WF, McCabe BF. Significance of node biopsy before definitive treatment of cervical metastatic carcinoma. *Laryngoscope* 1978;**88**:594–7
- 10 Pynnonen MA, Boyd Gillespie M, Roman B, Rosenfield RM, Tunkel DE, Bontempo L *et al.* Clinical practice guideline: evaluation of the neck mass in adults. *Otolaryngol Head Neck Surg* 2017;**157**:S1–S30
- 11 Franzen A, Gunzel T, Buchali A, Coordes A. Cystic lateral neck lesions: etiologic and differential diagnostic significance in a series of 133 patients. *Anticancer Res* 2019;**39**:5047–52
- 12 Cinberg JZ, Silver CE, Molnar JJ, Vogl SE. Cervical cysts: cancer until proven otherwise? *Laryngoscope* 1982;**92**:27–30
- 13 Abadi P, Johansen A, Godballe C, Gerke O, Hoilund-Carlsen PF, Thomassen A. 18F-FDG PET/CT to differentiate malignant necrotic lymph node from benign cystic lesions in the neck. *Ann Nucl Med* 2017;**31**:101–8
- 14 Lechner M, Liu J, Masterson L, Fenton TR. HPV-associated oropharyngeal cancer: epidemiology, molecular biology and clinical management. *Nat Rev Clin Oncol* 2022;**19**:306–27
- 15 Shukla P, Gupta D, Bisht SS, Pant MC, Bhatt ML, Srivastava K *et al.* Metastatic squamous cell carcinoma neck with occult primary: a retrospective analysis. *Indian J Med Paediatr Oncol* 2009;**30**:124–30
- 16 Panchbai AS, Choudhary MS. Branchial cleft cyst at an unusual location: a rare case with a brief review. *Dentomaxillofac Radiol* 2012;**41**:696–702
- 17 Health Research Authority Decision Tool. In: [hra-decisiontools.org.uk/research](http://hra-decisiontools.org.uk/research) [1 March 2023]
- 18 Granström G, Edström S. The relationship between cervical cysts and tonsillar carcinoma in adults. *J Oral Maxillofac Surg* 1989;**47**:16–20
- 19 Bath A, Murty G, Bradley P. Branchial cyst – to endoscope or not? *J Laryngol Otol* 1992;**106**:1006–7
- 20 Andrews PJ, Giddings CE, Su AP. Management of lateral cystic swellings of the neck in the over 40s age group. *J Laryngol Otol* 2003;**117**:318–20
- 21 Yehuda M, Schechter ME, Abu-Ghanem N, Golan G, Horowitz G, Fliss DM *et al.* The incidence of malignancy in clinically benign cystic lesions of the lateral neck: our experience and proposed diagnostic algorithm. *Eur Arch Otorhinolaryngol* 2018;**275**:767–73
- 22 Koch EM, Fazel A, Hoffmann M. Cystic masses of the lateral neck: proposition of an algorithm for increased treatment efficiency. *J Craniomaxillofac Surg* 2018;**46**:1664–8
- 23 Gronlund S, Mey K, Andersen E, Rasmussen ER. The true malignancy rate in 135 patients with preoperative diagnosis of a lateral neck cyst. *Laryngoscope Invest Otolaryngol* 2016;**1**:78–82
- 24 Jones G, Chudek D, Davies K, Upile N, Kinshuck A, Triantafyllou A *et al.* Lateral cystic neck masses in adults: a ten-year series and comparative analysis of diagnostic modalities. *J Laryngol Otol* 2022;**137**:312–18
- 25 Stefanicka P, Gnojckova N, Kurinec F, Profant M. Incidence and clinical predictors of cystic squamous cell carcinoma in lateral cervical cysts. *J Laryngol Otol* 2019;**133**:430–5
- 26 Coskun HH, Medina JE, Robbins KT, Silver CE, Strojan P, Teymoortash A *et al.* Current philosophy in the surgical management of neck metastases from head and neck squamous cell carcinoma. *Head Neck* 2015;**37**:915–26
- 27 Ye W, Arnaud EH, Langerman A, Mannion K, Topf MC. Diagnostic approaches to carcinoma of unknown primary of the head and neck. *Eur J Cancer Care* 2021;**30**:e13459
- 28 Junn JC, Soderlund KA, Glastonbury CM. Imaging of head and neck cancer with CT, MRI and US. *Semin Nucl Med* 2021;**51**:3–12