

# Sarcoidosis Presenting as an Intramedullary Spinal Cord Lesion

*F.B. Maroun, F.J. O'Dea, G. Mathieson, G. Fox, G. Murray,  
J.C. Jacob, R. Reddy, R. Avery*

**ABSTRACT: Objectives:** Sarcoidosis affects the spinal cord in only 0.43% of patients with sarcoidosis. Usually there is systemic involvement prior to the development of cord lesions. We present a case of sarcoid isolated to the intramedullary spinal cord, which was a diagnostic and therapeutic challenge. We review the case and then present a review of the literature with an emphasis on presentation, diagnosis and treatment. **Methods:** We have reviewed a patient who presented with an isolated sarcoid granuloma affecting the cervical spinal cord. All pertinent history and physical information was extracted from the patient's chart and through patient interview. Laboratory, radiographic and pathological investigations are presented. **Results and conclusions:** Fourteen patients have been reported with isolated intramedullary spinal cord sarcoidosis. Current practice supports the role of surgery for biopsy; mainstay of treatment is corticosteroids.

**RÉSUMÉ: Lésion intramédullaire comme mode de présentation initial d'une sarcoïdose. Objectifs:** La moelle épinière est impliquée dans la sarcoïdose chez seulement 0.43% des patients atteints de cette maladie. Il y a habituellement des lésions systémiques avant l'apparition de lésions de la moelle épinière. Nous présentons un cas de lésion sarcoïdienne intramédullaire isolée, ce qui représente un défi diagnostique et thérapeutique. Nous revoyons le cas et nous présentons une revue de la littérature en soulignant le mode de présentation, le diagnostic et le traitement. **Méthodes:** Nous revoyons le cas d'un patient porteur d'un granulome sarcoïdienne isolé de la moelle épinière cervicale. L'histoire médicale pertinente et les données de l'examen physique ont été tirés du dossier du patient ainsi que d'une entrevue avec le patient. Nous présentons l'investigation biochimique, radiologique et anatomopathologique. **Résultats et conclusions:** Quatorze patients porteurs d'une sarcoïdose localisée uniquement à la moelle épinière ont été rapportés dans la littérature. La chirurgie a un rôle à jouer dans le diagnostic et la corticothérapie constitue la base du traitement.

Can. J. Neurol. Sci. 2001; 28: 163-166

Sarcoidosis is a multisystem granulomatous disease. Five to ten percent of patients with systemic sarcoid may have intracranial manifestations; involvement of spinal cord is rare.<sup>1-3</sup> Spinal cord sarcoidosis may present as multiple (cord) lesions, diffuse leptomeningeal involvement, in the clinical context of systemic sarcoidosis. There are few case reports of intramedullary spinal cord sarcoidosis, without evidence of systemic sarcoidosis; less than 0.5% of patients have this clinical presentation.<sup>4</sup> We report a patient with an isolated intramedullary cervical spinal cord sarcoid granuloma, who had no evidence of systemic sarcoidosis, and also review relevant literature.

## CASE REPORT

A 42-year-old man presented with clinical features of cervical myelopathy. His large physique (weight 150kg; height 180.34 cm) precluded magnetic resonance imaging (MRI); as no MRI system in Canada could accommodate an individual of his stature. Myelogram revealed extradural cord compression at mid-cervical spinal level C5-C6. Cervical cord decompression, by laminectomy at C4-C7 spinal level

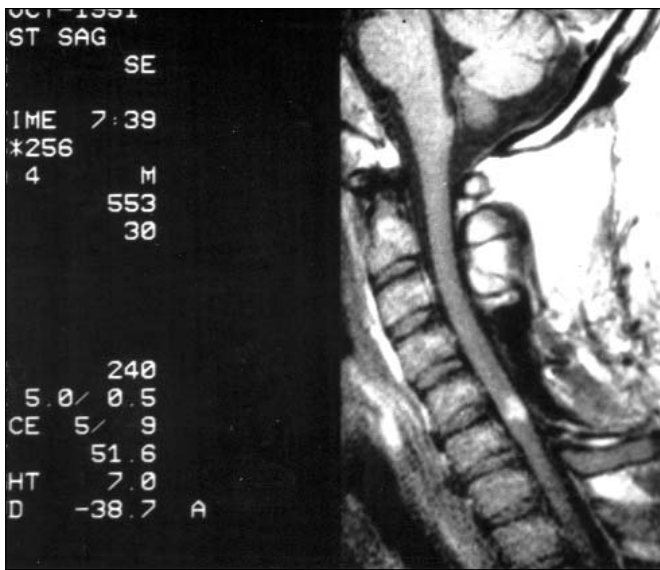
resulted in marked improvement in clinical deficit; mild residual spasticity in lower limbs did not interfere with his functional abilities.

Four years later, a fall while dancing was followed by acute onset of weakness of right arm and marked spastic paraplegia; bladder and bowel function was unimpaired. Cervical cord trauma was clinically suspected; treatment with a high dose of Decardon resulted in clinical improvement. However, this improvement was short-lived, as the clinical deficits worsened when steroid dose was decreased. Magnetic resonance imaging, (obtained in the USA) revealed an oval enhancing lesion at C5-C6 (Figure 1, 2). Differential diagnosis included intramedullary cervical cord neoplasm, lupus, Lyme disease, granulomatous disease and post-traumatic myelomalacia. Following

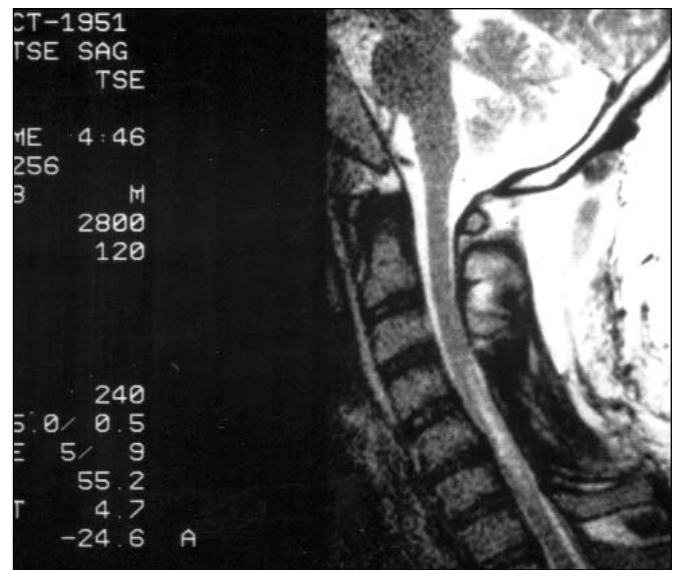
From the Division of Neurosurgery, Neurology, Departments of Radiology and Pathology, Memorial University of Newfoundland, Health Sciences Centre, St. John's, Newfoundland, Canada

RECEIVED AUGUST 21, 2000. ACCEPTED IN FINAL FORM DECEMBER 5, 2000.

Reprint requests to: F.B. Maroun, Rm. 5202, Health Sciences Centre, St. John's, NF, Canada A1B 3V6



**Figure 1:** T1 weighted MRI image with gadolinium enhancement of well circumscribed lesion at the level of C5-C6. Note the intramedullary location of the lesion.



**Figure 2:** T2 weighted MRI image of the spinal cord lesion. Note that the lesion appears to involve the spinal cord more diffusely.

further cranial and spinal MRI, surgical biopsy of the lesion was performed, through the previous laminectomy site (Figure 3). The lesion was firm in consistency, easily distinguishable from neural tissue, but was poorly demarcated in its deeper margins.

Histopathologic examination of the biopsy revealed a granulomatous lesion. The lesion was composed of Langerhans cells, epithelioid cells and lymphocytes, with a peripheral rim of mononuclear cells (Figure 4). There was no evidence of necrosis, caseation, foreign body, fungi, or acid fast bacilli. There was no growth of fungus or acid fast bacilli on culture. Following histologic diagnosis of sarcoidosis, despite extensive investigation, there was no evidence of systemic sarcoidosis.

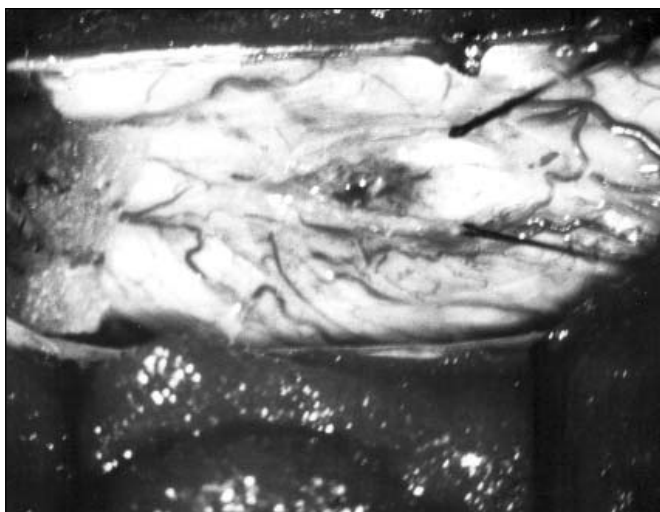
High dose prednisone therapy (60 mg od) was initiated together with rehabilitative therapy. Three months after biopsy, there was modest

improvement in function of the right arm but only minimal improvement in sensation and power in lower limbs. Adverse effects of steroid treatment included weight gain, and insulin dependent diabetes mellitus.

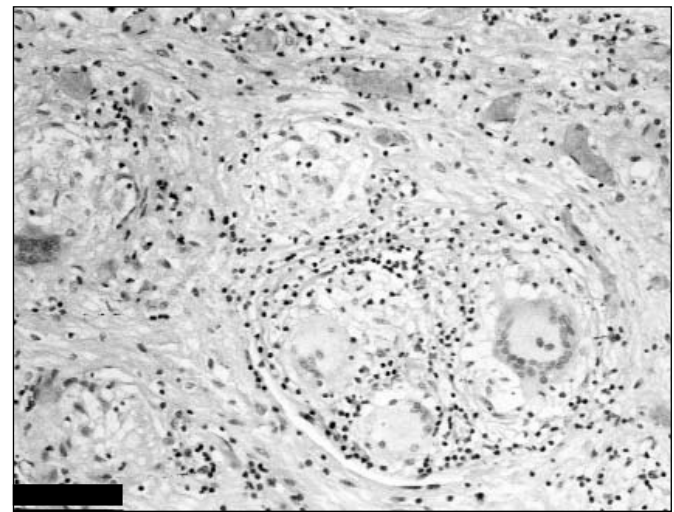
#### DISCUSSION

Thirty-seven cases of biopsy proved spinal cord sarcoidosis have been published.<sup>1,5-35</sup> Of these, 20 had evidence of systemic sarcoidosis.<sup>7-17,21,24,27,28,30,31,33,36-51</sup> Fourteen patients presented with an isolated intramedullary spinal cord sarcoid granuloma (Table).

The cervical cord is the site of predilection for spinal sarcoidosis; however, the mode of presentation is variable.



**Figure 3:** Operative photograph. Slight greyish discolorization of the spinal cord, intramedullary removal of the circumscribed lesion.



**Figure 4:** Granuloma with prominent multinucleated giant cells. Haematoxylin and eosin. Scale bar 100 µm.

**Table:** Cases of Biopsy Proven Intramedullary Spinal Cord Sarcoidosis Without Systemic Involvement

Author	Cord Level	Treatment	Outcome
Jefferson '57	C3-C4	Biopsy	Dead
Garcin '62	T12-L1	Subtotal removal and steroids	Improved
Hitchon '84	T5-T8	Total removal and steroids	No change
Rubenstein '84	C3-C6	Biopsy and steroids	No change
Vighetto '85	C5-C6	Biopsy and steroids	Improved
Kelly '88	C3-C6	Biopsy and steroids	Improved
Levievier '91	C3-C4	Subtotal removal and steroids	No change
Kayama '93	C3-C7	Subtotal removal and steroids	No change
Kayama '93	C3-C7	Subtotal removal and steroids	Improved
Jallo '97	C3-C6	Biopsy and steroids	Improved
Jallo '97	C2-C5	Biopsy and steroids	Improved
Chitoku '97	C6-T1	Biopsy and steroids	Improved
Lee '98	C4-C7	Biopsy and steroids	Improved
Lee '98	C1-C5	Subtotal removal and steroids	Worse
Present case	C5-C6	Subtotal removal and steroids	Improved

Sarcoidosis can present with clinical features suggesting meningeal involvement, or as an extramedullary intramedullary cord lesion.

Surgery is undertaken for biopsy and histopathologic diagnosis.<sup>5,6</sup> The mainstay of treatment is high dose corticosteroid therapy.<sup>5,6,8,10,41,52</sup> Radical surgical removal has been associated with worsening of neurological status,<sup>4,5,8,11</sup> because of the infiltrative nature, and hence the difficulty achieving total resection of the lesion. Corticosteroid therapy has been effective in reducing the size of the lesion, evidenced by MRI and improving clinical outcome, although complete recovery is rare.<sup>6,25,43</sup> Dose and duration of steroid therapy has not been defined. Reports suggest short-term improvement with steroid dose of 60 mg od for several weeks followed by tapering over a few months, although others have found relapses with short course treatment.<sup>6,41</sup> Hashmi<sup>41</sup> used 60 mg of prednisone daily for one year followed by a second year of lower doses. Higher doses have been used for a short period with good results, however, a standardized approach has not been formulated. Other pharmacologic therapy (with variable results) includes methotrexate, cyclophosphamide, cyclosporine, azathioprine, chlorambucil, chloroquine and hydroxychloroquine.<sup>55</sup>

Our patient showed clinical improvement, while receiving corticosteroid treatment, prior to histopathologic diagnosis but relapsed when steroid dose was decreased. Once the histopathologic diagnosis was made, reinstatement of high dose steroid therapy resulted in improvement. Complications of steroid therapy, including marked weight gain and diabetes mellitus necessitated decreasing doses of steroid.

Other pharmacologic agents have been used in patients with central nervous system sarcoidosis, particularly when there is

need to limit steroids. Stern reported success with cyclosporine in a steroid resistant patient with CNS neurosarcoidosis.<sup>54</sup>

Radiation therapy for brain lesions has also been undertaken with some measure of success.<sup>56-58</sup> This therapy remains to be investigated for spinal cord sarcoidosis.

## CONCLUSION

Sarcoidosis affecting the spinal cord is an exceptionally rare condition. It can mimic a neoplastic lesion, and therefore, pose a diagnostic and therapeutic challenge. Corticosteroids are the principal mode of treatment. Alternative pharmacologic agents, other than steroids, may be an option in the future.

## REFERENCES

1. Day AL, Sybert GW. Spinal cord sarcoidosis. *Ann Neurol* 1977;1:79-85.
2. Delaney P. Neurological manifestations in sarcoidosis: review of the literature, with a report of 23 cases. *Ann Intern Med* 1977;87:336-345.
3. Siltzbach LE, James DG, Neville E. Course and prognosis of sarcoidosis around the world. *Am J Med* 1974;57:847-852.
4. Bogousslavsky J, Hungerbuhler JP, Regli F, Garf HJ. Subacute myelopathy as the presenting manifestation of sarcoidosis. *Acta Neurochir (Wien)* 1982;65:193-197.
5. Chitoku S, Kawai S, Watabe Y, et al. Multiple intramedullary spinal sarcoidosis: case report. *Surg Neurol* 1997;48:522-526.
6. Jallo GI, Zagzag D, Lee M, et al. Intraspinal sarcoidosis: diagnosis and management. *Surg Neurol* 1997;48:514-521.
7. Askanazy CL. Sarcoidosis of the central nervous system. *J Neuropathol Exp Neurol* 1952;11:392-400.
8. Banerjee T, Hunt WE. Spinal cord sarcoidosis. Case report. *J Neurosurg* 1972;36:490-493.
9. Barauh JK, Glausauer FE, Sil R, Smith BH. Sarcoidosis of the

- cervical spinal canal: case report. *Neurosurgery* 1978;3:216-218.
10. Bernstein J, Rival J. Sarcoidosis of the spinal cord as the presenting manifestation of the disease. *South Med J* 1978;71:1571-1573.
  11. Buge A, Escourolle R, Poisson M, Rancurel G, Gray F. Sarcoidose medullaire: observation anatomo-clinique. *Ann Med Interne (Paris)* 1975;126:11-16.
  12. Campbell JN, Black P, Ostrow PT. Sarcoid of the cauda equina: case report. *J Neurosurg* 1977;47:109-112.
  13. Clifton AG, Stevens JM, Kapoor R. Spinal cord sarcoidosis with intramedullary cyst formation. *Br J Radiol* 1990;63:805-808.
  14. Collett P, Vighetto A, Bady B. Intramedullary sarcoidosis: an observation confirmed histologically. *Presse Med* 1983;40:2533-2534.
  15. de Morsier G, Maurice P, Martin F. Besnier-Boeck diffus des muscles et lesions du systeme nerveux central. *Acta Neurol Belg* 1954;54:34-51.
  16. Erickson TC, Odom G, Stern K. Boeck's disease (sarcoid) of the central nervous system. Report of a case with complete clinical and pathologic study. *Arch Neurol Psychiatr* 1942;48:613-621.
  17. Fazlullah S. Sarcoidosis with involvement of the nervous system. *Dis Chest* 1962;41:685-688.
  18. Garcin R. Sarcoidose de la moelle lombo sacree. In: Bunge I (ed). *Livre Jubilaire du Docteur Ludo van Bogaert*. Bruxelles: Les Editions Acta Medica Belgica 1962: 301-309.
  19. Hitchon PW, Haque AU, Olson JJ, Jacobs SK, Olson SP. Sarcoidosis presenting as an intramedullary mass. *Neurosurgery* 1984;15:86-90.
  20. Jefferson M. Sarcoidosis of the nervous system. *Brain* 1957;80:540-556.
  21. Kanoff RB, Ruberg RL. Intramedullary sarcoidosis of the spinal cord. Report of a case. *J Am Osteopath Assoc* 1978;77:868-873.
  22. Kayama S, Kikuchi S. Intramedullary spinal cord sarcoidosis. Report of two cases. *Spine* 1993;18:2118-2120.
  23. Kelly RB, Mahoney PD, Cowley KM. MR demonstration of spinal cord sarcoidosis. Report of a case. *AJNR Am J Neuroradiol* 1988;9:197-199.
  24. Kinuta Y, Isaka F, Uemura Y, Kikuchi H. Two cases of spinal sarcoidosis. *Spinal Surg* 1994;8:147-151.
  25. Lee M, Epstien FJ, Rezai AR, Zagzag D. Nonneoplastic intramedullary spinal cord lesions mimicking spinal cord lesions. *Neurosurgery* 1998;43(4):788-794.
  26. Levivier M, Brotchi J, Balariaux D, Pirotte B, Durand JF. Sarcoidosis presenting as an isolated intramedullary tumor. *Neurosurgery* 1991;29:271-276.
  27. Nishiura I, Tochio H, Koyama T. Cervical intramedullary sarcoidosis. *Neurochirurgia* 1992;35:163-166.
  28. Riffel B, Wietholer H, Storh M, Thron A, Eggert R. Zur Sarkoidose des Ruckenmararks. *Forsch Neurol Psychiatr* 1982;50:275-278.
  29. Rubenstien I, Hess J, Baum GL. Intramedullary spinal cord sarcoidosis. *Surg Neurol* 1984;21:272-274.
  30. Semins H, Nugent GR, Chou SM. Intramedullary spinal cord sarcoidosis. Case report. *J Neurosurg* 1972;37:233-236.
  31. Snyder R, Towfighi J, Gonatas NK. Sarcoidosis of the spinal cord. *J Neurosurg* 1976;44:740-743.
  32. Vighetto A, Fischer G, Collet P, Bady B, Trillet M. Intramedullary sarcoidosis of the cervical spinal cord. *J Neurol Neurosurg Psychiatr* 1985;48:477-479.
  33. Waxman JS, Hollenburg S. The spectrum of central nervous system sarcoidosis. A clinical and pathologic study. *Mt Sinai J Med* 1979;46:309-317.
  34. Wiederholt WC, Siekert RG. Neurological manifestations of sarcoidosis. *Neurology* 1965;15:1147-1154.
  35. Wood EH, Bream CA. Spinal sarcoidosis. *Radiology* 1959;73:226-233.
  36. Bogousslavsky J, Hungerbuhler JP, Regli F, Garf HJ. Subacute myelopathy as the presenting manifestation of sarcoidosis. *Acta Neurochir (Wien)* 1982;65:193-197.
  37. Caroscio JT, Yahr MD. Progressive myelopathy due to sarcoid. *Clin Neurol Neurosurg* 1980;84:217-222.
  38. Colover J. Sarcoidosis with involvement of the nervous system. *Brain* 1948;71:451-475.
  39. Gallenkamp U, Suchenwirth R. Spinale Sarkoidose. *Z Neurol* 1971;200:274-278.
  40. Goebel G. Myelitis transversa als Fruhmanifestations einer sarkoidose. *Nervenarzt* 1975;46:688-689.
  41. Hashmi M, Kyritsis AP. Diagnosis and treatment of intramedullary spinal cord sarcoidosis. *J Neurol* 1998;245:178-180.
  42. Kahan A. Sarcoidosis with involvement of the central nervous system. *Proc Roy Soc Med* 1952;45:509.
  43. Kirks DR, Newton TH. Sarcoidosis: a rare cause of spinal cord widening. *Radiology* 1972;102:643.
  44. Longscope WT, Freiman DG. Sarcoidosis or Besnier-Boeck-Schaumann disease. *JAMA* 1941;117:1321-1327.
  45. Moldover A. Sarcoidosis of the spinal cord. *Arch Int Med* 1958;102:414-417.
  46. Okansen V. Neurosarcoidosis: clinical presentations and course in 50 patients. *Acta Neurol Scand* 1986;73:283-290.
  47. Pennell WH. Boeck's sarcoid with involvement of the central nervous system. *Arch Neurol Psychiatr* 1951;66:728-737.
  48. Ravindra NM, Chase PH, Elguezabel A, Weinstein M. Spinal cord sarcoidosis. *NY State J Med* 1976;766:748-752.
  49. Reisner D. Boeck's Sarcoid and systemic sarcoidosis. Study of 35 cases. *Am Rev Tuberculosis* 1944;49:249-309.
  50. Strickland GT, Moser KM. Sarcoidosis with a Landry-Guillain-Barre syndrome and clinical response to corticosteroids. *Am J Med* 1967;43:131-135.
  51. Walker A. Sarcoidosis of the brain and spinal cord. *Postgrad Med J* 1961;37:431-436.
  52. Lexa FJ, Grossman RI. MRI of sarcoidosis in the head and spine: spectrum of manifestations and radiographic response to steroid therapy. *Am J Neuroradiol* 1994;15:973-982.
  53. Sharma OP. The treatment of sarcoidosis: if not corticosteroids, then what? *Pulmonary Perspectives* 1997;14:141-143.
  54. Stern BJ, Schonfeld SA, Sewell C, et al. The treatment of neurosarcoidosis with cyclosporine. *Arch Neurol* 1992;49:1065-1072.
  55. Jarniero D, Serié C. Les Neurosarcoidoses: revue de la Littérature. *Neurochirurgie* 1999;453:214-218.
  56. Agbogu N, Stern BJ, Sewell C, Yang G. Therapeutic considerations in patients with refractory neurosarcoidosis. *Arch Neurol* 1995;52:875-879.
  57. Bejar JM, Kerby GR, Ziegler DK, Festoff BW. Treatment of central nervous system sarcoidosis with radiotherapy. *Ann Neurol* 1985;18:258-260.
  58. Grizzanti JN, Knapp AB, Schecter AJ, Williams MH. Treatment of sarcoid meningitis with radiotherapy. *Am J Med* 1982;73:605-608.