



To flex or not to flex: oesophageal soft food bolus obstruction in the modern age

Christy M Moen¹ , Hiteshkumar Tailor¹ , Siggie Hammond¹, Bruce Hay², Nimmi Peedika³, A E Louise McMurrans³, Xin Yin Choo¹ and Murray Stewart¹

¹ENT, NHS Greater Glasgow & Clyde, Glasgow, UK, ²ENT, NHS Lanarkshire, Airdrie, UK and ³ENT, NHS Lothian, Edinburgh, UK

Main Article

Christy Maurice Moen takes responsibility for the integrity of the content of the paper

Data presented at ENT Scotland and Scottish National Video Conference ENT Audit Meeting, 8 November 2019, Stirling, Scotland.

Cite this article: Moen CM, Tailor H, Hammond S, Hay B, Peedika N, McMurrans AEL, Choo XY, Stewart M. To flex or not to flex: oesophageal soft food bolus obstruction in the modern age. *J Laryngol Otol* 2024;**138**: 957–960. <https://doi.org/10.1017/S0022215124000665>

Received: 28 June 2023

Revised: 19 November 2023

Accepted: 6 April 2024

First published online: 30 April 2024

Keywords:

Otolaryngology; endoscopy; gastrointestinal diseases; general surgery

Corresponding author:

Christy Maurice Moen;
Email: christy@moen.co.uk

Abstract

Background. Oesophageal soft food bolus obstruction is a common presentation to emergency departments. Often these patients are given medication with little evidence of efficacy. Although many cases self-resolve, some require removal of the obstruction. Delay in removal can lead to complications such as oesophageal perforation and mediastinitis. Traditionally, removal was performed by ENT surgeons using rigid oesophagoscopy, but oesophago-gastro duodenoscopy offers a safer alternative that does not require a general anaesthetic.

Method. The current performance, pathways and outcomes of patients attending emergency departments across three health boards in Scotland were reviewed.

Results. In total, 313 patients admitted for oesophageal soft food bolus obstruction were identified. Mixed practice for a single common presentation was observed. In addition, it was found that the majority of patients are already managed by surgery and gastroenterology services with good outcomes and low morbidity.

Conclusion. Patients presenting with soft food bolus obstruction should be referred to local surgery and gastroenterology services in the first instance.

Introduction

Oesophageal soft food bolus obstruction is a well-recognised and not uncommon presentation to emergency departments. While many obstructions are found to resolve spontaneously, there are cases that require surgical intervention.¹ Swift management to resolve the obstruction is important, given the potential risk of rare but serious consequences such as perforation and mediastinitis.²

In general, initial hospital management can consist of an observation period with simultaneous medical therapy postulated to relax the oesophageal tone to permit the bolus to migrate distally.³ Failing this, the still often practiced approach is rigid oesophagoscopy performed by ENT surgeons under general anaesthetic.

Access to and quality of flexible oesophagoscopy and/or oesophago-gastro duodenoscopy equipment has vastly improved. Given the advantage of negating the need for general anaesthesia, this procedure offers patients a quicker recovery with a smaller risk of complications.⁴ It is performed by general surgeons, gastroenterologists or nurse endoscopists.

The aim of this study was to review the current performance, pathways and outcomes of patients attending emergency departments across three health boards in Scotland to provide evidence-based practice in a condition that otherwise has a poor, historical or conflicted evidence base.

Materials and methods

This study was approved as an audit by the Research Ethical Committee and local Caldicott guardian approvals were gained. Data were requested from clinical informatics on all patients admitted with a soft food bolus obstruction in three Scottish territorial health boards, Greater Glasgow & Clyde, Lothian and Lanarkshire, for periods between January 2016 and December 2018. The International Classification of Diseases, Tenth Revision codes used were T18.1 (foreign body in oesophagus) and K22.2 (oesophageal obstruction). A retrospective case note review was carried out to record details of presentation, emergency department treatment, speciality management and final outcome for each patient, including any complications.

Results and analysis

We identified 377 patients admitted with suspected food bolus. Of these, 64 patients had a sharp and/or solid material obstruction and so were excluded. The mean age of the patients was 55 years (range, 7–93 years) and 63 per cent of patients were male (Table 1).

Table 1. Patient characteristics included in this study

Total number of patients (after exclusions) (n)	313
Male (n (%))	197 (63)
Female (n (%))	116 (37)
Age (mean (range); years)	55 (7–93)
Previous food bolus (n (%))	108 (35)
Patient with hypertension (n (%))	44 (14)
Patient with ischaemic heart disease (n (%))	25 (8)

Overall, 35 per cent of patients reported prior history of food bolus obstruction, 12 per cent had a known oesophageal stricture and 8 per cent had a history of oesophageal malignancy. The most common medical co-morbidity was arterial hypertension, with 14 per cent of patients having this diagnosis. In addition, 8 per cent of patients had ischaemic heart disease.

Ultimately, approximately two-thirds of patients admitted required therapeutic oesophago-gastro duodenoscopy, 18 per cent had a rigid oesophagoscopy and 16 per cent had spontaneous resolution (Table 2). In the spontaneous resolution group, 28 per cent of patients received no medical management and 72 per cent received Buscopan. Data on pre-existing arterial hypertension and ischaemic heart disease were collected as these are contraindications to Buscopan. Despite this spread of final intervention, 37 per cent of patients were initially admitted under ENT, 35 per cent to general surgery and 28 per cent to gastroenterology (Figure 1).

Of those initially admitted under ENT, 23 per cent had spontaneous resolution, 47 per cent underwent rigid oesophagoscopy and a further 30 per cent were referred on for oesophago-gastro duodenoscopy. The referral for oesophago-gastro duodenoscopy was as a result of a mixture of initial clinical decision thinking oesophago-gastro duodenoscopy more appropriate and the food bolus being distal and the rigid scope failing. Of those initially admitted under general surgery, 12 per cent had spontaneous resolution, 86 per cent required oesophago-gastro duodenoscopy while only 2 per cent were referred to ENT for rigid oesophagoscopy. A smaller proportion were referred to the gastroenterology team, of which 11 per cent had spontaneous resolution, 88 per cent had oesophago-gastro duodenoscopy and only 1 per cent were referred on to ENT for rigid oesophagoscopy.

The mean time taken between time of admission and time of procedure was 16.2 hours for oesophago-gastro duodenoscopy and 15.6 hours in rigid oesophagoscopy.

The average distance of the bolus from the incisors was 28 cm, with the majority found at the mid or distal oesophagus (Table 3).

Complication rates were also analysed (Table 4). Of the 57 rigid oesophagoscopies, there were 8 reported complications (complication rate of 14 per cent), including 1 perforation. Of the 206 oesophago-gastro duodenoscopies performed, there were only 6 reported complications (complication rate of 3 per cent), with no known perforations.

Table 2. Final outcome of treatment

Oesophago-gastro duodenoscopy (n (%))	206 (66)
Rigid oesophagoscopy (n (%))	57 (18)
Spontaneous resolution (n (%))	50 (16)

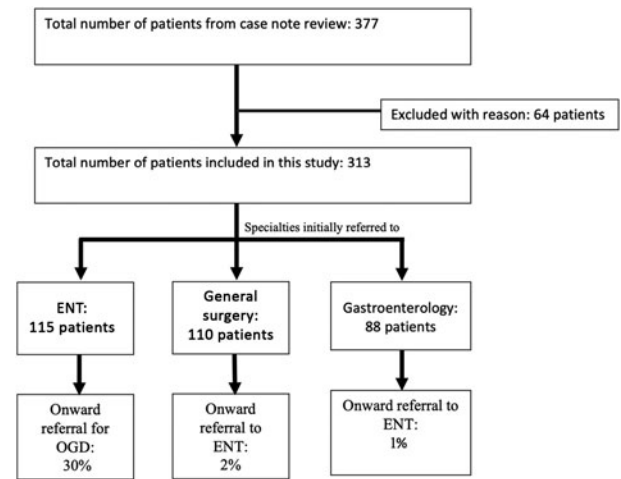


Figure 1. Initial and subsequent referrals. OGD = oesophagogastro duodenoscopy

Table 3. Site of food bolus

Average distance from incisors (cm)	28
Cricopharyngeus muscle (%)	17
Proximal oesophagus (%)	12
Mid oesophagus (%)	20
Distal oesophagus (%)	51

Medical management

The use of Hyoscine butylbromide (also known as Buscopan) was also measured. Eight per cent of patients who were given buscopan also had a diagnosis of IHD. While 61 per cent of all patients received at least one dose of Buscopan during their admission, there was a success rate of only 18 per cent (Table 5).

There were also patients who received magnesium sulphate, Peptac, diazepam, metoclopramide or triple-dose Buscopan; all of these patients required surgical intervention.

Discussion

The oesophagoscopy procedure for relief of a foreign body has been in existence for nearly 200 years. Its historical origin in ENT is probably owed to Chevalier Jackson, who mastered the rigid oesophagoscopy approach in the early 1900s.⁵ Prior to this, it was seen as a potentially fatal procedure in untrained

Table 4. Comparison of complications rate in oesophago-gastro duodenoscopy and rigid oesophagoscopy

Complication	Oesophago-gastro duodenoscopy (N = 206)	Rigid oesophagoscopy (N = 57)
Total (n (%))	6 (3)	8 (14)
- Mucosal injuries (n (%))	4 (2)	6 (10)
- Oral injuries (n (%))	2 (1)	1 (2)
- Oesophageal perforation (n (%))	0 (0)	1 (2)

Table 5. Success from use of medical adjuncts

Medical therapy	Patients receiving adjunct (n (%))	Patients needing endoscopic intervention (n (%))
Buscopan	192 (61)	157 (82)
Fizzy drink	62 (53)	50 (81)
Glucagon	14 (8)	11 (79)
Glyceryl trinitrate	7 (6)	5 (71)

hands, and even now the procedure has significant risks. Easy access to oesophago-gastro duodenoscopy has introduced an arguably safer alternative to removal of soft food bolus. However, patient pathways have not been updated to mirror this change in practice, exemplified by the high rate of initial ENT referrals, over a third, despite ensuing subsequent onward referral for oesophago-gastro duodenoscopy.

The vast majority of patients presenting with a soft food bolus were ultimately managed with therapeutic oesophago-gastro duodenoscopy. Longstreth *et al.* found that oesophago-gastro duodenoscopy permitted disimpaction in 98 per cent of soft food boluses.⁶ In Scotland, most oesophago-gastro duodenoscopies are performed by both general surgery and gastroenterologists. A logical framework for dealing with soft bolus impaction is needed that is pragmatic, workable and evidence based.

Furthermore, acute ENT services in the participating Scottish health boards are centralised. Patients may require inter-hospital transfer from the presenting emergency department to the acute ENT site, which adds delay to treatment, increases inconvenience and adds to the resource burden. General surgery acute teams generally are not centralised, negating the need for inter-hospital transfer.

The complication rate of oesophago-gastro duodenoscopy was found to be only 3 per cent compared to 14 per cent in rigid oesophagoscopy. The increased complication rate of rigid oesophagoscopy compared with oesophago-gastro duodenoscopy has been shown in previous studies.⁴ In addition to this, oesophago-gastro duodenoscopy is almost exclusively performed under sedation, removing the risks and complications related to a general anaesthetic and the post-operative monitoring required.⁷ Patients should be offered a less risky procedure wherever possible.

It was found that 71 per cent of food boluses were located in the mid or distal oesophagus. It is widely acknowledged that complications of rigid oesophagoscopy increase the further the distance traversed, therefore full oesophagoscopy is now rarely performed.⁸ Furthermore, if an oesophageal perforation were to happen, this is often managed by general surgery.⁹

Although some ENT surgeons can perform trans-nasal oesophagoscopy, it is not part of the core ENT training and practice in the UK, nor is flexible nasendoscopy (FNE) designed for use in the oesophagus. As such, the role of FNE in these patients is often redundant, as it rarely changes management.

Eosinophilic oesophagitis is a recognised predisposing factor for food bolus obstruction, being found in 26.3–54.8 per cent of patients.^{10,11} The diagnosis of eosinophilic oesophagitis requires endoscopic evaluation and multiple random biopsies.¹² While eosinophilic oesophagitis can be assessed with rigid oesophagoscopy, it is not a condition routinely managed under ENT.

Patient perception of the location of the food bolus (e.g. above or below the manubrium) is often used by emergency department physicians to predict the location of the food bolus and then refer to ENT or general surgery depending on its location. However, there is little evidence to suggest patient perception has any accuracy in predicting the location of the food bolus.^{13,14}

We were unable to collect data on patient localisation of the food bolus as documentation was often not specific enough regarding localisation. However, most food bolus were located in the mid to distal oesophagus, and the high ENT referral is likely due to inaccurate localisation to the throat and misunderstanding of the pathophysiology by referring clinicians. It could be postulated that once sedation or anaesthesia is administered, the bolus may migrate distally because of reduced oesophageal tone. However, delayed regurgitation of fluids is perhaps a better hallmark of distal location, although no evidence was found to demonstrate this.

We found the same rate of spontaneous resolution for patients receiving Buscopan as for patients swallowing a fizzy beverage. There is very little evidence to support the use of pharmacological interventions in food bolus.^{3,15} The current popular use of Buscopan is probably a result of the erroneous reference in *Scott-Brown's Otolaryngology* (6th edition) to a poorly designed and uncontrolled study of 16 patients in 1991 receiving various medical adjuncts; Buscopan was not even one of the original interventions but is recommended.^{16,17}

- Oesophageal soft food bolus obstruction is a well-recognised and not uncommon presentation to emergency departments
- Many oesophageal soft food bolus obstructions are found to resolve spontaneously, but some cases require surgical intervention
- Very mixed practice for a single common presentation was demonstrated
- The majority of patients are already managed by surgery and gastroenterology services with good outcomes and low morbidity
- Patients presenting with soft food bolus obstruction should be referred to local surgery and gastroenterology services in the first instance

Buscopan also has side effects, and the Medicines and Healthcare products Regulatory Agency put out an alert in 2017 regarding the very small risk of serious adverse reactions in patients with underlying cardiac disease.¹⁸ A significant number of our patients had ischaemic heart disease, implying the risks outweigh any benefit in the administration of Buscopan for food bolus. The use of medical adjuncts has a very poor evidence base, and even with this study, the only potential adjunct we would advocate is fizzy drinks.

The main limitation of this study arises from its retrospective character and the uncontrolled non-standard documentation and heterogenous practices.

Conclusion

We demonstrate very mixed practice for a single common presentation. We also show that the majority of patients are already managed by surgery and gastroenterology services with good outcomes and low morbidity. We therefore advocate that patients presenting with soft food bolus obstruction should be referred to local surgery and gastroenterology services in the first instance. This would reduce the need for inter-hospital transfers, minimise delays to treatment and avoid the risks associated with rigid oesophagoscopy. Further

work will be required to identify risk factors in the patients necessitating transfer to ENT services (2 per cent in this study) to make the framework as robust as possible. This will form the basis of further audit work.

Competing interests. None declared

References

- 1 Scott-Brown WG, Gleeson M. *Scott-Brown's Otolaryngology, Head and Neck Surgery*. London: Hodder Arnold, 2008
- 2 Loh KS, Tan LK, Smith JD, Yeoh KH, Dong F. Complications of foreign bodies in the esophagus. *Otolaryngol Head Neck Surg* 2000;**123**:613–16
- 3 Leopard D, Fishpool S, Winter S. The management of oesophageal soft food bolus obstruction: a systematic review. *Ann R Coll Surg Engl* 2011;**93**:441–4
- 4 Gmeiner D, von Rahden BHA, Meco C, Hutter J, Oberascher G, Stein HJ. Flexible versus rigid endoscopy for treatment of foreign body impaction in the esophagus. *Surg Endosc* 2007;**21**:2026–9
- 5 Boyd AD. Chevalier Jackson: the father of American bronchoesophagoscopy. *Ann Thorac Surg* 1994;**57**:502–5
- 6 Longstreth GF, Longstreth KJ, Yao JF. Esophageal food impaction: epidemiology and therapy. A retrospective, observational study. *Gastrointest Endosc* 2001;**53**:193–8
- 7 Hazen SE, Larsen PD, Martin JLH. General anesthesia and elderly surgical patients. *AORN J* 1997;**65**:815–21
- 8 Wennervaldt K, Melchioris J. Risk of perforation using rigid oesophagoscopy in the distal part of oesophagus. *Dan Med J* 2012;**59**:A4528
- 9 Chirica M, Kelly MD, Siboni S, Aiolfi A, Riva CG, Asti E *et al.* Esophageal emergencies: WSES guidelines. *World J Emerg Surg* 2019;**14**:26
- 10 Desai TK, Stecevic V, Chang CH, Goldstein NS, Badizadegan K, Furuta GT. Association of eosinophilic inflammation with esophageal food impaction in adults. *Gastrointest Endosc* 2005;**61**:795–801
- 11 Ntuli Y, Bough I, Wilson M. Recognising eosinophilic oesophagitis as a cause of food bolus obstruction. *Frontline Gastroenterol* 2020;**11**:11–15
- 12 Spergel JM, Dellon ES, Liacouras CA, Hirano I, Molina-Infante J, Bredenoord AJ *et al.* Summary of the updated international consensus diagnostic criteria for eosinophilic esophagitis: AGREE conference. *Ann Allergy Asthma Immunol* 2018;**121**:281–4
- 13 Cook IJ. Diagnostic evaluation of dysphagia. *Nat Clin Pract Gastroenterol Hepatol* 2008;**5**:393–403
- 14 Ko HH, Enns R. Review of food bolus management. *Can J Gastroenterol* 2008;**22**:805–8
- 15 Hardman J, Sharma N, Smith J, Nankivell P. Conservative management of oesophageal soft food bolus impaction. *Cochrane Database Syst Rev* 2020;**(5)**:CD007352
- 16 Scott-Brown WG. *Scott-Brown's Otolaryngology*, 6th edn. CRC Press, 1996:3928
- 17 Tibbling L, Stenquist M. Foreign bodies in the esophagus. A study of causative factors. *Dysphagia* 1991;**6**:224–7
- 18 Medicines and Healthcare products Regulatory Agency. MHRA safety alert: hyoscine butylbromide (Buscopan) injection. *Drug Ther Bull* 2017;**55**:51