



# An infant case of coronary artery aneurysms with no systemic symptoms after treatment for Kawasaki disease

## Brief Report

**Cite this article:** Asai Y, Suzuki T, and Yamada M (2024) An infant case of coronary artery aneurysms with no systemic symptoms after treatment for Kawasaki disease. *Cardiology in the Young* **34**: 2007–2009. doi: [10.1017/S1047951124025563](https://doi.org/10.1017/S1047951124025563)


Received: 14 February 2024  
Revised: 26 April 2024  
Accepted: 16 May 2024  
First published online: 5 November 2024

### Keywords:

Kawasaki disease; coronary artery abnormalities; infant

### Corresponding author:

T. Suzuki;  
Email: [takanori-s@axel.ocn.ne.jp](mailto:takanori-s@axel.ocn.ne.jp)

Yumiko Asai<sup>1</sup>, Takanori Suzuki<sup>2</sup>  and Midori Yamada<sup>1</sup>

<sup>1</sup>Department of Pediatrics, Kariya Toyota General Hospital, Kariya, Aichi, Japan and <sup>2</sup>Department of Pediatrics, School of Medicine, Fujita Health University, Toyoake, Aichi, Japan

### Abstract

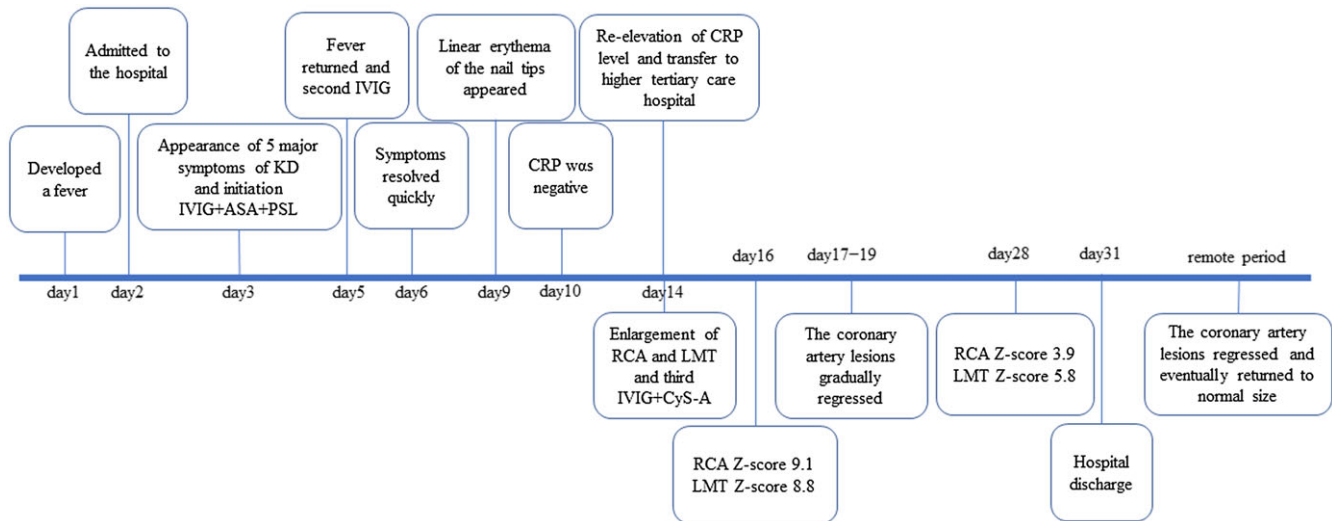
This case is a 4-month-old patient with Kawasaki disease who showed coronary artery lesions after a disease relapse. Following the guidelines from the Randomised Controlled Trial to Assess Immunoglobulin plus Steroid Efficacy, the patient initially saw an improvement in symptoms. However, a relapse occurred despite low levels of C-reactive protein, leading to significant coronary artery growth. Treatment with a third dose of intravenous immunoglobulin and cyclosporine led to a slow reduction in the size of the coronary artery abnormalities. This case highlights the difficulty in monitoring Kawasaki disease progression through clinical symptoms and C-reactive protein levels alone. We also emphasise the necessity of echocardiographic monitoring in patients receiving anti-inflammatory treatments, including steroids, because coronary artery problems can arise or continue without the usual signs of Kawasaki disease or increased C-reactive protein levels.

## Background

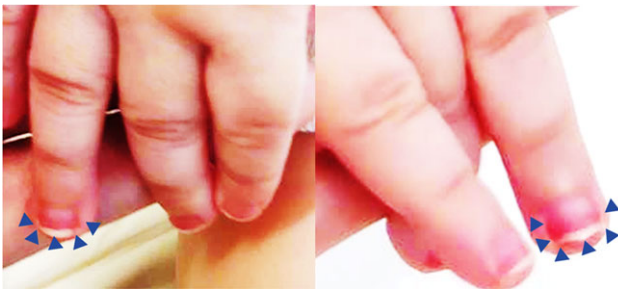Kawasaki disease is an acute form of systemic vasculitis and the most common cause of paediatric-acquired heart disease in developed countries.<sup>1</sup> In Japan, the Kobayashi score is used to predict intravenous immunoglobulin resistance and subsequent complications, including coronary artery abnormalities, in children with Kawasaki disease.<sup>2</sup> According to the Randomised Controlled Trial to Assess Immunoglobulin plus Steroid Efficacy for Kawasaki disease, a score of >5 indicates the need to administer steroids from the initial treatment of the disease.<sup>3</sup> We describe a case of a patient who developed coronary artery abnormalities after relapse following acute treatment for Kawasaki disease, despite the absence of an inflammatory reaction or Kawasaki disease symptoms.

## Case

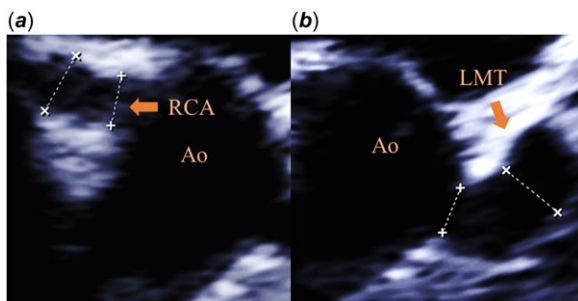
The patient, a 4-month-old boy, developed a fever the night before admission and was referred to our hospital. The patient's clinical course is shown in Figure 1. He was admitted to the hospital with the chief complaints of fever and poor feeding on the second day of his illness. At that time, there were no symptoms of Kawasaki disease other than fever. The patient's abdomen was flat and soft, his respiratory sounds were clear, his heart sounds were clear, and no murmurs were detected. Laboratory findings comprised a leukocyte count of 25,300/ $\mu$ L (6000–17500/ $\mu$ L), a neutrophil count of 75.0% (37–72%), C-reactive protein levels of 6.98 mg/dL (<0.2 mg/dL), a platelet count of  $52 \times 10^4$  ( $15\text{--}40 \times 10^4$ ), a sodium level of 135 mmol/L (138–145 mmol/L), and an aspartate aminotransferase level of 41 IU/L (25–85 IU/L). Treatment with cefotaxime was initiated as a bacterial infection was suspected. On the third day of the illness, the high fever persisted, and ocular conjunctival hyperaemia, cervical lymphadenopathy, indeterminate erythema excluding lip erythema, and induration oedema appeared. As five of the six symptoms of Kawasaki disease were observed, Kawasaki disease was diagnosed. The patient was started on intravenous immunoglobulin at 2 g/kg and aspirin at 30 mg/kg/day on the third day. His Kobayashi score was 7 points in total. This consisted of 1 point for hyponatraemia (129 mmol/L), 2 points for fever lasting, 2 points for elevated aspartate aminotransferase (114 IU/L), and 1 point for his age. In accordance with the Randomised Controlled Trial to Assess Immunoglobulin plus Steroid Efficacy study, intravenous steroid at 2 mg/kg/day was administered from the initial treatment. Echocardiography revealed no remarkable change. There were no coronary artery wall irregularities and no obvious increase in luminosity. Left ventricular wall motion was good, and no pericardial effusion or valve regurgitation was observed. The fever resolved on the fourth day of the illness, but on the fifth day, the fever returned (38.6°C). On the same day, a second dose of intravenous immunoglobulin 2 g/kg was administered. The fever resolved on the sixth day of illness, and the patient was fever-free thereafter, with no



**Figure 1.** Timeline of key events, ASA = aspirin; CRP = C-reactive protein; CyS = cyclosporine; HD = hospital days; IVIG = intravenous immunoglobulin; KD = Kawasaki disease; LMCA = left main coronary artery; RCA = right coronary artery; PSL = prednisolone.



**Figure 2.** Linear erythema of the nail tips, which differed from the patient's previous rigid oedema, in an infant with Kawasaki disease.



**Figure 3.** Arteries of an infant with Kawasaki disease. (a) Dilatation in the right coronary artery. (b) Diffuse dilatation in the left main coronary artery trunk. Echocardiography showed enlargement of the right coronary artery to 5.0 mm (z score 9.1) and the left main coronary artery trunk to 4.8 mm (z score 8.8).

recurrence of the main symptoms of Kawasaki disease. Around the ninth day, linear erythema of the nail tips, which differed from the previous rigid oedema, appeared (Figure 2). Echocardiography on the ninth day showed no significant coronary artery abnormalities. On the tenth day of the illness, a blood test showed a C-reactive protein level of 0.35 mg/dL, which was almost negative, and the treatment course was good. On the fourteenth day, however, his blood test showed a re-elevation of C-reactive protein to 5.20 mg/dL. The patient was considered to have relapsed and was transferred to a higher tertiary care hospital for further treatment.

After the patient was transferred, echocardiography showed enlargement of the right coronary artery to 5.0 mm (z score 9.1) and the left main coronary artery trunk to 4.8 mm (z score 8.8) (Figure 3). The inflammation from Kawasaki disease persisted, so a third dose of intravenous immunoglobulin 2 g/kg was administered on the fourteenth day of illness, and cyclosporine was given at a dose of 5 mg/kg/day for 6 days. Thereafter, the coronary lesions showed no further enlargement and gradually regressed to normal size. Blood tests on the twentieth day of illness confirmed that C-reactive protein was almost negative at 0.32 mg/dL. Echocardiographic evaluation on the twenty-eighth day showed residual small to moderate coronary artery abnormalities, with the right coronary artery having a diameter of 2.7 mm (z score 3.9) and the left main coronary artery trunk, 3.5 mm (z score 5.8). Two antiplatelet agents, aspirin and clopidogrel, were prescribed, and the patient was discharged from the hospital on the thirtieth day. The patient is currently under outpatient follow-up care. The coronary artery aneurysm gradually regressed in size and eventually returned to a size within the normal range by Z score derived from body surface area. There were no specific cardiovascular events.

## Discussion

We have described a case of Kawasaki disease, in which the patient had no symptoms of Kawasaki disease, disappearance of fever, and very low C-reactive protein levels after treatment with intravenous immunoglobulin. However, the patient subsequently relapsed and developed coronary artery abnormalities.

C-reactive protein is an important biomarker of inflammation in Kawasaki disease and is used in the Kobayashi scoring system to evaluate the severity of the disease.<sup>2</sup> The prescribed treatment for this condition is based on the Randomised Controlled Trial to Assess Immunoglobulin plus Steroid Efficacy study. High Kobayashi scores indicate the need for steroid use from the early stages of the disease.<sup>3</sup> It is known that the inflammatory response, as indicated by C-reactive protein levels, is reduced in Kawasaki disease by steroids.<sup>3</sup> Even with low C-reactive protein levels, there is still a risk of coronary artery aneurysms in the acute phase of Kawasaki disease.<sup>4</sup> In the present case, it is possible that steroids

only partially suppressed inflammation and inhibited C-reactive protein, which then flared up again, resulting in coronary artery abnormalities. When steroids are used during the acute phase of Kawasaki disease, the inflammatory markers themselves may not be an indicator of disease activity. This is a very important observation, well known to those who care for many Kawasaki disease patients but perhaps less well understood by the attending physician who do not see so many of these patients.

In this case, coronary artery abnormalities developed despite the complete resolution of the fever. There have been previous reports of cases in which coronary artery aneurysms developed despite the absence of fever.<sup>5</sup> In the acute treatment of Kawasaki disease, fever resolution can be achieved earlier with the administration of steroids, infliximab, and cyclosporine.<sup>3,6,7</sup> It should be kept in mind that fever may be masked by anti-inflammatory therapies. The patient in this case was an infant, and it is known that infants generally exhibit less consistent Kawasaki disease symptoms and are prone to greater disease severity.<sup>8,9</sup> In this case, the primary symptoms of Kawasaki disease were present prior to the start of treatment but, thereafter, Kawasaki disease symptoms were not apparent. Nail changes in Kawasaki disease have been previously reported.<sup>10</sup> The nail symptoms in our case were seen in the subacute phase of the disease and might suggest a persistent inflammatory response.

### Conclusions

When anti-inflammatory drugs, including steroids, are used in acute Kawasaki disease patients, blood laboratory findings and clinical symptoms may be masked, and coronary artery echocardiography should be utilised appropriately. In high-risk patients, close echocardiographic surveillance is warranted until coronary dimensions stabilise in order to guide therapy.

**Acknowledgements.** None.

**Financial support.** None.

**Competing interests.** The authors have no financial relationships or conflicts of interest to declare.

**Ethical standard.** The authors assert that all procedures contributing to this work comply with the ethical guidelines for biomedical research on human participants, 2006, India, and with the Helsinki Declaration of 1975, as revised in 2013, and has been approved by the relevant institutional committees.

### References

1. Newburger JW, Takahashi M, Burns JC. Kawasaki disease. *J Am Coll Cardiol* 2016; 67: 1738–1149.
2. Kobayashi T, Inoue Y, Takeuchi K et al. Prediction of intravenous immunoglobulin unresponsiveness in patients with Kawasaki disease. *Circulation* 2006; 113: 2606–2612.
3. Kobayashi T, Saji T, Otani T et al. Efficacy of immunoglobulin plus prednisolone for prevention of coronary artery abnormalities in severe Kawasaki disease (RAISE study): a randomised, open-label, blinded-endpoints trial. *Lancet* 2012; 379: 1613–1620.
4. Minami T, Hiroyuki S, Takashi T. A case of a boy with Kawasaki disease who developed a coronary artery aneurysm after a low C-reactive protein level in the acute phase of the disease. *Prog Med* 2003; 23: 1737–1740.
5. Yoshino A, Tanaka R, Takano T, Oishi T. Afebrile Kawasaki disease with coronary artery dilatation. *Pediatr Int* 2017; 59: 375–377.
6. Hamada H, Suzuki H, Onouchi Y et al. Efficacy of primary treatment with immunoglobulin plus ciclosporin for prevention of coronary artery abnormalities in patients with Kawasaki disease predicted to be at increased risk of non-response to intravenous immunoglobulin (KAICA): a randomised controlled, open-label, blinded-endpoints, phase 3 trial. *Lancet* 2019; 393: 1128–1137.
7. Tremoulet AH, Jain S, Jaggi P et al. Infliximab for intensification of primary therapy for Kawasaki disease: a phase 3 randomised, double-blind, placebo-controlled trial. *Lancet* 2014; 383: 1731–1738.
8. Genizi J, Miron D, Spiegel R, Fink D, Horowitz Y. Kawasaki disease in very young infants: high prevalence of atypical presentation and coronary arteritis. *Clin Pediatr* 2003; 42: 263–269.
9. Salgado AP, Ashouri N, Berry EK et al. High risk of coronary artery aneurysms in infants younger than 6 Months of age with Kawasaki disease. *J Pediatr* 2017; 185: 112–116.e1.
10. Mitsuishi T, Miyata K, Ando A, Sano K, Takanashi J, Hamada H. Characteristic nail lesions in Kawasaki disease: case series and literature review. *J Dermatol* 2022; 49: 232–238.