

Acute gastric volvulus: case report and review of the literature

William E. Sevcik, MD,* Ivan P. Steiner, MD†

ABSTRACT: Gastric volvulus is a rare but potentially life-threatening cause of upper gastrointestinal obstruction. Emergency physicians must maintain a high index of suspicion in patients who present with signs and symptoms suggesting foregut occlusion. We report an illustrative case and review the pathogenesis, classification, diagnosis and treatment of this rare entity.

RÉSUMÉ : Le volvulus gastrique est une cause rare mais potentiellement fatale de l'obstruction gastro-intestinale supérieure. Les urgentologues doivent se montrer très vigilants face à des patients qui présentent les signes et symptômes évoquant une occlusion de l'intestin grêle. Nous présentons un cas illustrant cette pathologie rare et passons en revue la pathogénèse, la classification, le diagnostic et le traitement.

Key words: volvulus, abdominal pain, upper gastrointestinal obstruction, surgical emergency

Introduction

The term volvulus is derived from the Latin word *volvere*, meaning to turn or roll. Gastric volvulus is defined as an acquired rotation of the stomach or parts thereof more than 180° creating a closed loop obstruction.¹ Though rare, gastric volvulus is a true surgical emergency that is life-threatening if not recognized and treated quickly. Since Berti's initial description in 1866,² there have been approximately 300 reported cases. This paper reports a case of acute gastric volvulus, reviews the pathogenesis, clinical features, diagnosis, and treatment options, and offers some practical suggestions for emergency physicians.

Case report

A 76-year-old woman presented to the emergency department (ED) with a 2-day history of abdominal pain, nausea and bilious vomiting. Attempts to drink caused retching within 5 to 10 minutes, and she could not keep anything down. Her pain had started in the upper abdomen, but generalized prior to ED presentation. She had no other gastrointestinal

symptoms. Her family physician had prescribed an H₂ blocker and an anti-emetic 24 hours prior to her arrival at the ED.

She recalled 2 similar episodes in the past, both which resolved spontaneously after 1 to 2 hours. Her medical history was also significant for extremity fractures, hypertension, arthritis, "irregular heart beats" and a penicillin allergy. Current medications included an ACE inhibitor, a calcium-channel blocker and a nonsteroidal anti-inflammatory.

Physical examination demonstrated an elderly woman who appeared unwell and dehydrated. Pulse was 96 beats/min and regular, BP 140/100, respiratory rate 20/min, temperature 37°C and glucometer reading was 9 mmol/L. Mucous membranes were dry and there was moderate tenting of the skin. Bowel sounds were increased and her abdomen was distended, with diffuse tenderness to superficial and deep palpation. There was no guarding, rebound, masses or organomegaly. Rectal exam revealed no occult blood.

The initial clinical impression was vomiting and dehydration, probably secondary to gastric outlet obstruction. At this point a 500 mL normal saline fluid bolus was initiated, IV analgesics and anti-emetics were provided, and a nasogastric tube was placed, with some difficulty. Her leukocyte

*From the Division of Emergency Medicine and the †Department of Family Medicine, University of Alberta, Edmonton, Alta. This article has been peer reviewed.

count was $11.3 \times 10^9/L$ with 95% neutrophils. Serum sodium was 151 mmol/L, potassium 3.4 mmol/L, chloride 110 mmol/L and HCO_3^- 29 mmol/L. Her serum creatinine and BUN were 143 μ mol/L and 15.8 mmol/L respectively. The remainder of her lab results, including liver function tests, were normal. Abdominal radiographs demonstrated a large hiatus hernia with an air fluid level and a nasogastric tube passing below the diaphragm (Fig. 1).

A surgical consult was obtained. The consultant's impression was that the problem was a simple hiatus hernia. Because of the patient's condition and our concern about gastric outlet obstruction, a radiological consult was requested and an emergent barium swallow performed. This revealed a large sliding hiatus hernia with organoaxial volvulus of the stomach (Fig. 2). After surgical reassessment, the patient was taken for emergency surgery. At laparotomy, the gastric fundus, lying above the diaphragm, was reduced back to its anatomical position. The stomach was found to be viable and the hernia was surgically repaired. The patient recovered uneventfully and was discharged on the seventh post-operative day.

Discussion

Pathogenesis

The stomach is anchored at the cardia and tethered by the gastrocolic, gastrohepatic, gastrophrenic and gastrosplenic ligaments; however, the stomach's need to store, grind, and mix food requires that it be relatively mobile. As a result, some movement is normal and intermittent episodes of asymptomatic gastric rotation do occur.³ Using a cadaver model, Dalgaard⁴ demonstrated that it is easier to rotate a fluid-filled stomach than an empty one, and that a normal stomach can not rotate more than 180° unless the gastrosplenic or gastrocolic ligaments are divided. Thus, if the gastric ligaments are relaxed, any cause of gastric distention can predispose to excessive rotation, setting the stage for volvulus.⁵

A second major predisposing factor for gastric volvulus is the presence of a diaphragmatic defect that

allows stomach displacement into atypical spaces. In adults the most common such defect is a paraesophageal hernia.⁶ Other predisposing factors include diaphragmatic injury or surgery, congenital hernias, and diaphragmatic eventration associated with phrenic nerve paralysis, left lung resection, or pleural adhesions. In some cases, intra-abdominal adhesions act as a rotational axis for the stomach.⁷ Intrinsic lesions (e.g., gastric ulcer or neoplasm) or extrinsic pressure from adjacent masses can obstruct the stomach, altering normal anatomy, and predisposing to volvulus.

Types of volvuli

The most frequently used classification system was proposed by Singleton,⁸ who described 3 types of gastric volvulus: organoaxial, mesenteroaxial and combination-unclassified. Organoaxial volvulus is the most common variant, occurring in approximately 59% of cases.⁹ Because the duodenum and gastroesophageal (GE) junction are relatively fixed, the stomach rotates around the longitudinal axis, with the greater curvature rotating (most often) anteriorly.¹⁰ This rotation is analogous to "wringing out a wet rag."¹¹ In such cases, obstruction can occur at the GE junction, the pylorus, or both, and strangulation is more likely to occur.

In mesenteroaxial volvulus, which comprises 29% of cases,⁹ rotation occurs around the transgastric axis (a line connecting the middle of the lesser curvature with the middle of the greater curvature). The result is that the anterior gastric wall folds upon itself. Gastrosplenic ligament laxity is thought to be the predisposing factor,⁴ and this form of volvulus often occurs without concomitant diaphragmatic

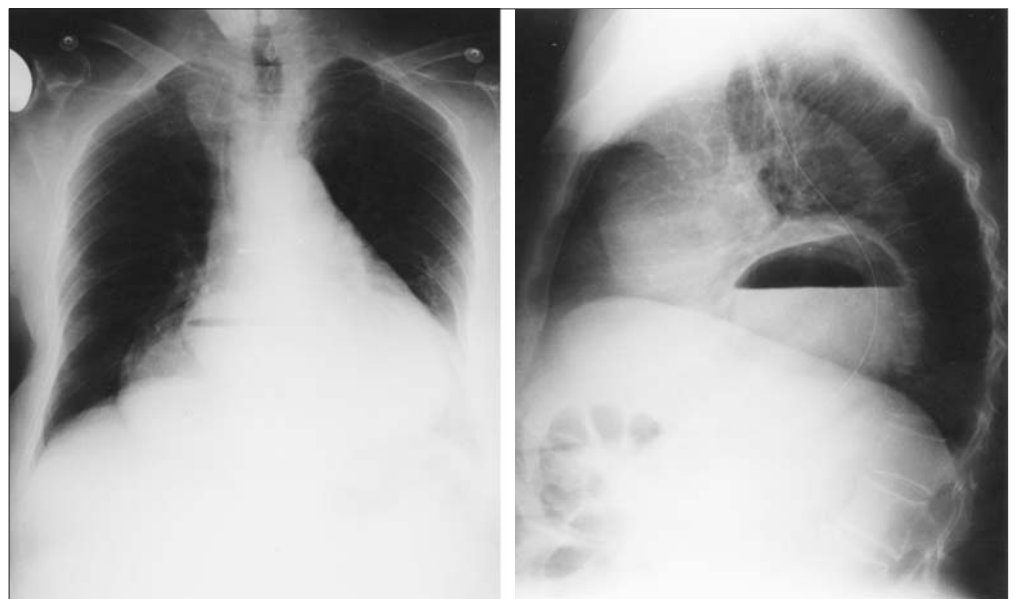


Fig. 1. Chest x-ray. Erect PA (left) and lateral (right): Large intra-thoracic hiatus hernia with associated air-fluid level. Nasogastric tube has its tip in middle part of the stomach.

defects.⁶ Complete obstruction and strangulation are unlikely and spontaneous detorsions with recurrent acute episodes may occur. Most cases of chronic volvulus are related to mesenteroaxial rotation.

The remaining 12% of volvuli exhibit features of both the above or remain unclassified.³ These usually present with chronic or recurrent symptoms.

Clinical features

Gastric volvulus most often occurs during the 5th decade of life⁷ but there are over 100 reported pediatric cases.¹² Signs and symptoms depend on the speed of onset, the severity of torsion, the age of the patient, the degree of obstruction and the presence of complications.

Gastric volvulus can present as an acute surgical emergency or a chronic, recurring problem. Approximately $\frac{1}{3}$ of all episodes present acutely with sudden, severe left upper quadrant or left lower thoracic pain. Pain may radiate to the back, neck or interscapular area and may be accompanied by dyspnea. Vomiting occurs and quickly progresses to dry heaves. The upper abdomen may be distended while the lower abdomen remains flat and soft. Borchardt's

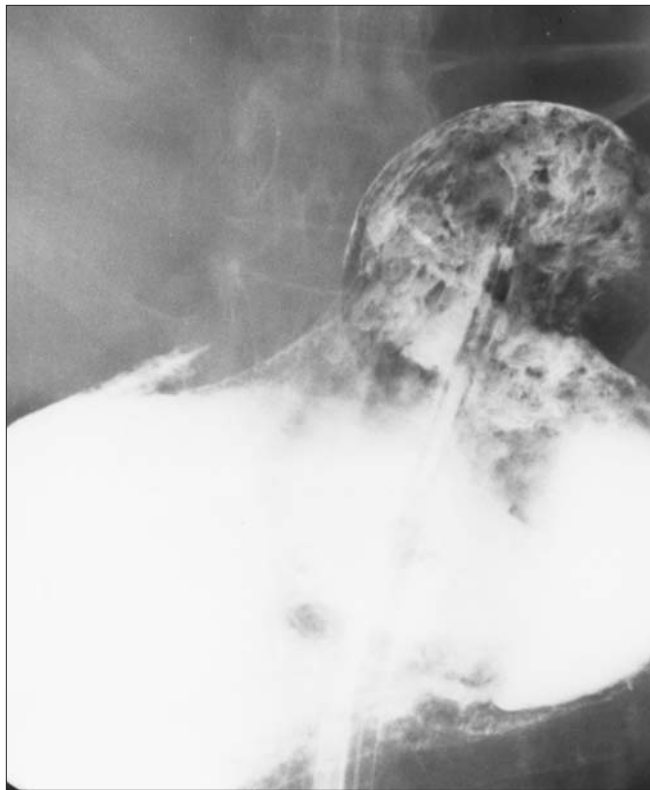

Fig. 2. Upper GI series: A large hiatus hernia is noted. The lower portion of the stomach has flipped into the thoracic cavity consistent with an organoaxial volvulus. The pylorus has a "beaked" appearance suggesting an outlet obstruction.

triad¹³ includes: 1) acute severe epigastric pain with distention; 2) vomiting followed by violent, intractable, nonproductive retching; and 3) difficulty or inability to pass a nasogastric tube into the stomach. This progression of symptoms reflects an initial pyloric obstruction followed by obstruction at the cardia and, finally, gastric distention secondary to a closed loop obstruction.

Carter⁷ reported 3 additional findings that may facilitate early diagnosis. These include: minimal abdominal findings when the stomach is completely intrathoracic; a gas-filled viscus in the lower chest or upper abdomen shown by chest x-ray; and obstruction at the site of volvulus shown by upper gastrointestinal contrast study.

The most common complications of acute volvulus are strangulation and perforation. Because of the stomach's luxuriant blood supply, strangulation occurs in only 5% to 28% of patients.⁷ Of note, most reported cases of gastric strangulation were related to a traumatic diaphragmatic hernia. Patients suffering a gastric infarction may present with gastrointestinal hemorrhage, cardiopulmonary failure or shock. Mortality is 30% to 50%^{12,14} for acute gastric volvulus and 60% if strangulation and infarction occurs.

Chronic volvulus, which accounts for $\frac{2}{3}$ of adult cases, may be asymptomatic, may be reported as an incidental finding on routine chest x-ray or upper GI series, or may present with vague, spontaneously resolving symptoms — usually nondescript upper abdominal pain. Patients may also experience dysphagia, early satiety, bloating, shortness of breath and bouts of eructation. Some patients, especially those with diaphragmatic hernias, exhibit features similar to angina pectoris, complete with ECG changes,^{14,15} and in one reported case, pyloric rotation led to common bile duct compression and obstructive jaundice.¹⁶ Because of its remitting nature, chronic gastric volvulus is easily confused with peptic ulcer disease or cholecystitis¹⁷ and may remain undiagnosed for years.

Diagnosis

Diagnosis is based on clinical suspicion and radiographic studies. Organoaxial volvulus is difficult to image, particularly if no diaphragmatic defect is present. Plain films may show a horizontally oriented stomach with a single air fluid level¹⁸ and a paucity of distal gas. An upper GI contrast study may show a low lying GE junction¹⁹ and a horizontal or inverted stomach with the cardia and pylorus at the same level.²⁰ If the pylorus is obstructed secondary to organoaxial torsion, there may be marked gastric dilatation with "beaking" of the contrast material at the site of torsion.²¹ In cases of organoaxial volvulus, plain films and contrast studies may both be falsely negative, depending on the degree of torsion.

In mesenteroaxial volvulus the stomach appears spherical on supine radiographs. Upright films often show a double air fluid level, one inferior and left, representing the normally situated fundus, and the other superior and right, representing the displaced antrum.²² Occasionally the inferior air-fluid level is located in a normal position beneath the diaphragm while the upper one (herniated antrum) lies in the retrocardiac mediastinum.²³ A helpful finding on chest x-ray is a nasogastric tube that is arrested at the GE junction secondary to obstruction. On an upper GI series, the GE junction is usually below the diaphragm, the distal portion of the stomach appears cephalad, and a “beak” may appear where the GE junction is normally located.²⁴

Treatment

Acute gastric volvulus is a surgical emergency and treatment delays lead to increased mortality. Volume resuscitation, analgesics and antiemetics should be initiated, and early gastric decompression with a nasogastric tube is advocated, although this may be difficult or impossible if the GE junction is obstructed. Aggressive attempts to advance nasogastric tubes may cause perforation, especially in children.²⁵ Non-operative therapy may be successful in selected patients, but this does not address the underlying predisposing factors that led to volvulus. Because volvulus is unpredictable, potentially catastrophic, and may recur, most authors recommend expeditious surgical intervention, with gastric decompression, reduction of the volvulus, correction of predisposing factors, and fixation of the stomach to prevent recurrence.⁶ The preferred surgical procedure is anterior gastropexy, in which the greater curvature of the stomach is affixed to the anterior abdominal wall, but if gastric necrosis has occurred, partial or total gastrectomy may be required depending on the extent of ischemic injury.¹⁷ In high risk patients, endoscopic decompression and reduction may be an option.²⁶

Conclusion

Acute gastric volvulus is a rare and often unrecognized surgical emergency that should be considered in patients who present to the ED with severe epigastric pain, nonproductive retching, and evidence of a gastric outlet obstruction — especially if there is difficulty passing a nasogastric tube. Critically ill patients and those with peritonitis should go directly to the operating room, but if time permits and the diagnosis is in doubt, an upper GI series should be requested. Currently, surgical repair remains the treatment of choice.

References

1. Tanner N. Chronic and recurrent volvulus of the stomach. *Am J Surg* 1968;115:105-9.
2. Berti A. Singolare attortigliamento de' esofago col duodeno sequita da rapida morte. *Gass Med Ital* 1866;9:139.
3. Wastell C, Ellis H. Volvulus of the stomach. *Br J Surg* 1971;58:39-45.
4. Dalgaard JB. Volvulus of the stomach. *Acta Clin Scand* 1952; 103:131-6.
5. Askew AR. Treatment of acute and chronic gastric volvulus. *Ann R Coll Surg* 1978;60:326-8.
6. Wasselle JA, Norman J. Acute gastric volvulus: pathogenesis, diagnosis and treatment. *Am J Gastroenterol* 1993;88:1780-4.
7. Carter R, Brewer LA, Hinshaw DB. Acute gastric volvulus: a study of 25 cases. *Am J Surg* 1980;140:99-106.
8. Singleton AC. Chronic gastric volvulus. *Radiology* 1940;34:53-61.
9. Milne LN, Hunter JJ. Gastric volvulus: 2 cases and review of the literature. *J Emerg Med* 1994;12:299-306.
10. Teplick G, Haskin M. *Surgical radiology*. 3rd ed. Philadelphia: W.B. Saunders; 1980. p. 482.
11. Raffin SB. *Diverticula rupture and volvulus*. 3rd ed. Philadelphia: W.B. Saunders; 1983. p. 604.
12. Samuel M, Burge DM. Gastric volvulus and associated gastroesophageal reflux. *Arch Dis Child* 1995;73:462-4.
13. Borchardt M. Zun pathologie and therapie des magnevolvulus. *Arch Klin Chir* 1904;74:243-60.
14. Haas O, Rat P. Surgical results of intrathoracic gastric volvulus complicating hiatal hernia. *Br J Surg* 1990;77:1379-81.
15. Hooper TL, Lawson R. Volvulus of the stomach, an unusual cause of pulsus paradoxus. *Postgrad Med J* 1986;62:377-9.
16. Claneza P, Salt W, Parkya E. Extrahepatic biliary obstruction complicating a diaphragmatic hiatal hernia with intrathoracic gastric volvulus. *Am J Gastroenterol* 1986;81:292-4.
17. Ellis H. Diaphragmatic hernia: a diagnostic challenge. *Postgrad Med J* 1986;62:325.
18. Cameron AE, Howard ER. Gastric volvulus in children. *J Ped Surg* 1987;22:944-7.
19. Ziprkowski MN, Littlewood Teele R. Gastric volvulus in childhood. *Am J Roentgenol* 1979;132:921-5.
20. Kilcoyne RF, Babbitt DP, Sakaguchi S. Volvulus of the stomach: a case report. *Radiology* 1972;103:157-8.
21. Gean AD, Deluca S. Acute gastric volvulus. *Am Fam Phys* 1986; 34:99.
22. Gurney JW, Olson D. The gastric bubble: roentgen observations. *Radiographs* 1989;9:467-85.
23. Menuck L. Plain film finding of gastric volvulus herniating into the chest. *Am J Roentgenology* 1976;126:1169-74.
24. Llaneza PP, Salt II WB. Gastric volvulus more common than previously thought? *Postgrad Med* 1986;80:279-88.
25. Miller DL, Pasquale MD. Gastric volvulus in the pediatric population. *Arch Surg* 1991;26:1146-9.
26. Lowenthal MN, Odes HS. Endoscopic reduction of acute gastric volvulus complicating motor neuron disease. *Isr J Med Sci* 1985; 21:552-3.

Correspondence to: Dr. William E. Sevcik, 1G1.64 WMC Health Sciences Centre, 8440 112 St., Edmonton AB T6G 2B7