

Short Communication

Dr E Rosario takes responsibility for the integrity of the content of the paper

Cite this article: Rosario E, Navaratnam AV, Ferguson M, Rennie C, Saleh HA. A feasibility study of using a high-definition intra-operative exoscope in teaching septorhinoplasty. *J Laryngol Otol* 2024;**138**:115–117. <https://doi.org/10.1017/S002221512300052X>

Received: 24 November 2022
Revised: 7 February 2023
Accepted: 25 February 2023
First published online: 23 March 2023

Keywords:

Rhinoplasty; education; technology

Corresponding author:

Eleanor Rosario;
Email: eleanor.rosario@nhs.net

A feasibility study of using a high-definition intra-operative exoscope in teaching septorhinoplasty

E Rosario , A V Navaratnam , M Ferguson, C Rennie and H A Saleh

Department of Otolaryngology, Imperial College Healthcare NHS Trust, London, UK

Abstract

Objective. This pilot study aimed to assess the feasibility of using a high-definition intra-operative exoscope in teaching septorhinoplasty.

Methods. The exoscope was used in septorhinoplasty cases with different trainers and trainees. A high-definition screen displayed real-time, magnified images. Post-procedure, a questionnaire was completed by trainer and trainees, assessing the feasibility, safety and content validity of the exoscope as a septorhinoplasty training tool.

Results. Trainees and trainers assigned favourable ratings to all aspects of the exoscope as a training tool, particularly with regard to teaching anatomy and improving visualisation.

Conclusion. The exoscope is a potentially effective training tool in septorhinoplasty, and is especially useful in improving visualisation, without restricting the operator. Annotatable intra-operative photographs and videos allow trainees to study cases outside of the operating theatre environment. The use of an exoscope for septorhinoplasty in the UK may facilitate increased hands-on involvement earlier in training than is currently typical.

Introduction

Septorhinoplasty is an essential procedure for every otolaryngology trainee to become competent in. The challenges faced by an early-years trainee in performing this procedure may result in exposure being delayed until a later stage of training. A recent study of septorhinoplasty training in the UK found that 32 per cent of trainees in their final two years were yet to complete a single septorhinoplasty procedure, with 81 per cent attending a dedicated course to advance their training.¹ In part, these difficulties pertain to the difficulty of visualising the anatomy and operative steps within a confined area. Solutions to improve visualisation, such as endoscopes, are frequently obstructive to the operator.² The risk of patient dissatisfaction with the results of septorhinoplasty means that senior support is often required until a trainee is highly proficient at this procedure.

Solutions that improve visualisation of the operative steps have the potential to vastly improve septorhinoplasty training, and potentially allow increased exposure earlier on in training. The exoscope consists of a 0° telescope, mounted externally to the patient. This is attached to a high-definition camera and light source, and is manoeuvrable in three planes. Real-time images are captured, magnified and displayed onto high-definition monitors, in 1920 × 1080 resolution, within the operating theatre.³ The external nature of the apparatus means that the operator is not restricted by the equipment. As well as improving visualisation, training is enhanced through the capture of images and videos, which can be annotated for study outside of the operating theatre.

Our pilot study aimed to assess the feasibility of utilising an exoscope to enhance septorhinoplasty training.

Materials and methods

Three septorhinoplasty cases were completed utilising the Vitom® exoscope. The operating team consisted of a trainee and a trainer, with other trainees able to observe by watching the procedure on the high-resolution monitor. The set-up is shown in Fig. 1. Examples of intra- and inter-operative photographs are shown in Figs 2 and 3 respectively.

A post-procedure Likert-style questionnaire was completed by trainees ($n = 4$) and trainers ($n = 2$), regarding the exoscope as a training tool (Table 1). Three domains were assessed using several questions. The domains were feasibility, safety and content validity. Each question was rated on a five-point scale: 1 = strongly disagree, 2 = disagree, 3 = neutral, 4 = agree and 5 = strongly agree. A global rating and free text comments were included at the end of the questionnaire, to compare use of the exoscope to traditional training methods.

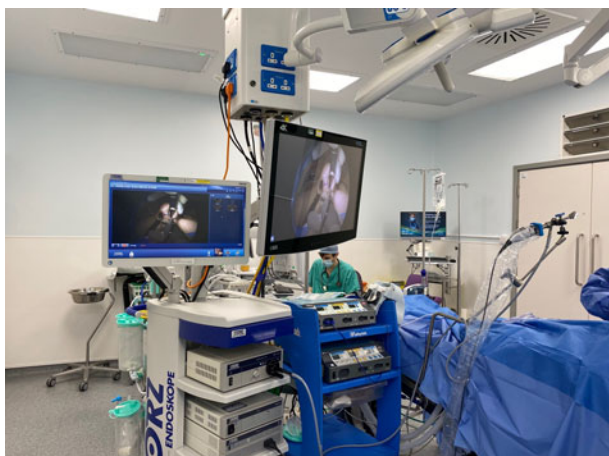

Figure 1. Operative set-up.

Results

All trainees and trainers agreed that increased exposure to septorhinoplasty would be beneficial to training.

All domains were assessed as positive by trainees and trainers, each receiving a mean Likert score of 4 or higher (Table 2). The highest scoring domain was ‘safety as a training tool’, at 4.5.

The only individual question that did not receive a mean score of 4 or higher related to the ease of set-up.

Participants noted in the free text comments that there was superior visualisation of anatomy and surgical techniques, and that it was possible to appreciate operative steps when not scrubbed. It was also noted that it was sometimes difficult to visualise the osteotomies, because of difficulty moving the exoscope directly overhead.

Discussion

Difficulties in visualising the operative field during septorhinoplasty complicate the learning of this procedure. Trainees may only fully appreciate certain operative steps when performing them for the first time, and trainers are often limited to describing the steps without access to full visualisation. Endoscopic techniques have been demonstrated to improve trainee visualisation for the septoplasty portion of a septorhinoplasty procedure; however, endoscopes must be handled by a member of the operating team within the small operative field.⁴ Operative manoeuvres are therefore restricted, because one hand is needed to operate the endoscope.²

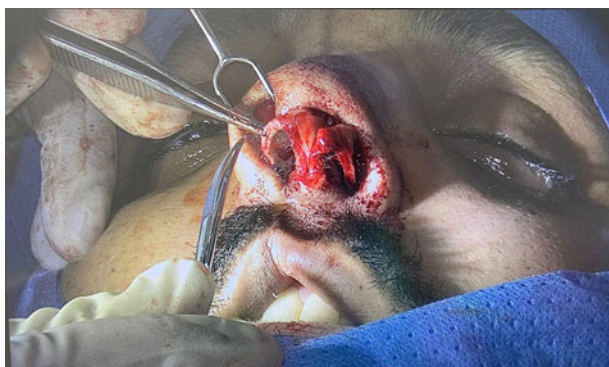

Figure 2. Intra-operative view.

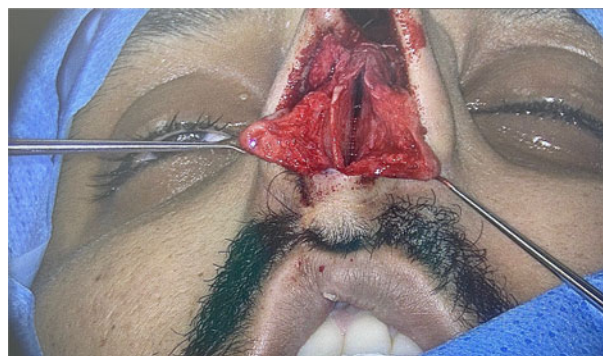


Figure 3. Intra-operative view.

Our pilot study data demonstrate that the use of a high-resolution exoscope is beneficial to both trainees and trainers in teaching anatomy and visualising the procedure. An exoscope allows trainees to fully visualise trainers performing operative steps, and allows trainers to point out important anatomy and techniques on the screen. The exoscope is mounted externally to the patient and provides views of the entire operative field. Any required adjustments can be made easily by a non-operating theatre team member, who does not need to be surgically trained. Operations may be recorded and used for trainees to study outside of the operating theatre.

In 2021, Kadaba *et al.* described the use of an exoscope in oculoplastic surgery education, particularly the benefits to trainees in visualising key surgical anatomy and steps.⁵

Table 1. Post-procedure questionnaire

Increased exposure to septorhinoplasty would be beneficial to training	1 = Strongly disagree 2 = Disagree 3 = Neutral 4 = Agree 5 = Strongly agree
Feasibility as a training tool	Easy to set up
	Easy to adjust during surgery
	Unobtrusive to work flow
	Aware of progress of procedure
Safety as a training tool	Reliable
	Sufficient image resolution
	No safety concerns
	Improved quality of patient care
	Improved visualisation over traditional approach
Content validity as a training tool	Teach anatomy
	Teach surgical planning
	Effective as a guidance tool
	Give feedback to trainee
	Communication with trainee
	Access to videos outside theatre would be helpful in training
	Overall training tool
Global rating	Include in training
	Would use recorded videos in own time
	Recommend to colleague

Table 2. Median questionnaire scores

Question	Median score (out of 5)
Increased exposure to septorhinoplasty would be beneficial to training	5.0
Feasibility as a training tool	4.0
Safety as a training tool	4.5
Content validity as a training tool	4.0
Global rating	4.0

In addition, intra-operative photographs and videos, which can be annotated, allow trainees to study operative cases outside of the operating theatre environment.⁵ Those authors also noted an improvement to operative flow, as the whole theatre team could follow the procedure and anticipate equipment needs.⁵ This is also applicable to septorhinoplasty, and has the potential to improve operating theatre efficiency.

The use of an exoscope has also been described in neuro-, plastic and paediatric surgical teaching, along with other areas of otolaryngology such as microlaryngoscopy and thyroid surgery.^{5–7} The educational potential has been reported for rhinoplasty in both Italy and the USA, especially with regard to the benefits of magnification.^{2,8}

A particular advantage noted when using the exoscope in microlaryngoscopy, oculoplastic surgery, and head and neck free-flap surgery was the improved operative visualisation and learning for trainees who were not scrubbed.^{5,7,9} The main disadvantage noted was the reduced high-definition capacity of the exoscope when working in deeper planes (more than 2.5 cm),⁵ although this was not consistent with reports in thyroid surgery where the exoscope was reported as being effective up to 10 cm depth.⁶

A further advantage noted in thyroid surgery was the potential for telesurgery or telementoring, particularly in the context of the coronavirus disease 2019 pandemic.⁶

Our study did not raise any safety concerns with regard to utilising an exoscope, and in fact this was identified as an area of excellence within the questionnaire. Concerns were raised surrounding ease of use, and if an exoscope were to be formally introduced, training in its use would need to be established in otolaryngology theatres.

Limitations

This was a small study, so we were unable to perform meaningful statistical analysis on our questionnaire data. Further assessment with more trainees and trainers would be helpful

to establish the utility of the exoscope in septorhinoplasty training. It was difficult to obtain the exoscope for all septoplasty procedures, as only one exoscope was available in the Trust. For this small pilot study, we were able to obtain consent for the use of images from individual patients; however, on a larger scale, a formal process would need to be established for this.

Conclusion

Our pilot study demonstrates that an exoscope is beneficial in septorhinoplasty training, particularly with regard to visualising operative steps and appreciating key anatomy. It is also a safe technology to use within the operating theatre. In order to establish use, theatre teams and trainees would require training in the operation of the equipment. The use of an exoscope for septorhinoplasty in the UK may facilitate increased hands-on involvement earlier in training than is currently typical.

Acknowledgement. The authors would like to thank Jörn Sonnabend, Senior Product Specialist – Upper Endoscopy, Karl Storz Endoscopy (UK) Ltd, who kindly assisted in the set-up and smooth running of the exoscope during the first use.

Competing interests. None declared

References

- Oremule B, Khwaja S, Saleh HA. Overcoming challenges in septorhinoplasty training faced by UK otorhinolaryngology trainees. *Bull R Coll Surg Engl* 2021;**103**:212–17
- Tasca I, Ceroni Compadretti G, Romano C. High-definition video telescopic rhinoplasty. *Acta Otorhinolaryngol Ital* 2016;**36**:496–8
- Karl Storz – Endoskope. VITOM 3D. In: <https://www.karlstorz.com/us/en/product-detail-page.htm?cat=1000160546&productID=1000082890> [6 August 2023]
- Ali YH, Alandejani T. Rhinoplasty assisted by endoscopic septoplasty: precise job and an educational tool. *J Craniofac Surg* 2020;**31**:847–50
- Kadaba V, Shafi F, Ahluwalia HS. The VITOM® exoscope in oculoplastic surgery: the 5 year Coventry experience. *Eye* 2021;**35**:3137–40
- Kullar P, Tanna R, Ally M, Vijendren A, Mochloulis G. VITOM 4K 3D exoscope: a preliminary experience in thyroid surgery. *Cureus* 2021;**13**:e12694
- De Virgilio A, Costantino A, Mondello T, Conti V, Pirola F, Russo E *et al.* Pre-clinical experience with the VITOM 3D and the ARTip Cruise System for micro-laryngeal surgery. *Laryngoscope* 2021;**131**:136–8
- Hakimi AA, Merna C, Wong BJF. Evaluation of a high-definition intraoperative exoscope in rhinoplasty education and workflow. *Facial Plast Surg Aesthet Med* 2021;**23**:144–5
- De Virgilio A, Mercante G, Gaino F, Yiu P, Mondello T, Malvezzi L *et al.* Preliminary clinical experience with the 4 K3-dimensional microvideoscope (VITOM 3D) system for free flap head and neck reconstruction. *Head Neck* 2020;**42**:138–40