



## Letter to the Editor: New Observation

# Recessive Pathogenic *GMPPB* Variants Cause a Childhood Onset Myasthenic Syndrome Responsive to Pyridostigmine

Gordon Jewett<sup>1,2,\*</sup> , Benjamin Beland<sup>1,\*</sup>, Shahin Khayambashi<sup>3</sup>, Sarah Silverstein<sup>4,5</sup>, Sandra Donkervoort<sup>5</sup>, Carsten G. Bönnemann<sup>5</sup>, Gerald Pfeffer<sup>1,2</sup>  and Sameer Chhibber<sup>1</sup>

<sup>1</sup>Department of Clinical Neurosciences, Cumming School of Medicine, University of Calgary, Calgary, AB, Canada, <sup>2</sup>Hotchkiss Brain Institute, Cumming School of Medicine, University of Calgary, Calgary, AB, Canada, <sup>3</sup>Department of Internal Medicine, Division of Neurology, University of British Columbia, Vancouver, BC, Canada, <sup>4</sup>Rutgers New Jersey Medical School, Newark, NJ, USA and <sup>5</sup>Neuromuscular and Neurogenetic Disorders of Childhood Section, National Institute of Neurological Disorders and Stroke, National Institutes of Health, Bethesda, MD, USA

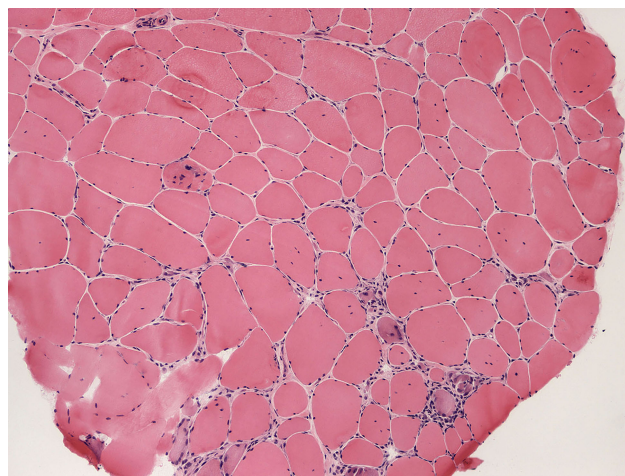
**Keywords:** GMPPB; muscular dystrophy; pyridostigmine; congenital myasthenic syndrome

A 35-year-old female of European descent was referred for longstanding myalgias, symmetrical limb-girdle weakness, and chronic creatinine kinase (CK) elevation. She had a history of uncomplicated gestation with term birth and normal early gross motor development. At age 5 years, she was described as an “awkward runner” and she experienced increasing difficulty with sports. Family history was noncontributory and there was no known consanguinity.

At age 21 years she presented to rheumatology with severe myalgias and CK elevation (1000–3000 U/L, normal < 200 U/L). Needle electromyography (EMG) revealed an irritable myopathy affecting shoulder and hip girdle muscles. Fatigable weakness was not detected and electrodiagnostic testing to identify neuromuscular transmission deficits was not performed. She was treated with prednisone and azathioprine for 2-years without benefit. Progressive weakness and persistently elevated CK prompted a left vastus lateralis biopsy suggestive of chronic myopathy without inflammation (Fig. 1). Over 7 years, severe myalgias continued, leading to opioid dependence, and she was dependent for many activities of daily living. Myalgias spontaneously resolved in her early 30s, briefly recurring during pregnancy that was carried to term without complication.

Examination at 35 years of age revealed generalized small muscle bulk, mild paraspinal and rhomboid atrophy with symmetrical lateral winging of the scapula, and no calf hypertrophy. She had a high-arched palate, joint laxity in the hands, and no contractures. There was no diplopia, ptosis, or facial weakness. She had a limb-girdle pattern of weakness (Table 1a). Reflexes were 2+ throughout. Clinical fatigability was not noted but was not specifically assessed.

Whole exome sequencing (WES) revealed compound heterozygous variants in *GMPPB* (GenBank: NM\_021971.4; OMIM: 615320) encoding GDP-Mannose Pyrophosphorylase B, a c.79G > C; p. Asp27His, and a c.95C > T; p. Pro32Leu missense



**Figure 1:** Left vastus lateralis biopsy (hematoxylin and eosin stain) demonstrated endomysial fibrous connective tissue, internalized nuclei, fiber size variability, degenerating and regenerating fibers, and hypercontracted and small rounded fibers. There was no necrosis or significant inflammation. Dystrophin and sarcoglycan staining were normal (not shown), and alpha-dystroglycan staining was not pursued. Photo courtesy of Dr. Geoffrey Joseph, University of Calgary.

variant. Both variants are classified as pathogenic in ClinVar (accessed Oct 17, 2022). The c.79G > C variant has been associated with a limb-girdle muscular dystrophy (LGMD) phenotype, often mild, in at least 38 individuals, and overlapping myasthenic syndrome phenotype with neuromuscular junction instability in at least 19 individuals.<sup>1–8</sup> The c.95C > T variant has been associated with LGMD and congenital muscular dystrophy phenotypes in at least nine individuals, and overlapping myasthenic syndrome phenotype in at least three individuals (two of them also with concurrent trans c.79G > C variant).<sup>1,5</sup> Segregation of variants in the

**Corresponding author:** G. Jewett; Email: [gjewett@ucalgary.ca](mailto:gjewett@ucalgary.ca)

\*Gordon Jewett and Benjamin Beland contributed equally to this work.

**Cite this article:** Jewett G, Beland B, Khayambashi S, Silverstein S, Donkervoort S, Bönnemann CG, Pfeffer G, and Chhibber S. (2024) Recessive Pathogenic *GMPPB* Variants Cause a Childhood Onset Myasthenic Syndrome Responsive to Pyridostigmine. *The Canadian Journal of Neurological Sciences* 51: 595–597, <https://doi.org/10.1017/cjn.2023.277>

© The Author(s), 2023. Published by Cambridge University Press on behalf of Canadian Neurological Sciences Federation. This is an Open Access article, distributed under the terms of the Creative Commons Attribution licence (<http://creativecommons.org/licenses/by/4.0/>), which permits unrestricted re-use, distribution and reproduction, provided the original article is properly cited.

**Table 1:** Motor examination (A) pre- and (B) post-treatment with pyridostigmine, and (C) after 7 years with ongoing treatment (Medical research council graded power out of 5)

Muscle	Pretreatment (A)		Post-treatment (B)		After 7-years treated (C)	
	Right	Left	Right	Left	Right	Left
Neck flexion	4		5		5	
Shoulder abduction/external rotation	4	4	5	5	4+ (fatigable)	4+ (fatigable)
Elbow flexion/extension	4+	4+	5	5	5	5
Distal arms	5	5	5	5	5	5
Hip flexion	4-	4-	5	5	4+ (fatigable)	4+ (fatigable)
Hip extension/adduction	4	4	5	5	4+	4+
Hip abduction	3	2	4	4	4+	4+
Knee flexion	4-	4-	5	5	5	5
Knee extension	5	5	5	5	5	5
Ankle dorsiflexion	4-	4-	5	5	5	5
Ankle plantarflexion	5	5	5	5	5	5

parents was not performed, however, the variants did not appear on the same reads on binary alignment map files, indicating that the variants are in trans (biallelic inheritance). Other variants identified with WES, largely classified as of uncertain significance in ClinVar, did not explain the patient's phenotype. She was diagnosed with genetically confirmed *GMPPB*-related LGMD.

Based on reports of neuromuscular transmission deficits in a subset of patients with *GMPPB* LGMD, 3 Hz repetitive nerve stimulation (RNS) in the left accessory – trapezius nerve muscle pair was pursued, which revealed compound muscle action potential (CMAP) amplitude decrement of 26.9% with post-exercise repair. There was no decrement in ulnar – adductor digiti minimi or facial – nasalis nerve muscle pairs. There was no post-exercise facilitation of CMAP amplitudes to indicate presynaptic dysfunction.

Pyridostigmine 60 mg four times daily resulted in dramatic improvement, with mild weakness only in hip abduction that was not functionally limiting at 6-month follow-up (Table 1b). After 7 years, her response to pyridostigmine remains robust. Creatinine kinase elevation is persistent (1000–3000 U/L). She has slowly progressive limb-girdle weakness with no distal weakness (Table 1c). There is clinically detectable fatigable weakness in shoulder abduction and hip flexion. There is mild subjective benefit from 3,4-diaminopyridine 15 mg three times daily. A trial of salbutamol was not tolerated due to symptomatic tachycardia.

LGMD is a heterogenous group of inherited muscle disorders, including the  $\alpha$ -dystroglycanopathy subgroup characterized by abnormal  $\alpha$ -dystroglycan glycosylation.<sup>9</sup> Pathogenic recessive *GMPPB* variation causes an  $\alpha$ -dystroglycanopathy associated with a spectrum of disease ranging from an adult-onset LGMD to a severe congenital myopathy with structural brain and eye involvement.<sup>10</sup> Based on the role of *GMPPB* in *N*-glycosylation of acetylcholine receptors, neuromuscular transmission deficits have been identified in a subset of patients resulting in a myasthenic syndrome phenotype.<sup>2,11</sup> This opens exciting avenues for symptomatic NMJ-targeted treatment.<sup>2</sup> Additionally, neuromuscular transmission defects may be seen in other inherited myopathies, such as those associated with pathogenic variants in *BIN1*, *DES*, *DNM2*, *MTM1*, *PLEC*, *DMPK*, *CLCN1*, or *SCN4A*, so recognition of decremental response to RNS can narrow and aid in molecular diagnosis.<sup>12</sup>

The patient we describe is typical of *GMPPB* myasthenic syndrome, characterized by lower extremity predominant limb-girdle weakness in early adulthood and mild gross motor impairment in the first decade of life. Ocular, bulbar, and distal extremity weakness are rare. Fatigable weakness is not prominent on examination<sup>3</sup> but patients describe deterioration with activity and improvement with rest.<sup>2</sup> The severe pain experienced by our patient is atypical, but lower extremity myalgias and cramps are reported in about half of cases. Weakness is gradually progressive, often marked by deterioration during infection and other stressors, as seen during pregnancy in this case.<sup>3</sup>

RNS and/or single fiber EMG demonstrate NMJ deficits in proximal muscles but not typically distal or cranial muscles. CMAP amplitude increment after exercise or high-frequency RNS is uncommon, reflecting post-synaptic pathology with minimal presynaptic involvement. Marked CK elevation, biopsy evidence of muscular dystrophy, and myopathic features on needle EMG reflect unanimous overlap with muscle disease.<sup>3</sup> Sustained improvement in strength and function occurs in the majority of patients treated with pyridostigmine and can be profound.<sup>2,3,11</sup> Additional benefit from 3,4-diaminopyridine and/or salbutamol is described in some patients.<sup>2,3,13</sup>

This case highlights the importance of objective assessment for neuromuscular transmission defects in all patients with an LGMD phenotype to avoid diagnostic and treatment delays. In particular, all patients with pathogenic *GMPPB* variants should be investigated for NMJ dysfunction if not previously performed. We advocate for an empiric trial of pyridostigmine in all patients with *GMPPB* LGMD given the low risk and significant potential benefit.

**Acknowledgments.** We thank the patient for her willingness to publish her case.

We confirm that we have read the Journal's position on issues involved in ethical publication and affirm that this report is consistent with those guidelines.

**Author contribution.** GJ, BB, CB, SD, GP, and SC contributed to study conceptualization and design, analysis and interpretation of results, and drafting, reviewing, and editing of the manuscript. SK contributed to study conceptualization and design, and reviewing and editing of the manuscript. SS contributed to analysis and interpretation of results and reviewing and editing of the manuscript. All authors reviewed the results and approved the final version of the manuscript.

**Funding.** Gordon Jewett has received salary support from ALS Canada; he has received research support from the Canadian Institutes of Health Research; and he has served on medical advisory boards for Amylyx Pharmaceuticals.

Shahin Khayambashi has received honoraria from Alnylam Pharmaceuticals.

Carsten G. Bönneman has received research support from Muscular Dystrophy UK and NOELIA foundation; he has received support to attend meetings from the Peripheral Nerve Society and DGM; he has a patent pending for methods to diagnose and treat COL6-related disorders (US Appl No. 16/315,278); he has served on medical advisory boards for Nationwide Children's Hospital, Abeona Therapeutics, and Rockett Pharmaceuticals; and he has served on scientific advisory boards for the RYR1 foundation, Muscular Dystrophy UK Oxford Neuromuscular Centre, NeuroMyoAlp Lyon, Sarepta Therapeutics, and iThera Medical.

Gerald Pfeffer has received research support from the Canadian Institutes of Health Research, International Development Research Centre, Muscular Dystrophy Canada, and Kennedy's Disease Association; he has served on medical advisory boards for ALS Canada, Muscular Dystrophy Canada, Ataxia Canada, and CureVCP.

Sameer Chhibber has received honoraria from Alnylam Pharmaceuticals, Amylyx Pharmaceuticals, and Argenix; he has served on medical advisory boards for Alnylam Pharmaceuticals and Argenix.

**Competing interests.** None.

## References

1. Chompoopong P, Milone M. GDP-mannose pyrophosphorylase B (GMPPB)-related disorders. *Genes (Basel)*. 2023;14:372. DOI: [10.3390/genes14020372](https://doi.org/10.3390/genes14020372).
2. Belaya K, Rodríguez Cruz PM, Liu WW, et al. Mutations in GMPPB cause congenital myasthenic syndrome and bridge myasthenic disorders with dystroglycanopathies. *Brain*. 2015;138:2493–504. DOI: [10.1093/brain/awv185](https://doi.org/10.1093/brain/awv185).
3. Rodríguez Cruz PM, Belaya K, Basiri K, et al. Clinical features of the myasthenic syndrome arising from mutations in GMPPB. *J Neurol Neurosurg Psychiatry*. 2016;87:802–9. DOI: [10.1136/jnnp-2016-313163](https://doi.org/10.1136/jnnp-2016-313163).
4. Krenn M, Sener M, Rath J, et al. The clinical and molecular landscape of congenital myasthenic syndromes in Austria: a nationwide study. *J Neurol*. 2023;270:909–16. DOI: [10.1007/s00415-022-11440-0](https://doi.org/10.1007/s00415-022-11440-0).
5. Cabrera-Serrano M, Ghaoui R, Ravenscroft G, et al. Expanding the phenotype of GMPPB mutations. *Brain*. 2015;138:836–44. DOI: [10.1093/brain/awv013](https://doi.org/10.1093/brain/awv013).
6. Oestergaard ST, Stojkovic T, Dahlqvist JR, et al. Muscle involvement in limb-girdle muscular dystrophy with GMPPB deficiency (LGMD2T). *Neurol Genet*. 2016;2:e112. DOI: [10.1212/NXG.0000000000000112](https://doi.org/10.1212/NXG.0000000000000112).
7. Montagnese F, Klupp E, Karampinos DC, et al. Two patients with GMPPB mutation: the overlapping phenotypes of limb-girdle myasthenic syndrome and limb-girdle muscular dystrophy dystroglycanopathy. *Muscle Nerve*. 2017;56:334–40. DOI: [10.1002/mus.25485](https://doi.org/10.1002/mus.25485).
8. Gonzalez-Perez P, Smith C, Sebetka WL, Gedlinske A, Perlman S, Mathews KD. Clinical and electrophysiological evaluation of myasthenic features in an alpha-dystroglycanopathy cohort (FKRP-predominant). *Neuromuscul Disord*. 2020;30:213–8. DOI: [10.1016/j.nmd.2020.01.002](https://doi.org/10.1016/j.nmd.2020.01.002).
9. Liewluck T, Milone M. Untangling the complexity of limb-girdle muscular dystrophies. *Muscle Nerve*. 2018;58:167–77. DOI: [10.1002/mus.26077](https://doi.org/10.1002/mus.26077).
10. Carss KJ, Stevens E, Foley AR, et al. Mutations in GDP-mannose pyrophosphorylase B cause congenital and limb-girdle muscular dystrophies associated with hypoglycosylation of  $\alpha$ -dystroglycan. *Am J Hum Genet*. 2013;93:29–41. DOI: [10.1016/j.ajhg.2013.05.009](https://doi.org/10.1016/j.ajhg.2013.05.009).
11. Bobadilla-Quesada EJ, Natera-de Benito D, Carrera-García L, et al. Early and long-term effect of the treatment with pyridostigmine in patients with GMPPB-related congenital myasthenic syndrome. *Neuromuscul Disord*. 2020;30:719–26. DOI: [10.1016/j.nmd.2020.07.009](https://doi.org/10.1016/j.nmd.2020.07.009).
12. Nicolau S, Kao JC, Liewluck T. Trouble at the junction: when myopathy and myasthenia overlap. *Muscle Nerve*. 2019;60:648–57. DOI: [10.1002/mus.26676](https://doi.org/10.1002/mus.26676).
13. Thompson R, Bonne G, Missier P, Lochmüller H. Targeted therapies for congenital myasthenic syndromes: systematic review and steps towards a treatatolome. *Emerg Top Life Sci*. 2019;3:19–37. DOI: [10.1042/ETLS20180100](https://doi.org/10.1042/ETLS20180100).