

CANADIAN ASSOCIATION OF NEUROSCIENCE REVIEW: Respiratory Control and Behavior in Humans: Lessons from Imaging and Experiments of Nature

Immanuela Ravé Moss

ABSTRACT: The purpose of this review is to demonstrate that respiration is a complex behavior comprising both brainstem autonomic control and supramedullary influences, including volition. Whereas some fundamental mechanisms had to be established using animal models, this review focuses on clinical cases and physiological studies in humans to illustrate normal and abnormal respiratory behavior. To summarize, central respiratory drive is generated in the rostroventrolateral medulla, and transmitted to both the upper airway and to the main and accessory respiratory muscles. Afferent feedback is provided from lung and muscle mechanoreceptors, peripheral carotid and aortic chemoreceptors, and multiple central chemoreceptors. Supramedullary regions, including cortex and subcortex, modulate or initiate breathing with volition, emotion and at the onset of exercise. Autonomic breathing control can be perturbed by brainstem pathology including space occupying lesions, compression, congenital central hypoventilation syndrome and sudden infant death syndrome. Sleep-wake states are important in regulating breathing. Thus, respiratory control abnormalities are most often evident during sleep, or during transition from sleep to wakefulness. Previously undiagnosed structural brainstem pathology may be revealed by abnormal breathing during sleep. Ondine's curse and 'the locked-in syndrome' serve to distinguish brainstem from supramedullary regulatory mechanisms in humans: The former comprises loss of autonomic respiratory control and requires volitional breathing for survival, and the latter entails loss of corticospinal or corticobulbar tracts required for volitional breathing, but preserves autonomic respiratory control.

RÉSUMÉ: Contrôle et comportement respiratoire chez l'humain : leçons tirées de l'imagerie et des expériences naturelles. Le but de cette revue est de démontrer que la respiration est un acte complexe impliquant un contrôle neuro-végétatif provenant du tronc cérébral et des influences supramédullaires, entre autres la volonté. Alors que les mécanismes fondamentaux ont dû être établis grâce à des modèles animaux, cette revue est axée sur des cas cliniques et des études physiologiques chez l'humain afin d'illustrer le comportement respiratoire normal et anormal. En résumé, la stimulation respiratoire centrale origine de la moelle rostro-ventro-latérale et elle est transmise aux voies aériennes supérieures et aux muscles respiratoires principaux et accessoires. La rétroaction afférente provient de mécanorécepteurs pulmonaires et musculaires, de chémorécepteurs périphériques à la carotide et à l'aorte et de multiples chémorécepteurs centraux. Des régions supramédullaires corticales et sous-corticales jouent un rôle dans la modulation ou le déclenchement de la respiration par la volonté, l'émotion et en début d'exercice. Le contrôle neuro-végétatif de la respiration peut être perturbé par une pathologie du tronc cérébral, soit par une lésion expansive, une compression, le syndrome congénital d'hypoventilation alvéolaire central et le syndrome de la mort subite du nourrisson. Les états de sommeil et d'éveil sont importants dans la régulation de la respiration. Des anomalies du contrôle respiratoire sont plus souvent évidentes pendant le sommeil ou pendant la période de transition du sommeil à l'éveil. Une respiration anormale pendant le sommeil peut révéler une pathologie structurale du tronc cérébral encore non détectée. Le syndrome d'Ondine et le syndrome de déafférentation motrice (*locked-in syndrome*) distinguent les mécanismes régulateurs du tronc cérébral des mécanismes supramédullaires chez l'humain: les premiers comportent une perte du contrôle respiratoire neuro-végétatif et la survie dépend alors de la respiration volontaire et les derniers impliquent la perte des voies corticospinales ou corticobulbaires nécessaires à la respiration volontaire, mais préservent le contrôle respiratoire neurovégétatif.

Can. J. Neurol. Sci. 2005; 32: 287-297

The concept behind this article is that respiration is not just an automatic function. Rather, it is a complex behavior that is controlled at many brain levels and structures, some autonomic and others voluntary. This article will offer a review of the organization of respiratory control and its special features as gleaned from work in animals, and from relatively recent studies in humans using updated imaging techniques. The importance of the brainstem in autonomic respiratory control, of sleep-wake states in modulating respiration, and of supramedullary regulation of breathing during volition, with emotion, and at the

onset of exercise hyperpnea will be emphasized. Clinical cases will be described, including space occupying lesions in the

From the Departments of Pediatrics and Physiology, McGill University and McGill University Health Centre Research Institute, Montreal Children's Hospital and Montreal Children's Hospital Research Institute, Montreal, Quebec, Canada

RECEIVED OCTOBER 25, 2004. ACCEPTED IN FINAL FORM JANUARY 28, 2005

Reprint requests to: Immanuela Ravé Moss, Departments of Pediatrics and Physiology, McGill University, The Montreal Children's Hospital, Room A-707, 2300 Tupper Street, Montreal, QC H3H 1P3 Canada

brainstem, cervicomedullary compression and myelomeningocele, congenital hypoventilation and sudden infant death syndromes, obstructive sleep apnea, and Ondine's curse as well as the 'locked-in syndrome'. These cases will serve to illustrate how pathology in various brain regions can provide information on the importance of specific structures for normal respiratory function in humans.

A case history showing the importance of the brainstem for normal breathing

The crucial role of the brainstem in normal respiratory control can be illustrated by the case history of Mr. MDC (courtesy Dr. Rolando Del Maestro, Department of Neurosurgery, Montreal Neurological Institute, McGill University). At thirteen years of age, because of symptoms of increased intracranial pressure, this patient was diagnosed as having an invasive ependymoma, both in the fourth ventricle and in the posterior fossa. The tumor was partially removed and the region irradiated. The patient was lost

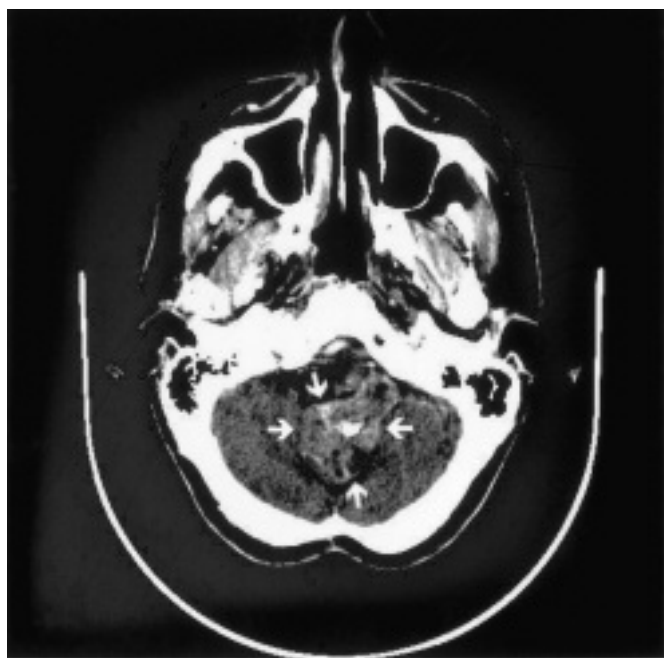


Figure 1: A CT scan of the medulla of Mr. MDC. The medulla, indicated by the arrows, is distorted and is circumscribed and infiltrated by fibrotic tissue, likely resulting from the irradiation this patient received for his original tumor (courtesy Dr. R Del Maestro, Brain Tumour Research Centre, Montreal Neurological Institute, McGill University Health Centre).

to follow-up until recently, when, at the age of forty-five, due to recurring motor problems, he was discovered to have extensive gliosis and fibrosis in and around the brainstem (Figure 1).

While hospitalized, respiratory gas monitoring showed severe hypoxemia and hypercarbia, especially during sleep. These were easily alleviated with mechanical ventilation. Indeed, on one occasion, the patient refused artificial ventilation, resulting in worsening of his respiratory status to the point of

coma, at which point artificial ventilation again corrected the respiratory gases and the state of consciousness. This sequence indicated that the underlying pathology of these respiratory findings was, at least in part, due to central alveolar hypoventilation, that is, to an inability of respiratory control mechanisms in the brainstem to adequately regulate breathing so as to ensure chemical homeostasis.

The organization of respiratory control: Brief review

To explain this patient's clinical respiratory findings, a review of the organization of respiratory control is in order.

First, autonomic respiration is controlled in the brainstem¹ (Figure 2A). Current concepts indicate that the predominant, if perhaps not exclusive, origin of the drive to breathe emanates from a relatively small region in the rostral ventrolateral medulla named the preBötzinger complex.² This region in the *in vitro* preparation of the neonatal rat comprises ~ 600 neurons. Of these neurons, the crucial ones are those that display an inherent inspiratory oscillatory activity and that can be identified by being endowed with both neurokinin-1 and mu-opioid receptors (the endogenous peptides of which include substance P and endomorphin-1 and endomorphin-2). Whereas, for several years after its discovery, the preBötzinger complex was considered the sole 'kernel' of central respiratory drive, recent studies have questioned its exclusive role, and have added neighboring neuronal networks, including neurons with pre-inspiratory activity, to the overall model of how central respiratory activity is generated.² It is important to emphasize that, whereas neuronal structures and connections have been defined in some detail from animal studies, it is highly likely that these are fundamentally similar in all mammalian species, including man, although the relative size and location of various components may vary among species.^{3,4}

Respiratory drive is transmitted via cranial motor nuclei, such as the vagus and hypoglossus, and via the ventral respiratory neuronal group and bulbospinal pathways to upper airway, diaphragmatic, intercostal and accessory respiratory muscles⁵ (Figure 2B). The feedback loop for this autonomic respiratory drive is completed by afferent stimuli from mechanoreceptors in the lung and respiratory muscles, and from O₂ and CO₂ chemoreceptors. With regard to the chemoreceptors, it is currently believed that, in addition to their peripheral locations, their central distribution is extensive.² This newer concept will become important as we try to explain the symptoms seen in the patient described above. Other structures in the brainstem also participate in autonomic respiratory control, including the solitary tract nucleus in the dorsal brainstem that is important for the integration of sensory autonomic information, the pontine parabrachial nuclei that participate in respiratory timing, and the sleep-wake-related gigantocellular, medullary raphé, lateral reticular, and locus coeruleus nuclei^{1,2,5,6} (Figure 2A).

Respiration is also regulated by many structures outside the brainstem. There is mounting evidence that extramedullary regions, such as several hypothalamic nuclei and the cerebellar fastigial nucleus, also modulate breathing.² Respiration is also under volitional control emanating from several cortical motor regions and operating via corticospinal pathways that are analogous to those of any other motor function.⁷

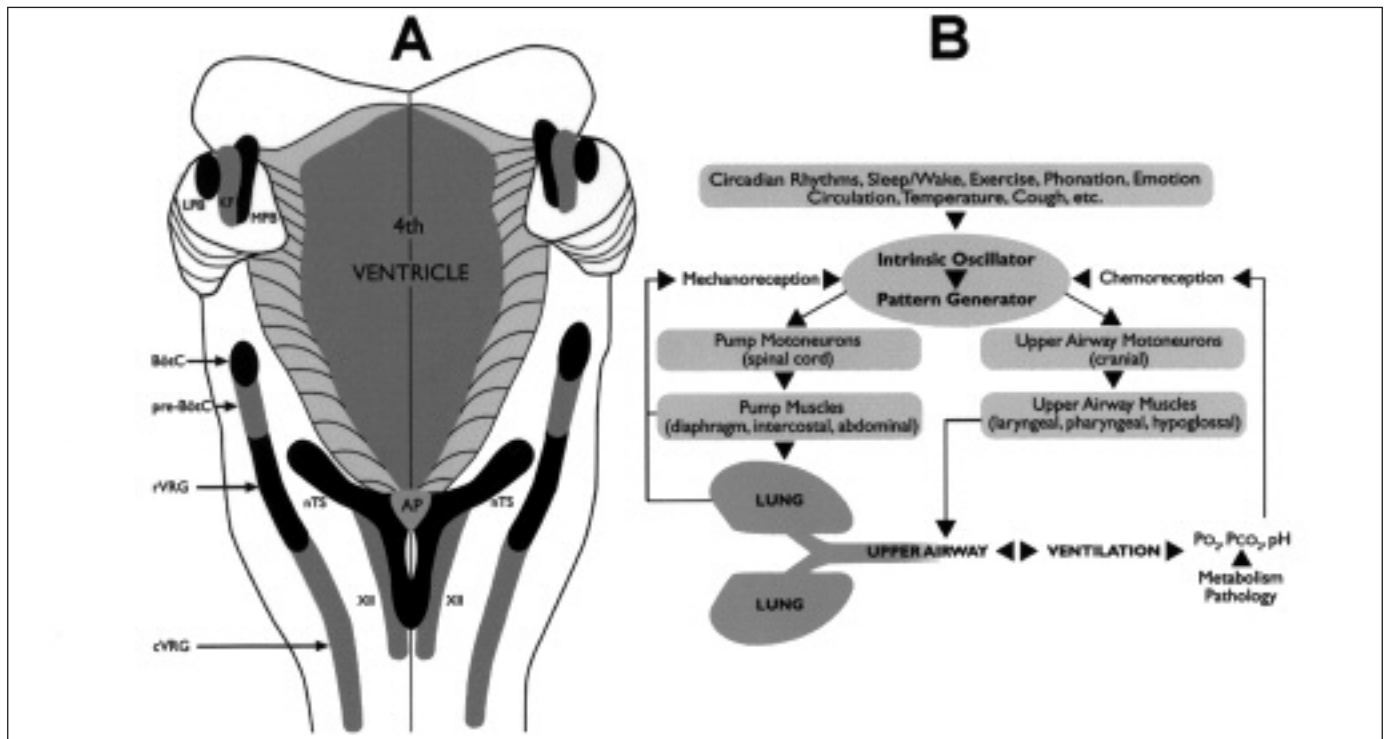


Figure 2A: The brainstem in respiratory control. This figure shows a schematic representation of a dorsal view of the pons and medulla (cerebellum removed). The major brainstem respiratory regions, from rostral to caudal, are (1) In the pons: PRG = Pontine respiratory group, including LPB = lateral parabrachial nucleus, MPB = medial parabrachial nucleus, and KF = Kölliker-Fuse nucleus, and (2) In the medulla: The paraambigular BötzC = Bötzinger complex; pre-BötC = pre-Bötzinger complex; rVRG = rostral ventral respiratory group; cVRG = caudal ventral respiratory group, and the solitary tract nucleus-related (MTS) dorsal respiratory group. Additional abbreviations: AP = area postrema; nTS = solitary tract nucleus; XII = hypoglossal nucleus (modified from¹).

Figure 2B: A schema of the organization of respiratory control, showing the pattern generator for central respiratory drive, efferent and afferent pathways, and supramedullary influences on breathing behavior (modified from⁵).

Finally, it is important to emphasize the overwhelming influence of behavioral or sleep-wake states on breathing, including the ability during wakefulness to override autonomic respiratory reflexes, the relative insensitivity of such reflexes during rapid eye movement (REM) sleep, and the total dependence of gaseous chemical homeostasis on respiratory reflexes during non REM sleep. A conceptual schema that shows the interrelationships among the many components of respiratory control is shown in Figure 2B.

Physiologic explanation of this patient's respiratory status

Returning to Mr. MDC, his recent computed tomography scan shows that much of his medullary circumference and portions of the solitary and hypoglossal nuclei are invaded by dense connective tissue, presumably, at least in part, a result of irradiation treatment for his tumor. As central CO_2 chemoreception occurs at and beneath the ventral medullary surface and at additional medullary regions, including the solitary tract nucleus, it is not surprising that CO_2 homeostasis in this patient was very much affected. The biggest effect was seen during sleep, when chemical respiratory homeostasis is dependent on autonomic respiratory control. Following the three successive nights without ventilatory support, the disturbed CO_2

homeostasis was manifested by an arterial P_{CO_2} of 120-130 Torr. It was at that P_{CO_2} level that the patient was comatose due to CO_2 narcosis. During daytime hours in that time period, cortical and wakefulness-related influences partially overrode the abnormal autonomic CO_2 reflexes, thus reducing the arterial P_{CO_2} to 48-55 Torr. The alveolar hypoventilation that is the fundamental pathophysiological process in this patient was also accompanied by hypoxemia in room air.

With regard to the function of the 10th and 12th cranial medullary motor nuclei, it was interesting to note that the patient's larynx dilated and constricted normally, indicating that, at least grossly, the motoneurons innervating the recurrent laryngeal nerves were spared. By contrast, his protruded tongue deviated to the right, indicating significant invasive fibrosis in his hypoglossal nucleus on the right. These discrepant findings attest to the variable degree of gliosis and fibrosis within the medullary tissue in this patient.

Additional examples of brainstem tissue lesions affecting chemosensitivity and breathing patterns

In their seminal 1981 review of neurological diseases manifesting as respiratory control abnormalities, Plum and Leigh⁸ summarized a variety of patients' case histories, including

their pathophysiological respiratory symptoms and signs, and described specific respiratory tests that helped define the sites of the specific lesions. Armed with less sophisticated *in vivo* imaging tools than we have today, many case histories included specific respiratory tests that functionally defined the locus of the pathology, and that location was ultimately put to the test by autopsy. The frequency with which such diagnoses were correctly made attests to the advantage of using respiratory studies for the definition of pathological processes, and retains the merit of this review for neurologists to this day.

In this section, however, we shall focus on more recent literature, in which the localization of pathological processes was made *in vivo* using current imaging technologies. The first of such examples is interesting, because it shows that even small unilateral lesions caused by circumscribed infarcts in the rostralateral medulla and identified by magnetic resonance imaging (MRI) can cause respiratory control abnormalities presenting as hypoxemia during sleep.^{9,10} Whether the hypoxemia was due to central hypoventilation or to upper airway obstruction could not be conclusively determined. Such upper airway obstruction might have been secondary to an incoordination between the upper airway and main respiratory muscles, or to a loss of function in the upper airways muscles. During restful wakefulness, minute ventilation and end-tidal P_{CO_2} (reflecting arterial P_{CO_2}) in those patients remained normal. By contrast, a CO_2 challenge elicited reduced respiratory responses when compared to the response of patients whose infarcts were elsewhere in the brainstem. This diminished responsiveness could be due to either the loss of CO_2 chemoreceptors, damage to a region that processes chemosensory input, or damage to a portion of the efferent pathway normally recruited only with hypercarbic stimulation. It is noteworthy, however, that these patients displayed a perfectly normal respiratory response to exercise. The dichotomous respiratory behavior in response to CO_2 versus exercise demonstrated that, at the level of those brainstem lesions, the efferent corticospinal pathways for exercise hyperpnea were in a different location from the bulbospinal pathways responsible for autonomic CO_2 responsiveness.

The reduced CO_2 responses with small unilateral lesions are important, in that they dispel the notion that a redundancy in CO_2 chemoreceptive sites² and a diffuse dispersion of bulbospinal pathways¹¹ guarantee a complete compensation for circumscribed damage. Furthermore, the studies of Morrell et al^{9,10} indicate that respiratory control abnormalities are not always easily apparent. When they do exist, such perturbations are likely, however, to manifest during sleep and to be expressed at least by an abnormally elevated carbon dioxide level and/or by reduced oxygenation. Therefore, at a minimum, regular monitoring of oxygenation during sleep serves as a precaution against such likelihood. Moreover, the diagnosis of breathing control abnormalities must at times be sought out deliberately with the help of specific respiratory tests such as CO_2 challenge.

Respiratory control abnormalities, however subtle, have various clinical implications: (1) Cyanotic episodes, or sleep apnea/hypoventilation that are not explained by lung disease may reveal the existence of brainstem pathology; (2) Superimposed respiratory illness such as pneumonia can precipitate full-blown respiratory failure in vulnerable patients;

(3) Sleep-related hypoventilation can be associated with exquisite sensitivity to the depressant effects of narcotic or sedative agents, leading to unexpected respiratory failure and occasional demise,⁸ and (4) The recurrent hypoxemia that is inherent to sleep-related hypoventilation carries a risk of long-lasting effects on many organ systems, for example, on the cardiovascular system, including systemic and pulmonary hypertension and cor pulmonale, and on the central nervous system, including an alteration of neuronal function and decreased neuronal survival.^{12,13}

Some of these implications are exemplified in a report on children with brain tumors who were referred to a sleep clinic for an evaluation of symptoms such as daytime hypersomnolence, respiratory insufficiency, hypoxemia and/or apnea.¹⁴ Of the 14 patients included in this report, one patient serves as an example for respiratory control abnormalities signaling brain malignancy: This patient had been initially referred for an evaluation of snoring and observed apnea, was found to have apnea and hypoventilation during sleep, but a CT scan of the brain at that time appeared normal. Two years later, when she returned with respiratory insufficiency and congestive heart failure, MRI study revealed a cervical-medullary astrocytoma that had probably also caused her initial respiratory symptoms. Another child who had a teratoid-rhabdoid tumor in the posterior fossa exemplifies the occurrence of overt respiratory abnormalities with acute lung pathology, in that this child developed both daytime and nighttime hypoxemia during a subsequent bout of pneumonia. A third child serves as an example for the increased sensitivity to sedation consequent to medullary pathology: Four years after resection and radio/chemotherapy for a medulloblastoma in the posterior fossa involving the brainstem, sedation for a colonoscopy that is usually uneventful precipitated an acute respiratory failure in that patient.

Medullary metastases can also result in a variety of respiratory effects depending on their location and/or extent of invasiveness. For example,¹⁵ a 52-year-old woman, who had been irradiated palliatively for large intracerebral adenocarcinomatous metastases (probably of pulmonary origin) displayed increasing hypersomnolence and was found dead one morning. Detailed autopsy revealed a hitherto undiscovered solitary metastasis in the brainstem. That small tumor completely replaced the right solitary tract nucleus and produced edema spreading to the contiguous reticular formation. Whereas the larger brain metastases in this patient may have also invaded supramedullary respiratory regions or pathways, the authors ascribed the sudden death to the disruption of activity in the solitary tract nucleus, because of its crucial role in the integration of afferent and efferent respiratory information, and because of its extensive connectivity both with its counterpart and with other respiratory medullary structures. The hypersomnia in this patient has been attributed to the involvement of the reticular formation, and the time of death has been ascribed to the vulnerability of respiratory control mechanisms at the transition between sleep and wakefulness. Of interest, a much more extensive metastasis in the medulla in another patient¹⁶ produced completely different functional disturbances: This 67-year-old man suffered from hypercarbia and hypoxemia that were not attributable to an abnormality in respiratory rhythm, but rather to a perturbation in the motor execution of breathing activity.

Indeed, when challenged with CO₂ or hypoxia, this patient's breathing frequency increased appropriately, but the tidal volume of each breath remained reduced. As well, when asked to take large breaths, his voluntary breathing efforts were also reduced. In this case, the authors concluded that the respiratory rhythm generator, the location of which is unknown in man, was somehow spared, thus permitting respiratory oscillation and increased respiratory rate, but that the major efferent respiratory outflow to the respiratory muscles was the culprit, thus preventing an increase in breath amplitude.

Compression-related causes of brainstem respiratory control abnormalities

Cervicomedullary compression in patients with achondroplasia can also cause severe respiratory symptoms, such as apnea and cyanotic episodes.¹⁷ The pathophysiology underlying those respiratory abnormalities can be divided into two categories: The first is directly related to skeletal abnormalities of upper airway structures, expected to produce upper airway obstruction, or of the chest, likely to produce restrictive lung pathology. The second pathophysiological category is a compression or indentation of the cervicomedullary brain tissue by osseous and fibrous elements. Such compression is sometimes combined with an obstruction of cerebrospinal fluid flow and with an elevated intracranial pressure.

When apnea and cyanosis were clinically observed in patients with achondroplasia, a polysomnographic sleep study revealed the full extent of the respiratory control abnormalities that included apnea and hypoventilation during sleep.¹⁷ Even in the absence of overt respiratory symptoms, however, sleep studies done in these patients for other reasons often revealed the existence of respiratory control abnormalities during sleep. Indeed, such respiratory abnormalities in achondroplasia are functionally more damaging than the skeletal motor disturbances associated with this syndrome, as these breathing perturbations may lead to acute respiratory failure and sudden death when they go undiagnosed. By contrast, however, when such perturbations are diagnosed in a timely fashion, and when they can clearly be attributed to the presence of a cervicomedullary compression, a surgical release of the compression can result in a complete relief of the respiratory symptoms. A concomitant upper airway obstruction, however, must be corrected separately.¹⁷

Children with severe myelomeningocele can display similar sleep-disordered breathing manifestations to those in achondroplasia, although the underlying pathophysiology in myelomeningocele is much more complex. In a cross-section study of a clinic population of children with myelomeningocele, those children who had a motor or sensory myelomeningocele level above L3, combined with a severe, Grade 3 Chiari II malformation (comprising brainstem abnormalities including a cervicomedullary kink and compression) were most inclined to exhibit respiratory perturbations during sleep.¹⁸ Those disturbances included hypoventilation, primarily in REM sleep, increased apnea and hypopnea, and central as well as obstructive apnea. The obstructive apnea appeared to be largely due to an incoordination of upper airway muscles, also of central origin, rather than to the more common childhood-related causes such as enlarged adenoids and/or tonsils. Inasmuch as the central respiratory abnormalities caused by this congenital malformation

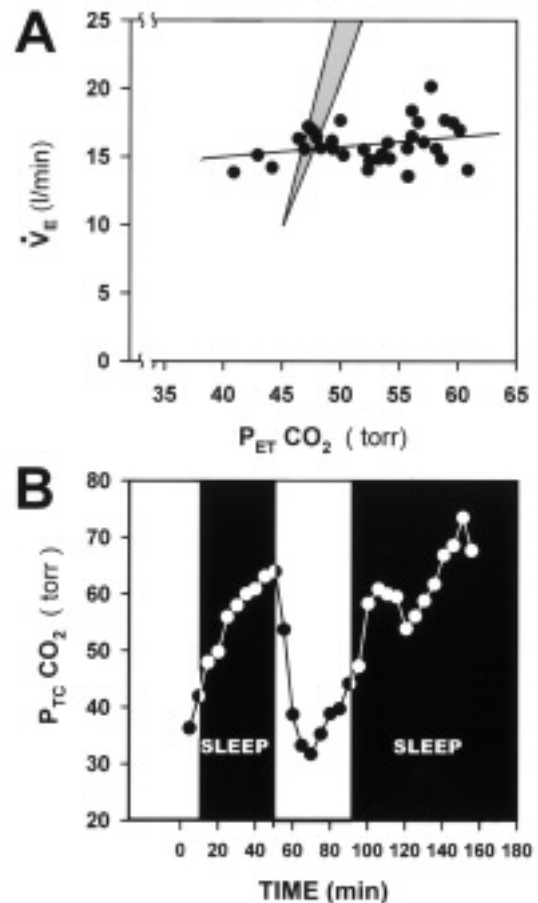


Figure 3A, 3B: Respiratory measures in a mother and daughter suffering from congenital alveolar hypoventilation syndrome. A. Blunted ventilatory responsiveness to hyperoxic CO₂ rebreathing in a 25-year-old woman who had been diagnosed with congenital central hypoventilation syndrome at the age of 14 months. A normal range of ventilatory responsiveness is shown for comparison by the grey fan. B. Increased transcutaneous P_{CO₂} during sleep, as compared to normal transcutaneous P_{CO₂} during wakefulness in a 13-day-old girl who has inherited the congenital central hypoventilation syndrome from her mother; the patient illustrated in A (modified from²²).

Abbreviations: \dot{V}_E , Minute Ventilation; $P_{ET}CO_2$, end-tidal partial pressure of carbon dioxide representing arterial partial pressure of carbon dioxide; $P_{TC}CO_2$, transcutaneous partial pressure of carbon dioxide.

last a lifetime, and because these abnormalities can be exacerbated by reduced lung function due to skeletal deformities such as scoliosis, the respiratory dysfunction in these patients must be diagnosed, treated and followed closely by medical teams that include neurologists.

Congenital central hypoventilation syndrome

Brainstem-related respiratory control abnormalities can also exist in the absence of any obvious structural pathology. In this regard, it is important to be cognizant of the existence of the relatively rare, but life-long affliction of congenital central hypoventilation syndrome.^{19,20} The predominant patho-

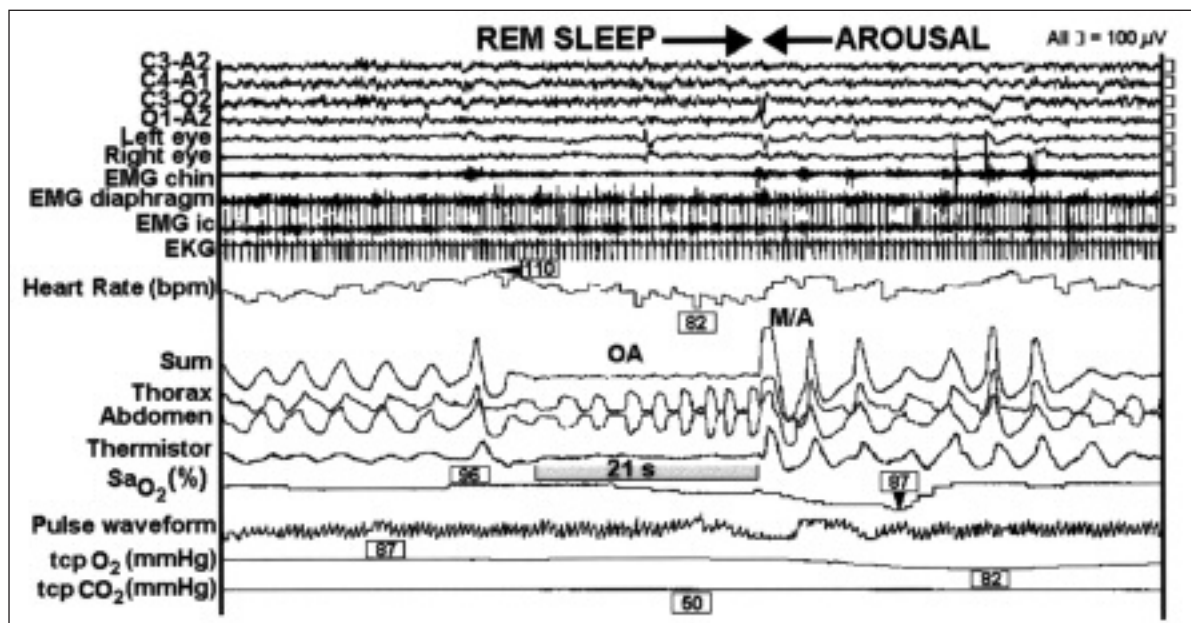


Figure 4: A polysomnogram showing an episode of obstructive sleep apnea in a child during REM sleep. A 21 second obstructive sleep apnea episode (OA), expressed by paradoxical thoracic versus abdominal breathing movements, nil sum of breathing movements and no air flow (thermistor), occurs during REM sleep (high frequency, low amplitude electroencephalographic activity, horizontal eye movements, very low chin electromyographic activity, left of first arrow). This episode is accompanied by a decrease of oxygen saturation (delayed) and heart rate, and followed by abrupt movement/arousal (M/A, high frequency, low amplitude electroencephalographic activity, increased chin electromyographic activity, movement artifacts, starting at second arrow), resumption of breathing and normalization of heart rate and oxygen saturation. Transcutaneous (tcp) O_2 and CO_2 are also shown (Courtesy Dr. Robert T Brouillette, Sleep Laboratory, Montreal Children's Hospital, McGill University Health Centre).

physiology of this syndrome is an inability to maintain chemical respiratory homeostasis, primarily during sleep in less severe cases, and during both sleep and wakefulness in more severe cases. Whereas the precise location or mechanism underlying this syndrome is yet unknown, the rhythmic but shallow breaths registered in these patients during sleep indicate an existence of a respiratory oscillator, but an abnormality in either the perception, integration, or motor neuron response to CO_2 and O_2 chemostimulation. The general location of this abnormality is thought to reside in the brainstem. This premise is strengthened by mounting evidence for other autonomic dysfunctions associated with this syndrome the location of which is also in the brainstem.²⁰ The embryological origin of these abnormalities is thought to stem from the neural crest, and several genes have been associated with this syndrome, although none exclusively.²¹ That there can be a genetic transmission of this syndrome is clearly evident from a study of a young woman who was afflicted with congenital central hypoventilation, as proven by a lack of responsiveness to CO_2 rebreathing (Figure 3A). She gave birth to an infant who, soon after birth, displayed wide swings in transcutaneous P_{CO_2} levels depending on behavioral state: P_{CO_2} was very high during sleep, and decreased to normal levels upon wakefulness (Figure 3B), as is typical of this syndrome.²² Despite its rareness (1 per 50,000 live births), one should be aware of this clinical entity so as to provide the life-long support that these patients require, including mechanical ventilation or phrenic nerve pacing.

In summary, the brainstem is crucial to the automated control of breathing and to chemical homeostasis. Experiments of nature, that is, tumors, fibrosis, infarcts, compression, distortion and structural abnormalities, as well as congenital conditions of as yet unclear etiology, can alter this homeostasis. Such disturbances are most clearly apparent during sleep, as this is the state in which the organism relies on automated respiratory control for the maintenance of chemical homeostasis.

Sleep, breathing, and brain hypoxia

The automated control of breathing by the brainstem is modulated by a great number of influences. One of the most important is the behavioral state. The importance of sleep-wake states in the control of breathing is already evident from the previous clinical examples which demonstrate that hypoventilation of any etiology manifests primarily during sleep, that wakefulness is a powerful stimulus to breathing that can overcome inherent brainstem pathology and normalize ventilation, and that the transition between sleep and wakefulness creates a vulnerability in the maintenance of breathing in compromised patients.

Sleep-wake states, the mechanisms of which are of ongoing interest and active research,^{23,24} modify breathing under normal conditions as well. Breathing control is truly automated during quiet, or non-rapid-eye-movement (non REM) sleep, a state associated with an inhibition of brain regions that produce arousal. During wakefulness, the afferent reticular activating

system excites the cortex via dorsal and ventral pathways. This general excitation also influences supramedullary respiratory control regions that can, in turn, overrule the automated breathing. Rapid eye movement (REM) sleep is a peculiar state in that it is associated with extensive cortical arousal via hypothalamic and other limbic structures. At the same time, however, this sleep state is accompanied by a depression of neuronal activity in many efferent motor pathways. This depression results from the activation of the subcoerulear nucleus, and produces the extensive motor paralysis that characterizes this behavioral state. Rapid eye movement disrupts autonomic respiratory control, resulting in a variable respiratory pattern that is not regulated by respiratory chemosensory stimuli.²³

In addition to aggravating the hypoventilation associated with brainstem pathology discussed above, sleep states are linked to several specific respiratory-related syndromes. The most common of those is obstructive sleep apnea syndrome. Whereas in the adult population, obstructive sleep apnea can be found in both non REM and REM sleep, in the pediatric population, such apnea is closely linked to REM sleep. This link can be seen in the section of a polysomnographic study from a child referred to the sleep laboratory for an evaluation of severe snoring (Figure 4). In this section, REM sleep can be identified by a constellation of low voltage, high frequency electroencephalogram, presence of horizontal eye movements, and very low electromyographic chin activity (as contrasted with the high voltage, low frequency electroencephalogram, absence of eye movements, and moderate electromyographic chin activity associated with non REM sleep). At the same time, paradoxical breathing movements are present, but there is no air flow. Hence, oxygen saturation decreases and bradycardia follows suit. This is a typical episode of obstructive sleep apnea during REM sleep. This episode is followed by abrupt arousal and wakefulness, recognized from the constellation of low voltage high frequency electroencephalogram, increased electromyographic chin activity, and body movement, and by a resumption of vigorous consensual thoracic and abdominal breathing movements, air flow and normalized oxygenation and heart rate. It is evident that the arousal and wakefulness provide a powerful stimulus to breathing, thus interrupting the apneic episode. Such cycling can occur hundreds of times per night. In severely afflicted patients, this recurring breathing pattern can be diagnosed from overnight oximetry studies that show clusters of oxygen desaturation episodes, thus obviating the need for full polysomnography.^{25,26} Obstructive sleep apnea results in recurrent intermittent hypoxia, an increased threshold for arousal, sleep fragmentation and deprivation, increased daytime somnolence and confusion, decreased concentration and learning, and increased cardiovascular complications including hypertension and cardiac failure in both children and adults.^{27,28}

The pathophysiology of upper airway obstruction ranges from the relatively common enlargement of adenoids and/or tonsils or from more complicated craniofacial abnormalities in children to other structural upper airway narrowing and disturbances in upper airway neuromotor tone in adults.²⁹ Whereas adenotonsillectomy in children, and even continuous positive airway pressure in adults, can reverse or improve much of the acute pathophysiology,^{30,31} there are indications that the

recurrent intermittent hypoxia associated with prolonged, severe obstructive sleep apnea may have long term functional consequences that outlast the removal of the obstruction. In children, such functional consequences are suspected, because post adenotonsillectomy improvements in school performance, for example, can be partial, modest, or non-existent, and because cardiovascular complications are sometimes only partially resolved.^{30,32} Neuroanatomical consequences are also suspected, as surmised from MRI studies in brains of adult patients after a long history of obstructive sleep apnea.^{12,13} These MRI studies have documented a decrease in the volume of grey matter in various brain regions. This volume loss has been interpreted as a possible indication of neuronal death consequent to the chronic intermittent hypoxia, hypercapnia and/or altered cerebral perfusion that accompany obstructive sleep apnea.^{12,13}

The other close correlation between sleep and respiratory-related syndromes relates to the Sudden Infant Death Syndrome. Although the precise pathophysiology of this syndrome is yet to be determined, a leading hypothesis ascribes it to developmental abnormalities in the autonomic control of breathing patterns, chemoreflexes, cardiac reflexes, thermoregulation and/or asphyxial arousal that manifest in early infancy and during sleep, and that may be related to abnormalities in genes involved in the development of the autonomic nervous system.³³ The subtle pathophysiological abnormalities are presumed to be augmented when the infants sleep in the prone position. In that position the infants may be rebreathing their own air, thus incurring progressive hypoxemia and hypercarbia. Whereas in normal infants, such circumstances would prompt arousal, a change in head position, increased ventilation, and correction of the respiratory chemical imbalance, these infants appear to have an elevated threshold of arousal and sluggish reflex responses. Such delay in arousal and responsiveness prevents these infants from benefitting from the powerful effect of wakefulness on breathing.^{19,33} A repetition of such episodes may produce recurrent hypoxemia which, in turn, may result in apoptosis in various brainstem and supramedullary regions³⁴ that may further increase the vulnerability of these infants and set the stage for their demise.

Supramedullary control of breathing: Volition

In addition to the general excitatory effect on respiration provided by arousal and wakefulness, volition is a powerful stimulus of breathing that can modulate and override autonomic respiratory reflexes. It has been important to demonstrate where the drive for volitional respiratory control emanates from for both scientific reasons and for a better understanding of clinical situations in which this drive to breathe is disrupted, as will be described later.

The localization of supramedullary regions generating the volitional control of breathing has been based on a study employing positron emission tomography (PET) imaging in human volunteers.³⁵ The principle behind the study is that a functionally-induced, increased synaptic and neuronal activity uses up oxygen and generates CO₂, and that the resultant local reduction in oxygen and elevation in CO₂ concentrations increase blood flow in the activated brain region. This regional blood flow increase can be imaged from H₂¹⁵O that is infused intravenously at the time that this process takes place, and that is

preferentially distributed to the region of high blood flow.

Using this approach, the volunteers were asked to perform volitional inspiratory or expiratory maneuvers. The PET images thus obtained were collected three-dimensionally and subtracted from those obtained during passive breathing using positive pressure ventilation. Volitional inspiration was found to involve the primary and supplemental motor cortical regions bilaterally and the premotor cortex and ventrolateral thalamus unilaterally, confirmed subsequently.³⁶ Of note, volitional expiration activated the same regions, although more extensively and with greater bilateral representation, and, in addition, activated the cerebellum. These findings document the participation of the cortex in volitional breathing, localize the motor regions involved, and emphasize the more extensive cortical representation during volitional expiration than during inspiration. Considering the fact that during normal breathing expiration is a passive process, the extensive participation of the cortex in volitional expiration emphasizes the essential role of active expiratory control in the execution of complex human activities such as speaking, singing, playing wind instruments, and expulsive maneuvers.

Exercise hyperpnea

During moderate exercise, the increased respiration is tightly matched to metabolic requirements and is termed exercise hyperpnea. The mechanisms involved in this hyperpnea include peripheral mechanisms through afferent signals from chemosensory organs, from the exercising skeletal muscle itself, and from the vascular dilation in the exercising muscle.³⁷ Central mechanisms have also been invoked, especially at the onset of exercise, during which there is a central command to initiate an increased breathing activity in anticipation of the exercise. Using experimental animals, that central command had been thought to emanate from hypothalamic regions.³⁸ More recent studies in humans have attempted to reveal whether the cortex might participate in the initiation of the central command for exercise hyperpnea.³⁹

To identify and define the role of the cortex in exercise hyperpnea, the study by Thornton et al³⁹ involved hypnotizing volunteer adult subjects and, under hypnosis, asking them to imagine various modalities of exercise. During these imaginary exercise maneuvers, the investigators recorded the volunteers' respiration and performed PET scanning so as to learn what portions of the brains were activated by each maneuver. The state of hypnosis was advantageous, because it isolated the subjects from environmental stimuli, diminished any perception of afferent stimulation, allowed a more directed and reproducible imagination of exercise without peripheral feedback, and ensured immobility, thus permitting more accurate scanning. Imagining riding a bicycle up a steep incline yielded a PET scan that included both the cognition of exercise and the imagined hard work of the exercise maneuver, whereas imagining riding a bicycle downhill rendered a scan that included the same cognition but without the imagined hard work. The volunteers were also asked to volitionally match the breathing patterns produced by the two exercise modalities, thus furnishing a PET scan of the volitional portion of those activities. Because increased ventilation without a concomitant increase in metabolism induces hypocarbia, CO₂ levels were monitored and

maintained by the addition of CO₂ to the inspired air so as to avoid any confounding effect of hypocarbia on the observations. When the three-dimensional PET scans were subtracted from one another, the supplementary motor areas, the right premotor area, and the dorsolateral prefrontal cortex were identified as the cortical regions that participated in the exercise hyperpnea that was unencumbered by feedback mechanisms. These cortical regions identified by imaging in man have been proposed to initiate the behavioral response to exercise, thus dispelling the notion that the central command for exercise hyperpnea emanates solely from the hypothalamus.

Air hunger

One of the most unpleasant respiratory sensations that occur either during strenuous exercise or with pulmonary disease is dyspnea, or shortness of breath. One of its components is breathlessness, or air hunger, defined as an uncomfortable urge to breathe. This sensation has many descriptors and its intensity can be ranked and quantified.⁴⁰ Air hunger can also be elicited in normal subjects by letting them inhale gases enriched with CO₂, by making them breathe through a face mask, or by limiting the size of mechanically provided breaths. Several studies have attempted to identify those brain regions that play a role in this sensation.

Brannan et al⁴¹ mapped such regions by PET scanning in healthy adults exposed to a high (8%) CO₂ mixture, and found that many limbic and paralimbic regions "lit up", consistent with the classical notion that these afferent and "old" brain areas are associated with strong emotions, including fear, panic, and anticipation of pain. Many other brain regions were activated as well, however, including cortical areas and the cerebellum. Whereas the PET scans obtained by these investigators are informative, they probably represent a combination of a general increase of cerebral blood flow due to the direct vascular effect of the high CO₂ with the regional increases in cerebral blood flow due to the neuronal activation by the CO₂ stimulus. The latter, however, likely encompasses both the supramedullary regions recruited in the overall respiratory response to hypercarbia² and those regions involved in the unpleasant sensations that accompany hypercarbia.

Several studies have attempted to distinguish among these components and isolate those brain regions activated by air hunger alone.^{40,42,43} In the first of this series,⁴² PET scans were obtained in healthy adult subjects that were artificially ventilated throughout the experiment, thus removing the contribution of volitional breathing from the equation. The experiment comprised changing the gaseous composition versus the volume of the mechanical breaths: When the Pco₂ was held at above normal levels, large tidal volumes did not elicit air hunger, but low tidal volumes did. When Pco₂ was held at below normal levels, neither large nor small tidal volumes elicited any sensation of air hunger. Thus it was a tidal volume that was inappropriately small for the prevailing chemical stimulus that generated the intense sensation of air hunger. Such a combination specifically activated the insular cortex, a region known to integrate visceral information with sensation, behavior and learning relevant to homeostasis.⁴⁴ In this case, the extent of neuronal insular activation depended on the balance between the afferent stimulus to breathe (CO₂) and the afferent visceral

information regarding the inflation status of the lung (mechanoreceptors) that, if adequate, would diminish the desire to breathe.

A subsequent study by the same group⁴⁰ refined the experimental approach, and also used a different imaging technique, blood oxygenation level dependent functional magnetic resonance imaging (BOLD fMRI), to map the activated brain regions. Briefly, this imaging method relies on the relatively lesser degree of hemoglobin deoxygenation in blood distributed to activated brain regions, due to increased regional blood flow and volume in those regions. The altered ratio between oxygenated and deoxygenated hemoglobin modifies the magnetic output, registered as a change in BOLD fMRI.⁴⁵ The advantages of this method versus PET scanning are (1) lack of ionizing radiation; (2) a greater signal to noise ratio, and (3) a greater spatial resolution. Using this method, and employing a similar experimental protocol in healthy adults to that used in the previous study,⁴² the investigators found that, in addition to the insula, many other cortical and subcortical regions were activated by the air hunger, including the anterior cingulate, operculum, cerebellum, amygdala, thalamus, basal ganglia and frontoparietal regions associated with attention. This finding indicates that the insula functions in concert with a larger neuronal network in integrating air hunger. More recently, the same group⁴³ dispelled the previously held notion that only hypercarbia, but not hypoxia, provokes air hunger, by showing that when ventilatory drive is made to be equal, the two chemical stimuli result in the same degree of air hunger. It is likely that the afferent projection of both chemical stimuli to the insular cortex emanates from the solitary tract nucleus, as this nucleus integrates these chemical stimuli and has direct projections to the insula.⁴⁴

Experiments of nature: Ondine's curse and the 'locked-in syndrome'

The preceding sections addressed the roles of the brainstem and of supramedullary regions in normal physiological

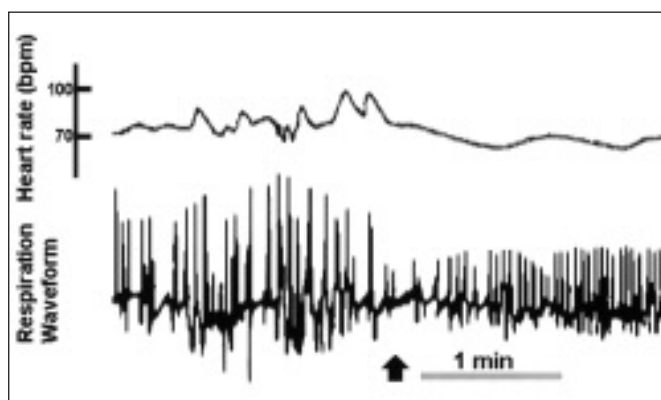


Figure 5: Respiration waveform and heart rate (bpm) while listening to dissonant atonal electronic music by Stockhausen (left of the arrow) versus melodic music by Chopin, indicating the effect of emotion on respiratory and circulatory behavior (Redrawn and modified from⁴⁹).

mechanisms controlling breathing. Ondine's curse and the 'locked-in syndrome' are medical conditions that illustrate what happens when some of these mechanisms are severely disrupted.

Ondine's curse is an extreme manifestation of sleep apnea, in which respiratory activity is entirely dependent on conscious volitional breathing, and ceases when the patient's attention is diverted, upon the onset of sleep, or when anesthesia is administered. This syndrome is named after the German mythical sea nymph, Ondine, who thrust a curse on her unfaithful mortal knight, Hans, that he would lose all autonomic functions, and would have to remember to breathe voluntarily to survive. He died when he finally fell asleep. As reviewed recently by Bolton et al⁴⁶, this rare condition can be caused by an extensive destruction of the medullary ventrolateral respiratory regions and their reticulospinal efferent and afferent connections due to pathologies ranging from vascular events, large and extensive space occupying lesions, poliomyelitis, tract resection for intractable pain, or degenerative diseases. These patients require artificial ventilation or phrenic pacing to survive.

By contrast, in an illustrative case study of the 'locked-in syndrome',⁴⁷ a 44-year-old man who suffered a bilateral infarction of the ventral pons displayed spontaneous breathing that was very regular, and that adequately maintained a normal P_{CO_2} . However, the patient could not exert any volitional breathing maneuver. By contrast, emotional outbursts provoked significant irregularities of his breathing rhythm. This patient is a testament to the fact that volitional breathing operates via corticobulbar pathways which were nonfunctional in his case. Further, these corticobulbar pathways are distinct from limbic respiratory pathways that conduct supramedullary respiratory responses to emotion, and that did remain functional. Under normal conditions, the two pathways eventually merge, but in his case, only the limbic pathways were intact. It is also noteworthy that this patient survived due to his pontomedullary respiratory oscillator which operated in isolation from the corticospinal pathways. It is because of this autonomic oscillator that this patient's ventilatory response to inhaled CO_2 was normal, and that he could sense breathlessness during the hypercarbic stimulus. Another instructive lesson was derived from the observation that when the patient's P_{CO_2} level was artificially reduced by mechanical hyperventilation while he was awake, he became apneic. In healthy subjects, such apnea never happens during wakefulness, and can only occur when the subject is in non REM sleep, as the wakeful stimulus that provides cortical excitation overrides such apnea and sustains breathing via the corticospinal pathways. The disrupted corticospinal pathways in this patient obviated such cortical protection against hypocarbia. The lessons that can be learned from this syndrome is that, whereas the pontomedullary oscillator is essential for basal respiratory homeostasis, the brain as a whole is required for normal breathing, and that the wakefulness stimulus and intact corticospinal pathways are crucial for maintaining stable, versatile and appropriately adaptive breathing patterns.

Breathing and Emotion

A vast lore exists in the medical literature about the effects of emotion on breathing.⁴⁸ The best known example is the emotive hyperventilation syndrome that can result in extreme hypocarbia, respiratory alkalosis, and muscle spasms due to an

acute reduction in ionized calcium. The relationship between emotion and breathing is an every day experience, however, as evidenced from Figure 5.⁴⁹ This figure depicts respiratory and pulse signals of a person listening to two successive styles of music, dissonant atonal electronic music by Stockhausen versus melodic soothing music by Chopin. The difference in respiratory and pulse patterns between the two is striking: It is highly excited and irregular in the first, and very stable and regular in the second, showing the different emotionally-driven respiratory and cardiac reactions to the two types of music. The pathways governing the emotion to respiration operate via limbic structures and are anatomically distinct from the corticospinal pathways, as noted in the 'locked in syndrome' case study discussed above.

SUMMARY AND CONCLUSIONS

Breathing is not only an automated function, but is a complex behavior that involves many brain regions. These include cortical and subcortical regions that are not usually considered with regard to respiratory control. These regions are activated by respiratory-related sensations and initiate complex respiratory activities. Clever experimental designs and specialized respiratory functional tests are required for demonstrating respiratory manifestations of brain pathology. Since respiratory abnormalities often become apparent during sleep, monitoring of breathing during sleep should be an inherent practice for any neurologically related pathology. Such monitoring will not only help in identifying abnormal patterns and chemical imbalances when the pathology is known, but will sometimes reveal an unknown pathology, and will also prevent respiratory crises from occurring during sleep or at the transition between sleep and wakeful states.

ACKNOWLEDGMENTS

This article was supported by the Canadian Institutes of Health Research and by the Montreal Children's Hospital Research Institute. The author thanks Dr. Rolando Del Maestro, Department of Neurosurgery, Montreal Neurological Institute, McGill University, for permitting the discussion of Mr. MDC's case history and the presentation of a CT scan, and Dr. Robert T. Brouillette, Department of Pediatrics, McGill University, for providing a polysomnographic recording. As well, the author is grateful to Mr. André Laferrière and Dr. B. Michael Davis, Department of Pediatrics, McGill University, for reviewing the manuscript and for making helpful suggestions. Mr. André Laferrière's contribution in producing the figures is greatly appreciated.

REFERENCES

1. Feldman JL, Smith JC. Neural control of respiratory pattern in mammals: an overview. In: Dempsey JA, Pack AI, (Eds). *Regulation of Breathing, Lung Biology in Health and Disease*, Vol 79. New York: Marcel Dekker, 1995: 39-69.
2. Feldman JL, Mitchell GS, Nattie EE. Breathing: rhythmicity, plasticity, chemosensitivity. *Annu Rev Neurosci* 2003; 26: 239-266.
3. Allen AM, Chai SY, Sexton SY, et al. Angiotensin II receptors and angiotensin converting enzyme in the medulla oblongata. *Hypertension* 1987; 9 (Suppl II): 198-205.

4. Allen AM, Chai SY, Clevers J, et al. Localization and characterization of angiotensin II receptor binding and angiotensin converting enzyme in the human medulla oblongata. *J Comp Neurol* 1988; 269: 249-264.
5. Feldman JL, McCrimmon DR. Neural control of breathing. In: Squire LR, Bloom FE, McConnell SK, Roberts JL, Spitzer NC, Zigmond MJ, (Eds). *Fundamental Neuroscience*. Amsterdam: Academic Press, 2003: 967-990.
6. Gottesmann C. Brain inhibitory mechanisms involved in basic and higher integrated sleep processes. *Brain Res. Brain Res Rev* 2004; 45: 230-249.
7. Davenport PW, Reep RL. Cerebral cortex and respiration. In: Dempsey JA, Pack AI, *Regulation of Respiration. Lung Biology in Health and Disease*, Vol 79. New York: Marcel Dekker, 1995: 365-388.
8. Plum F, Leigh RJ. Abnormalities of central mechanisms. In: Hornbein TF, (Ed). *Regulation of Breathing*. New York: Marcel Dekker, 1981: 989-1067.
9. Morrell MJ, Heywood P, Moosavi SH, et al. Unilateral focal lesions in the rostralateral medulla influence chemosensitivity and breathing measured during wakefulness, sleep, and exercise. *J Neurol Neurosurg Psychiatr* 1999; 67: 637-645.
10. Morrell MJ, Heywood P, Moosavi SH, et al. Central chemosensitivity and breathing asleep in unilateral medullary lesions patients: comparisons to animal data. *Respir Physiol* 2001; 129: 269-277.
11. Straus C, Locher C, Zelter M, et al. Facilitation of the diaphragm response to transcranial magnetic stimulation by increases in human respiratory drive. *J Appl Physiol* 2004; 97: 902-912.
12. Macey PM, Henderson LA, Macey KE, et al. Brain morphology associated with obstructive sleep apnea. *Am J Respir Crit Care Med* 2002; 166: 1382-1387.
13. Morrell MJ, McRobbie DW, Quest RA, et al. Changes in brain morphology associated with obstructive sleep apnea. *Sleep Med* 2003; 4: 451-454.
14. Rosen GM, Bendel AE, Neglia JP, et al. Sleep in children with neoplasms of the central nervous system: case review of 14 children. *Pediatrics* 2003; 112: e46-e54.
15. Rhodes RH, Wightman HR. Nucleus of the tractus solitarius metastasis: relationship to respiratory arrest? *Can J Neurol Sci* 2000; 27: 328-332.
16. Corne S, Webster K, McGinn G, et al. Medullary metastasis causing impairment of respiratory pressure output with intact respiratory rhythm. *Am J Respir Crit Care Med* 1999; 159: 315-320.
17. Aryanpur J, Hurko O, Francomano C, et al. Craniocervical decompression for cervicomedullary compression in pediatric patients with achondroplasia. *J Neurosurg* 1990; 73: 375-382.
18. Waters KA, Forbes P, Morielli A, et al. Sleep-disordered breathing in children with myelomeningocele. *J Pediatr* 1998; 132: 672-681.
19. Gozal D. New concepts in abnormalities of respiratory control in children. *Curr Opin Pediatr* 2004; 16: 305-308.
20. Vanderlaan M, Holbrook CR, Wang M, et al. Epidemiologic survey of 196 patients with congenital central hypoventilation syndrome. *Pediatr Pulmonol* 2004; 37: 217-229.
21. Weese-Mayer DE, Berry-Kravis EM, Zhu L, et al. Idiopathic congenital central hypoventilation syndrome: analysis of genes pertinent to early autonomic nervous system embryologic development and identification of mutations in PHOX2b. *Am J Med Gen* 2003; 123A: 267-278.
22. Sritippayawan S, Hamutcu R, Kun SS, et al. Mother-daughter transmission of congenital central hypoventilation syndrome. *Am J Respir Crit Care Med* 2002; 166: 367-369.
23. Siegel J. Brain mechanisms that control sleep and waking. *Naturwissenschaften* 2004; 91: 355-365.
24. Villablanca JR. Counterpointing the functional role of the forebrain and of the brainstem in the control of the sleep-waking system. *J Sleep Res* 2004; 13: 179-208.
25. Collop NA, Shepard JW, Strollo PJ. Executive summary on the systematic review and practice parameters for portable monitoring in the investigation of suspected sleep apnea in adults. *Am J Respir Crit Care Med* 2004; 169: 1160-1163.

26. Nixon GM, Kermack AS, Davis GM, et al. Planning adenotonsillectomy in children with obstructive sleep apnea: the role of overnight oximetry. *Pediatrics* 2004; 113: e19-e25.
27. O'Brien LM, Mervis CB, Holbrook CR, et al. Neurobehavioral correlates of sleep-disordered breathing in children. *J Sleep Res* 2004; 13: 165-172.
28. Parish JM, Somers VK. Obstructive sleep apnea and cardiovascular disease. *Mayo Clinic Proc* 2004; 79: 1036-1046.
29. Arens R, Marcus CL. Pathophysiology of upper airway obstruction: a developmental perspective. *Sleep* 2004; 27: 997-1019.
30. Lipton AJ, Gozal D. Treatment of obstructive sleep apnea in children: do we really know how? *Sleep Med Rev* 2003; 7: 61-80.
31. Hamilton GS, Solin P, Naughton MT. Obstructive sleep apnoea and cardiovascular disease. *Intern Med J* 2004; 34: 420-426.
32. Schechter MS. Technical report: diagnosis and management of childhood obstructive sleep apnea syndrome. *Pediatrics* 2002; 109: e69(1-20).
33. Hunt CE. Genes and sudden Infant death syndrome. *Pediatr Res* 2004; 56: 321-322.
34. Sparks DL, Hunsaker JC III. Neuropathology of sudden infant death (syndrome): literature review and evidence of a probable apoptotic degenerative disease. *Childs Nerv Syst* 2002; 18: 568-592.
35. Ramsay SC, Adams L, Murphy K, et al. Regional cerebral blood flow during volitional expiration in man: a comparison with volitional inspiration. *J Physiol* 1993; 461: 85-101.
36. Evans KC, Shea SA, Saykin AJ. Functional MRI localisation of central nervous system regions associated with volitional inspiration in humans. *J Physiol* 1999; 520: 383-392.
37. Haouzi P, Chenuel B, Huszczuk A. Sensing vascular distension in skeletal muscle by slow conducting afferent fibers: neurophysiological basis and implication for respiratory control. *J Appl Physiol* 2004; 96: 407-418.
38. Eldridge FL, Millhorn DE, Kiley JP, et al. Stimulation by central command of locomotion, respiration and circulation during exercise. *Respir Physiol* 1985; 59: 313-337.
39. Thornton JM, Guz A, Murphy K, et al. Identification of higher brain centres that may encode the cardiorespiratory response to exercise in humans. *J Physiol* 2001; 533: 3-36.
40. Evans KC, Banzett RB, Adams L, et al. BOLD fMRI identifies limbic, paralimbic, and cerebellar activation during air hunger. *J Neurophysiol* 2002; 88: 1500-1511.
41. Brannan S, Liotti M, Egan G, et al. Neuroimaging of cerebral activations and deactivations associated with hypercapnia and hunger for air. *Proc Natl Acad Sci USA* 2001; 98: 2029-2034.
42. Banzett RB, Mulnier HE, Murphy K, et al. Breathlessness in humans activates insular cortex. *NeuroReport* 2000; 11: 2117-2120.
43. Moosavi SH, Golestanian E, Binks AP, et al. Hypoxic and hypercapnic drives to breathe generate equivalent levels of air hunger in humans. *J Appl Physiol* 2003; 94: 141-154.
44. King AB, Menon RS, Hachinski V, et al. Human forebrain activation by visceral stimuli. *J Comp Neurol* 1999; 413: 572-582.
45. D'Esposito M, Deouell LY, Gazzaley A. Alterations in the BOLD fMRI signal with ageing and disease: a challenge for neuroimaging. *Nat Rev Neurosci* 2003; 4: 863-872.
46. Bolton CF, Chen R, Wijdicks EFM, Zifko UA. *Neurology of Breathing*. Philadelphia: Butterworth Heinemann, 2004: 1-304
47. Heywood P, Murphy K, Corfield DR, et al. Control of breathing in man; insights from the 'locked-in' syndrome. *Respir Physiol* 1996; 106: 13-20.
48. Boiten FA, Frijda NH, Wientjes CJE. Emotions and respiratory patterns - review and critical analysis. *Intl J Psychophysiol* 1994; 17: 103-128.
49. Harrer G. Somatische Aspekte des Musikerlebens. *Med Monatsspiegel* 1970; 6: 124-127.